



**PATIENT PRESENTING CLINICAL SIGNS**

Jojo Beckerf History chronic hematuria. Hx cystotomy to remove stones, Sept. 2022. Proteinuria. Exam limited to urinary system.

**SPECIES LIMITED ULTRASONOGRAPHIC EXAMINATION OF THE URINARY SYSTEM**

Feline **Urinary System**

**BREED** The urinary bladder was normal in size and tone with normal walls and no evidence of inflammatory or neoplastic criteria. The trigone, cystourethral junction, and visible pelvic urethra to a depth of 2 cm exhibited normal thickness and tone. Anechoic urine was present in the lumen with no uroliths or sediment. A focal area of minor non-obstructive urethral luminal mineral was present.

**SEX** Normal size and margination were present in the kidneys. A normal 1:3 cortex / medulla ratio was maintained. The medulla and cortices were uniform in texture with some increased echogenicity and mild loss of corticomedullary symmetry and definition expected for the age of the patient. Very minor left kidney pyelectasia was present. Non-obstructive medullary and pelvic mineral was present bilaterally. The left kidney measured 3.2 cm in length. The right kidney measured 4.2 cm in length.

**AGE ULTRASONOGRAPHIC FINDINGS**

5yr

- Overall sonographically urinary bladder
- Focal minor non-obstructive proximal urethral luminal mineral
- Bilateral chronic renal changes with non-obstructive medullary/pelvic mineral and minor left kidney pyelectasia

**WEIGHT**

9.4lb

**INTERPRETATION OF THE FINDINGS & FURTHER RECOMMENDATIONS**

**INTERPRETED BY**

R. McKenzie Daniel, DVM,  
 DABVP (Canine and Feline)

This patient is likely passing small amounts of mineral from the kidneys into the urinary bladder. Without evidence of lower urinary tract macrocalculi or inflammatory mural criteria the hematuria is suspected to be originating from the kidneys. A urine C/S on a sterile urine sample and baseline UPC is recommended.

**IMAGING PERFORMED BY**

Pamela Harrigan, RDCS

**HOSPITAL NAME**

Kitty Corner Cat Clinic

**REFERRING VET**

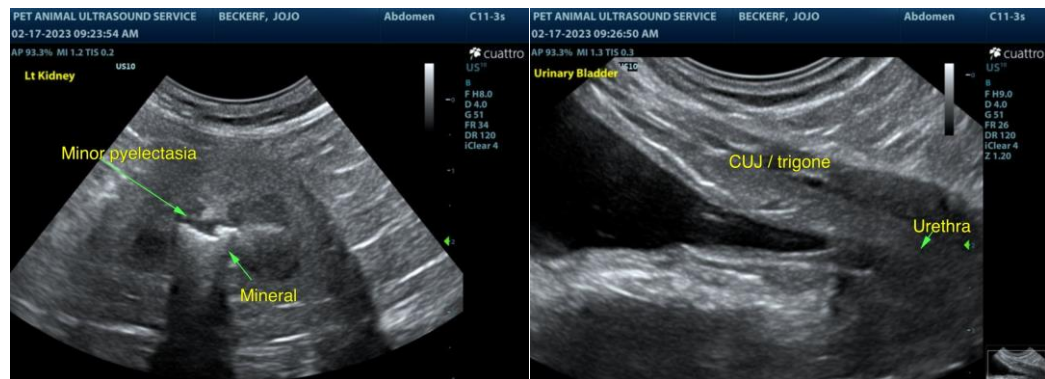
Dr. Harris

**INVOICE**

12988ag

**DATE**

02/17/2023





**PATIENT**

Jojo Beckerf

**SPECIES**

Feline

**BREED**

DSH

**SEX**

FS

**AGE**

5yr

**WEIGHT**

9.4lb

**INTERPRETED BY**

R. McKenzie Daniel, DVM,  
 DABVP (Canine and Feline)

**IMAGING PERFORMED BY**

Pamela Harrigan, RDCS

**HOSPITAL NAME**

Kitty Corner Cat Clinic

**REFERRING VET**

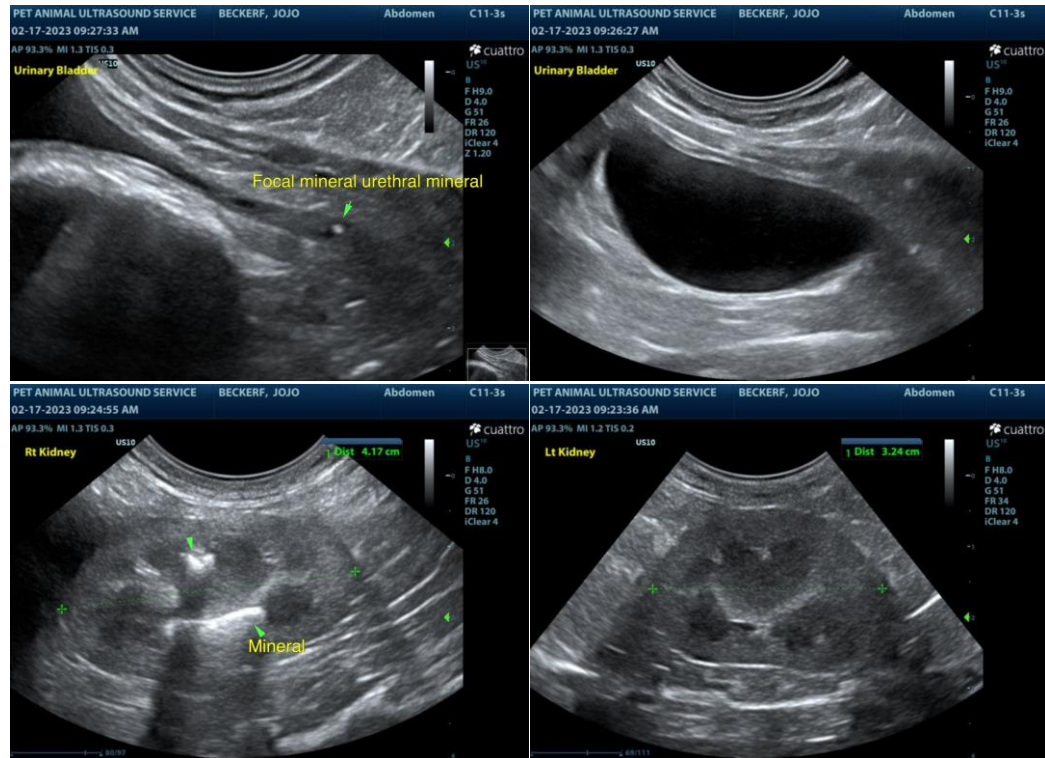
Dr. Harris

**INVOICE**

12988ag

**DATE**

02/17/2023



The information and recommendations provided are based on the images presented by the referring veterinarian/sonographer. No evaluation can be communicated regarding pathology that was not visible in the image/video clips provided.

Thank you for this referral. If the clinical or image interpretation does not parallel your findings or if I can be of any further assistance please contact me.

R. McKenzie Daniel, DVM, DABVP (Canine / Feline Practice)

info@SonoPath.com