



PATIENT

Violet Gardner

SPECIES

Canine

BREED

Labrador Retriever

SEX

Spayed Female

AGE

11 Years 2 Months

WEIGHT

63 pounds

INTERPRETED BY

R. McKenzie Daniel,
 DVM, DABVP (Canine
 / Feline Practice)

IMAGING PERFORMED BY

Rebecca Hamilton

HOSPITAL NAME

Marsh Animal Hospital

REFERRING VET

Dr. Armani

INVOICE

13837

DATE

02/16/26

PRESENTING CLINICAL SIGNS

- Elevated GGT
- Meds: Cytopoint inj.

Abnormal PE/Chem/CBC/UA Results: BPM 133/100, 148/115, 144/110, GGT 31, Monocytes, high 1248

ULTRASONOGRAPHIC EXAMINATION OF THE HEART & ABDOMEN

CANINE CARDIAC PARAMETERS	MR VMAX (m/s)	TR VMAX (m/s)	LA/AO (M-Mode)	LA/AO (Heart Base; Swe)	FS (%)	EF (%)	EPSS (cm)
NORMAL PARAMETER	4.5-5.5	<2.7	1.3	Up to 1.6	28-40	40-100	<0.6
PATIENT	--	--	1.1	1.0	51	83	0.25
CANINE CARDIAC PARAMETERS	HR (BPM)	AV VMAX (m/s)	PV MAX (m/s)	BODY WEIGHT (lbs)	LAD LA MAX 4 Chamber	LVIDd Avg; 2D and m-mode short axis (cm)	LVIDs Avg; 2D and m-mode short axis (cm)
NORMAL PARAMETER	50-100	0.7-1.7	0.7-1.6				
PATIENT	173	1.1	0.9	63.0	3.7	3.7	--

Cardiac Presentation

The echocardiogram in this patient demonstrated normal **left atrial** size based on 3 separate methods of LA evaluation. The cranial and caudal **mitral** valve leaflets presented normal linear structure, extension in systole, and union in diastole with normal kinesis. The **left ventricle** presented thicknesses with linear contour and was not dilated nor restricted. The **myocardium** presented normal echogenicity without subjective evidence of significant fibrotic or ischemic disease. **Contractility** of the ventricular walls was adequate and in normal range for this patient evidenced by the fractional shortening measurement and subjective evaluation of the different regions of the myocardium. The **left ventricular outflow** tract demonstrated normal laminar flow and subjective structural integrity. The **right atrium** and auricle revealed normal size, structure and content. No evidence of masses was noted. **Tricuspid** valvular assessment demonstrated adequate linear morphology and kinesis. The **right ventricle** was of normal size (1/3 diameter of LV), chordae structure, myocardial echogenicity and thickness. **Pulmonary outflow** tract assessment revealed normal valve structure, laminar flow, and diameter (approx.1:1 pa/ao ratio). No visible **pericardial** or free pleura fluid was noted. The cranial **mediastinum** and **pericardial and extra-cardiac regions** were free of masses in the visible window.

Urinary System



PATIENT

Violet Gardner

The urinary bladder, trigone, cystourethral junction, and visible pelvic urethra to a depth of 3.0 cm exhibited normal thickness and tone. Anechoic urine was present in the lumen with no uroliths or sediment. The ureteral papillae were normal. The ureters were not visible which is normal. No evidence of inflammatory or neoplastic change were noted.

SPECIES

Canine

The area of the aortic trifurcation was free of pathology.

BREED

Labrador Retriever

Normal size and margination was present in the kidneys. A normal 1:3 cortex / medulla ratio was maintained. The medulla and cortices were uniform in texture with some increased echogenicity and mild loss of corticomedullary symmetry and definition expected for the age of the patient. No evidence of pelvic dilation was present. The left kidney measured 5.7 cm in length. The right kidney measured 6.0 cm in length.

SEX

Spayed Female

Adrenal Glands

The left adrenal gland was uniform in size and contour with a uniformly hypoechoic parenchyma. The left adrenal gland measured 0.65 cm width at the caudal pole.

AGE

11 Years 2 Months

The right adrenal gland was uniform in size and contour with a uniformly hypoechoic parenchyma. The right adrenal gland measured 0.66 cm width at the caudal pole.

WEIGHT

63 pounds

Spleen

The spleen exhibited a finely textured and homogenous parenchyma which was hyperechoic to the liver and renal cortical parenchyma. The capsule was smooth and regular without apparent expansion. The splenic vasculature at the hilus was normal in volume with no evidence of congestion or thrombosis. Acute to chronic inflammatory, neoplastic, or benign parenchyma changes were not noted.

INTERPRETED BY

R. McKenzie Daniel,
DVM, DABVP (Canine
/ Feline Practice)

Liver & Gallbladder

The liver presented with subjective borderline mild generalized hepatomegaly. The parenchyma of the liver was subjectively normal in echogenicity compared to the spleen and renal cortices. The liver parenchyma was uniform with a mildly coarse echotexture. The capsule of the liver was symmetrically rounded to mildly swollen in margination. The hepatic and portal vasculature were normal in appearance without signs of congestion. Mild mid liver lobar swelling exhibiting maintained homogenous parenchyma with potential for emerging mid liver hepatoma-like mass measuring approximately 10.0 cm in diameter.

IMAGING PERFORMED BY

Rebecca Hamilton

The gallbladder was non-distended in size with thin walls and mild nonorganized bile debris. The cystic and common bile ducts were normal.

HOSPITAL NAME

Marsh Animal Hospital

REFERRING VET

Dr. Armani

Gastrointestinal

INVOICE

13837

The stomach presented intact wall layering with a normal wall layer ratio. The lumen of the stomach was empty with no signs of ileus, obstruction or foreign material.

DATE

02/16/26

The small intestine presented intact wall layering with 1:3 muscularis/mucosa ratio. The lumen of the small intestine was empty with no signs of ileus, obstruction or foreign material.

Normal visible colon wall layers were present with apparent formed feces in lumen.

Pancreas



PATIENT

Violet Gardner

SPECIES

Canine

BREED

Labrador Retriever

SEX

Spayed Female

AGE

11 Years 2 Months

WEIGHT

63 pounds

INTERPRETED BY

R. McKenzie Daniel,
DVM, DABVP (Canine
/ Feline Practice)

IMAGING PERFORMED BY

Rebecca Hamilton

HOSPITAL NAME

Marsh Animal Hospital

REFERRING VET

Dr. Armani

INVOICE

13837

DATE

02/16/26

The parenchyma of the left limb, body and right limb of the pancreas presented isoechoic to the adjacent omental fat. A normal curvilinear capsule contour of the pancreas was present. The visible pancreatic duct was normal. No signs of active inflammation or neoplastic disease was evident.

Free Abdomen

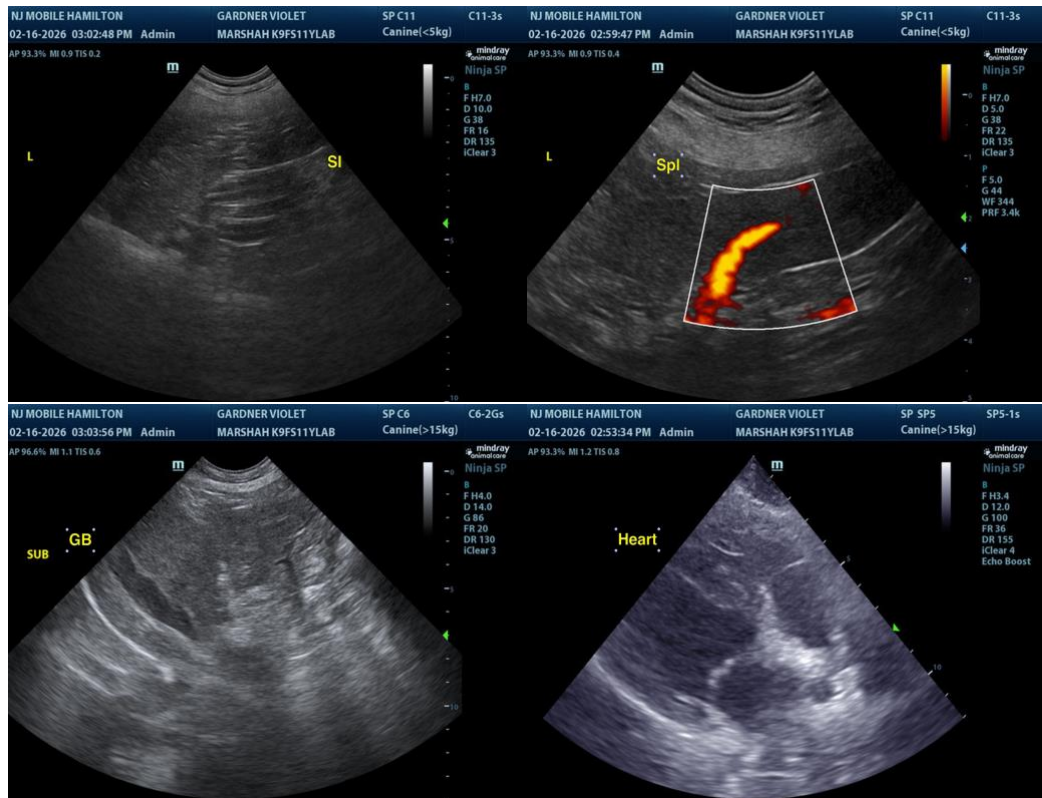
No overt lymphadenopathy or peritoneal effusion was present.

ULTRASONOGRAPHIC FINDINGS

- Normal echocardiogram.
- Borderline/mild hepatomegaly with mid liver lobar swelling and possible hepatoma-like mass.
- Nondistended gallbladder with mild bile sediment (non-mucocele).
- Age-related renal changes.
- Normal bilateral adrenal glands.

INTERPRETATION OF THE FINDINGS & FURTHER RECOMMENDATIONS

Potential for emerging to low-grade malignant hepatic neoplasia is thought less likely yet not definitively excluded. No evidence of post-hepatic stasis or obstruction. Assuming normal clotting status, FNA cytology of mid-liver lobar swelling to hepatoma-like mass is warranted for further clarification. Hepatosupportive medications including ursodiol trial with clinical and serial sonographic monitoring of the liver for evidence of progressive enlargement or lobar swelling would be a more conservative approach.





PATIENT

Violet Gardner

SPECIES

Canine

BREED

Labrador Retriever

SEX

Spayed Female

AGE

11 Years 2 Months

WEIGHT

63 pounds

INTERPRETED BY

R. McKenzie Daniel,
DVM, DABVP (Canine
/ Feline Practice)

**IMAGING
PERFORMED BY**

Rebecca Hamilton

HOSPITAL NAME

Marsh Animal Hospital

REFERRING VET

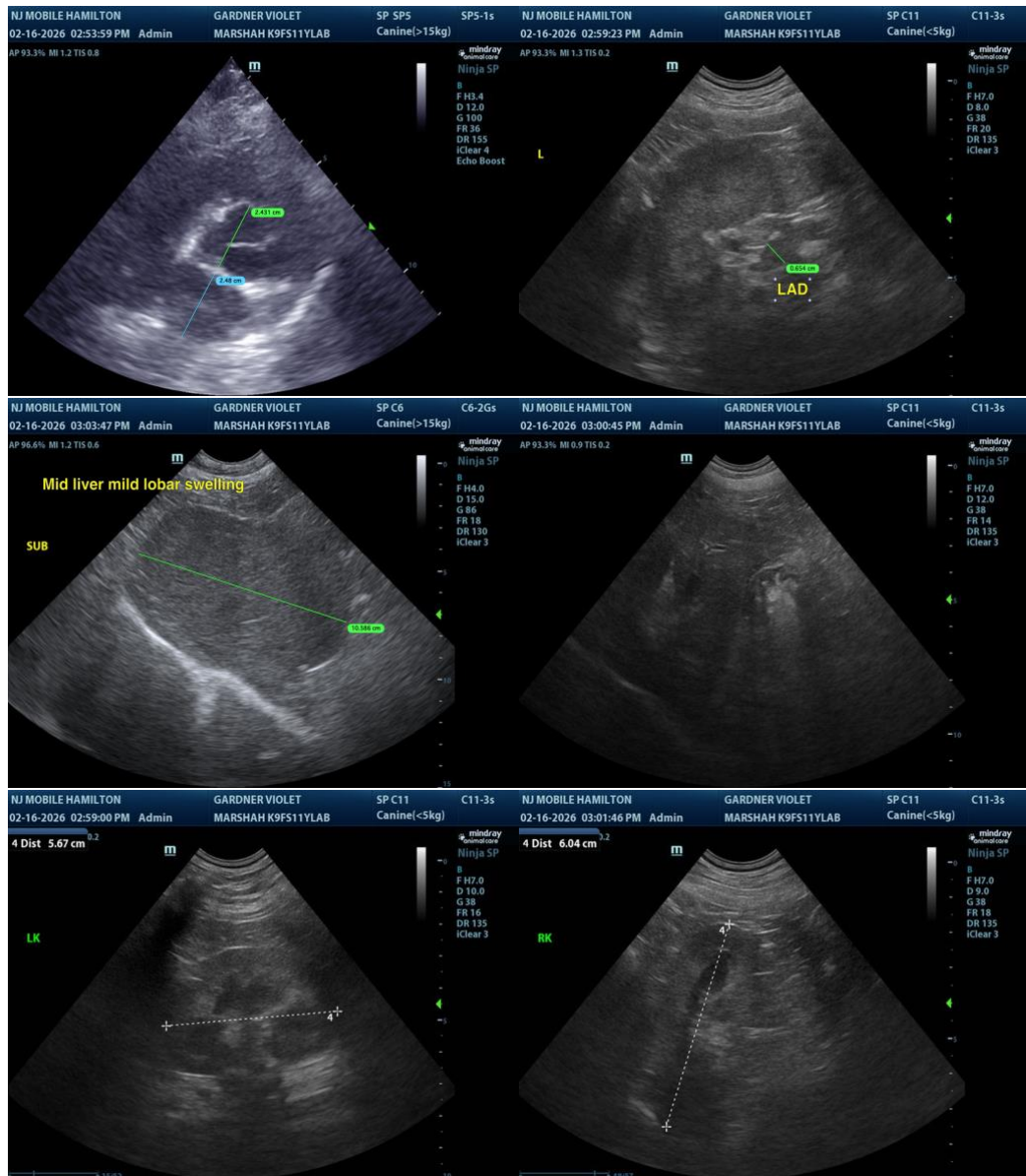
Dr. Armani

INVOICE

13837

DATE

02/16/26



The information and recommendations provided are based on the images presented by the referring veterinarian/sonographer. No evaluation can be communicated regarding pathology that was not visible in the image/video clips provided.

Thank you for this referral. If the clinical or image interpretation does not parallel your findings or if I can be of any further assistance, please contact me.

R. McKenzie Daniel, DVM, DABVP (Canine / Feline Practice)

info@SonoPath.com