



PATIENT PRESENTING CLINICAL SIGNS

Theo Fehr History: PU/PD for 1 year, 2/6 murmur, pre surgical, elevated liver values. Labs: ALP 7923, ALT 359, GGT 8, T.Bili 0.1, Albumin 3.5, Glucose 102, Cholesterol 309, BUN 12

SPECIES ULTRASONOGRAPHIC EXAMINATION OF THE ABDOMEN

Canine **Urinary System**

BREED

Pitbull

The urinary bladder, trigone, cystourethral junction, and visible pelvic urethra to a depth of 5.0 cm exhibited normal thickness and tone. Anechoic urine was present in the lumen with no uroliths or sediment. The ureteral papillae were normal. The ureters were not visible which is normal. No evidence of inflammatory or neoplastic changes were noted.

SEX

Neutered Male

The area of the residual prostate appeared normal and free of pathology.

The area of the iliac trifurcation was free of pathology.

AGE

2015

Normal size and margination were present in the kidneys. A normal 1:3 cortex / medulla ratio and normal corticomedullary definition were maintained. The echogenicity of the cortex was similar to or slightly less than normal liver parenchyma while the medulla echogenicity was hypoechoic to the cortex with no evidence of pelvic dilation. The left kidney measured 6.6 cm in length. The right kidney measured 7.3 cm in length. A solitary small cortical cysts was present in the left kidney.

WEIGHT

63

Adrenal Glands

The right adrenal gland was borderline prominent in size based on caudal pole measurement in light of body weight. No evidence of definitive adrenomegaly. No evidence of adrenal tumors. The right adrenal gland measured 3.9 cm length x 0.89 cm width at the caudal pole.

INTERPRETED BY

R. McKenzie Daniel,
DVM, DABVP
(Canine and Feline)

The left adrenal gland was uniform in size and contour with a uniformly hypoechoic parenchyma. The left adrenal gland measured 2.9 cm length x 0.77 cm width at the caudal pole.

Spleen

The spleen exhibited a finely textured and homogenous parenchyma which was hyperechoic to the liver and renal cortical parenchyma. The capsule was smooth and regular without apparent expansion. The splenic vasculature at the hilus was normal in volume with no evidence of congestion or thrombosis. Acute to chronic inflammatory, neoplastic, or benign parenchyma changes were not noted.

IMAGING PERFORMED BY

Rebekah Jakum, CVT
ARDMS/RVT

HOSPITAL NAME

Alburtis AH

Liver

The liver revealed subjective mild enlargement. The parenchyma of the liver was subjectively normal in echogenicity compared to the spleen and renal cortices. The liver parenchyma was uniform with a mildly coarse echotexture. The capsule of the liver was symmetrically rounded to mildly swollen in margination. The hepatic and portal vasculature were normal in appearance without signs of congestion.

REFERRING VET

Dr. Smith

The gallbladder was non-distended in size with anechoic content and mild nonorganized echogenic gallbladder debris, primarily in the caudal lumen in the area of the gallbladder neck. No evidence of gallbladder or peripheral gallbladder inflammation. The cystic and common bile ducts were normal.

INVOICE

21129

Gastrointestinal

DATE

2/16/23



PATIENT

Theo Fehr

The stomach presented intact wall layering with a normal wall layer ratio. The lumen of the stomach was empty with no signs of ileus, obstruction or foreign material.

SPECIES

Canine

The small intestine presented intact wall layering with 1:3 muscularis/mucosa ratio. The lumen of the small intestine was empty with no signs of ileus, obstruction or foreign material.

Normal visible colon wall layers were present with apparent formed feces in lumen.

Pancreas

BREED

Pitbull

The parenchyma of the left limb, body and right limb of the pancreas presented isoechoic to the adjacent omental fat. A normal curvilinear capsule contour of the pancreas was present. The visible pancreatic duct was normal. No signs of active inflammation or neoplastic disease was evident.

SEX

Neutered Male

Free Abdomen

No overt lymphadenopathy or peritoneal effusion was present.

ULTRASONOGRAPHIC FINDINGS

AGE

2015

- Small left kidney cortical cyst
- Hepatopathy- subjectively benign

WEIGHT

63

- Mild gallbladder debris (non-mucocele)
- Subjective borderline prominent right adrenal gland

INTERPRETATION OF THE FINDINGS & FURTHER RECOMMENDATIONS

INTERPRETED BY

R. McKenzie Daniel,
DVM, DABVP
(Canine and Feline)

The overall liver was nonspecific yet most consistent with benign hepatopathy. Considerations may include vacuolar hepatopathy, primary concurrent inflammatory/immune mediated disease, or other hepatopathy with infiltrative neoplasia considered unlikely. No evidence of posthepatic obstructive criteria. Full urinalysis with screening culture and sensitivity and baseline UPC level, if evidence of proteinuria, is recommended. The hepatic and adrenal presentation were not overtly consistent with primary adrenal disease yet full adrenal work up may be considered if strong clinical suspicion, based on clinical signs of adrenal hyperfunction. Leptospirosis/PCR is suggested if clinically applicable. Hepatosupportive medications, including Denamarin and Ursodiol may prove beneficial. No overt anesthetic contraindications given the evidence of normal hepatic function indicated by normal BUN, glucose, albumin and cholesterol levels. Hepatic sampling may be required for a definitive diagnosis.

IMAGING PERFORMED BY

Rebekah Jakum, CVT
ARDMS/RVT

HOSPITAL NAME

Alburtis AH

REFERRING VET

Dr. Smith

INVOICE

21129

DATE

2/16/23



PATIENT

Theo Fehr

SPECIES

Canine

BREED

Pitbull

SEX

Neutered Male

AGE

2015

WEIGHT

63

INTERPRETED BY

R. McKenzie Daniel,
DVM, DABVP
(Canine and Feline)

IMAGING PERFORMED BY

Rebekah Jakum, CVT
ARDMS/RVT

HOSPITAL NAME

Alburtis AH

REFERRING VET

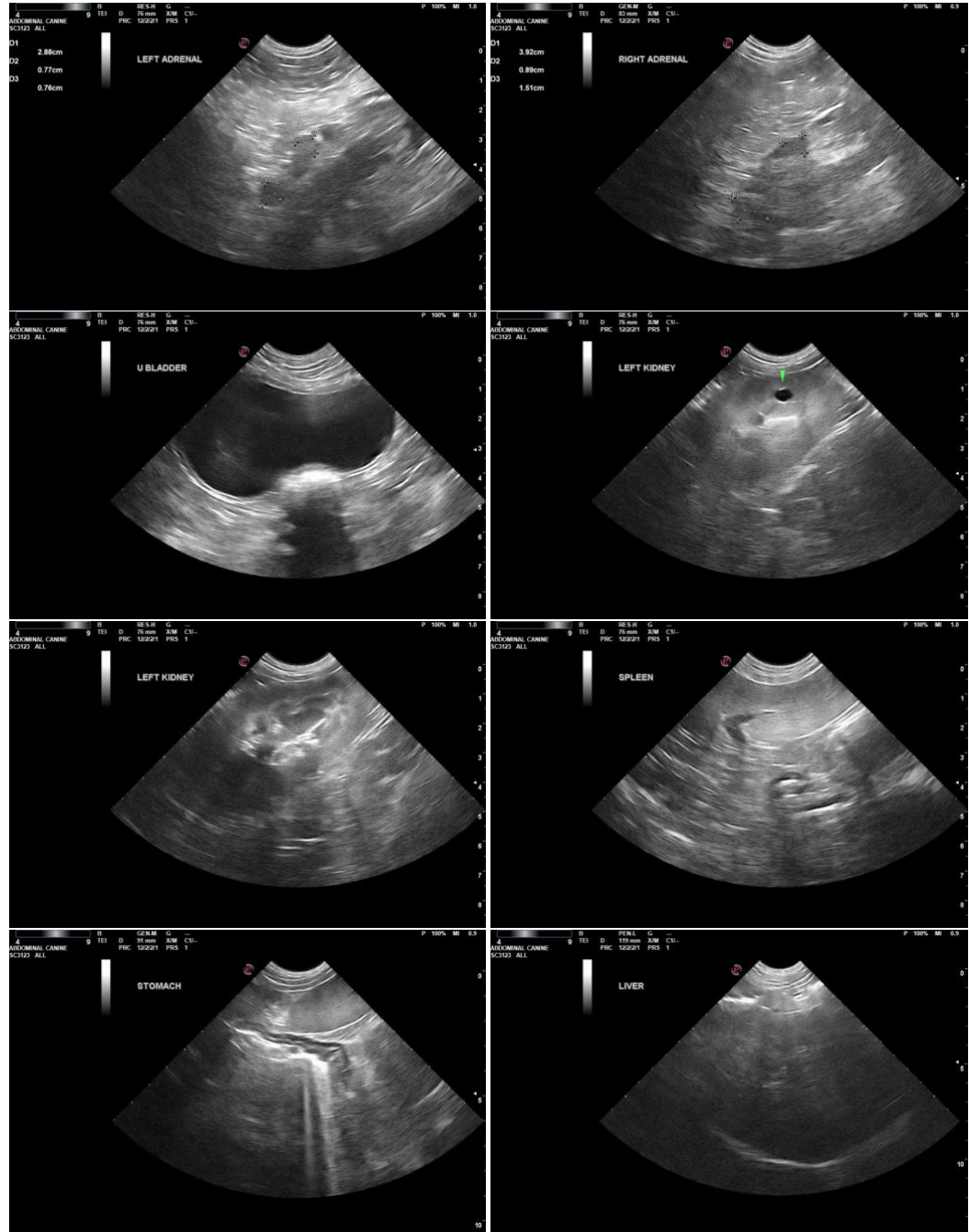
Dr. Smith

INVOICE

21129

DATE

2/16/23





PATIENT

Theo Fehr

SPECIES

Canine

BREED

Pitbull

SEX

Neutered Male

AGE

2015

WEIGHT

63

INTERPRETED BY

R. McKenzie Daniel,
DVM, DABVP
(Canine and Feline)

IMAGING PERFORMED BY

Rebekah Jakum, CVT
ARDMS/RVT

HOSPITAL NAME

Alburtis AH

REFERRING VET

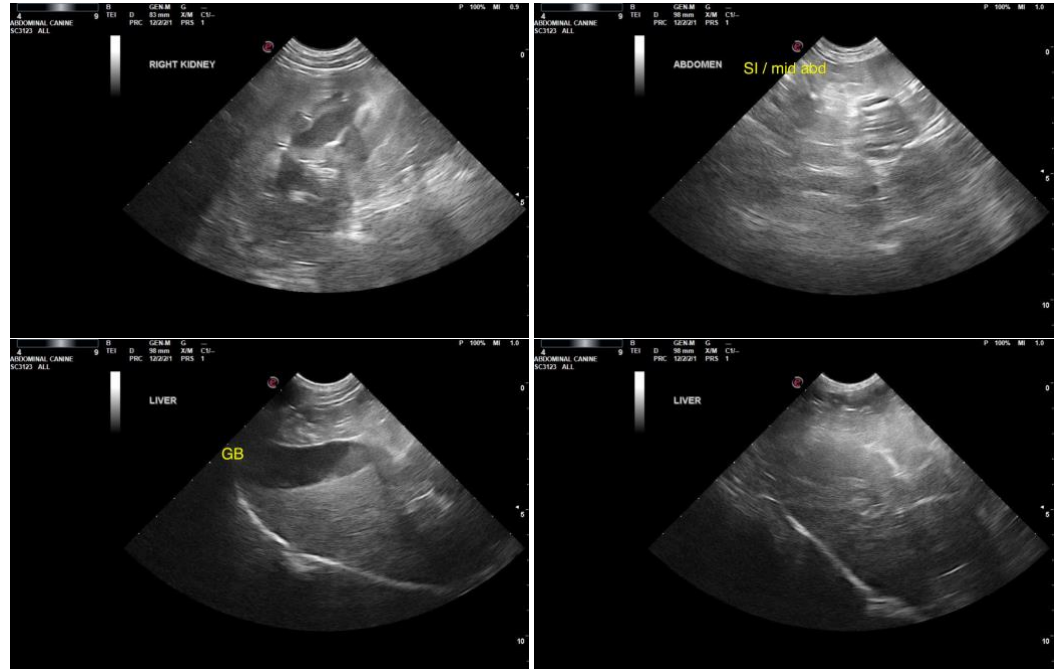
Dr. Smith

INVOICE

21129

DATE

2/16/23



The information and recommendations provided are based on the images presented by the referring veterinarian. No evaluation can be communicated regarding pathology that was not visible in the image/video clips provided.

Thank you for this referral. If the clinical or image interpretation does not parallel your findings or if I can be of any further assistance please contact me.

R. McKenzie Daniel, DVM, DABVP (Canine / Feline Practice)
info@SonoPath.com