



PATIENT PRESENTING CLINICAL SIGNS

Kris Upton Weight loss, thin BCS, occasional vomiting.

ULTRASONOGRAPHIC EXAMINATION OF THE ABDOMEN

SPECIES

Feline

Urinary System

The urinary bladder, trigone, cystourethral junction, and visible pelvic urethra exhibited normal thickness and tone. Primarily anechoic urine was present in the lumen. Mild, nondependent, particulate to focally hyperechoic sediment was present without evidence of calculus formation. The ureteral papillae were normal. The ureters were not visible which is normal. No evidence of inflammatory criteria, tumors, or neoplastic mural changes were noted. The urinary bladder sediment may suggest cellular / crystalline debris or mucus. Cystocentesis for UA +/- C/S if evidence of inflammatory cells is recommended.

BREED

DSH

SEX

MN

The area of the aortic trifurcation was free of pathology.

AGE

2009

Normal size and margination were present in the kidneys. A normal 1:3 cortex / medulla ratio was maintained. The medulla and cortices were uniform in texture with some increased echogenicity and mild to moderate loss of corticomedullary symmetry and definition expected for the age of the patient. No evidence of pelvic dilation was present. The left kidney measured 4.6 cm in length. The right kidney measured 4.2 cm in length.

WEIGHT

5.6

Adrenal Glands

The left adrenal gland was uniform in size and contour with a uniformly hypoechoic parenchyma. The left adrenal gland measured 0.4 cm width. No overt pathology was noted in the area of the right adrenal gland.

INTERPRETED BY

R. McKenzie Daniel,
 DVM, DABVP
 (Canine and Feline)

Spleen

The spleen exhibited a finely textured and homogenous parenchyma which was hyperechoic to the liver and renal cortical parenchyma. The capsule was smooth and regular without apparent expansion. The splenic vasculature at the hilus was normal in volume with no evidence of congestion or thrombosis. Acute to chronic inflammatory, neoplastic, or benign parenchyma changes were not noted.

IMAGING

PERFORMED BY

Rebekah Jakum, CVT
 ARDMS/RVT

HOSPITAL NAME

Easton AH

Liver/ Gallbladder

The liver exhibited potential borderline to mild enlargement. The parenchyma of the liver was subjectively increased in echogenicity compared to the spleen and renal cortices. The echotexture of the liver parenchyma was uniform with a mild coarse echotexture. The capsule of the liver was symmetrical in margination. The hepatic and portal vasculature were normal in appearance without signs of congestion. Normal hepatic vascular volume was present. No masses or nodules were noted. The gallbladder was non-distended in size with primarily anechoic luminal content. The cystic and common bile ducts were normal.

REFERRING VET

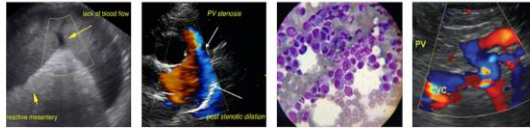
Dr. Yaswinski

INVOICE

16212

DATE

2/16/23



PATIENT *Gastrointestinal*

Kris Upton The stomach presented intact wall layering with a normal wall layer ratio. The lumen of the stomach was empty with no signs of ileus, obstruction, or foreign material. The gastric body wall width measured 0.25 cm.

SPECIES

Feline The small intestine presented generalized intact wall layering with subjective propensity for subtly prominent muscularis layer without overt evidence of significant intestinal mural hypertrophy. No visualized loss of intestinal wall layering or intestinal masses were noted to the level of the ileocolic junction.

BREED

DSH Normal visible colon wall layers were present with semi-formed fecal matter.

SEX

Pancreas

MN The parenchyma of the left limb, body, and right limb of the pancreas presented isoechoic to the adjacent omental fat. A normal curvilinear capsule contour of the pancreas was present. The visible pancreatic duct was normal. No signs of active inflammation or neoplastic disease were evident.

AGE

Free Abdomen

2009

Several variably enlarged mild asymmetrical homogeneous to mildly hyperechoic mesenteric lymph nodes were present mid-abdomen. An example of lymph node size was 3.6 cm x 0.85 cm. The lymph nodes appeared to primarily maintain a normal width: length ratio (<0.5). Mild volume peritoneal effusion was present. Mild generalized primarily peri intestinal echogenic omentum was noted.

WEIGHT

5.6

ULTRASONOGRAPHIC FINDINGS

INTERPRETED BY

- Chronic enteropathy pattern with associated mesenteric lymphadenopathy
- Borderline to mild hepatomegaly exhibiting subtle parenchyma hyperechogenicity
- Mild chronic renal changes
- Mild volume peritoneal effusion
- Urinary bladder sediment

R. McKenzie Daniel,
 DVM, DABVP
 (Canine and Feline)

IMAGING PERFORMED BY

Rebekah Jakum, CVT
 ARDMS/RVT

HOSPITAL NAME

Easton AH

REFERRING VET

Dr. Yaswinski

INTERPRETATION OF THE FINDINGS & FURTHER RECOMMENDATIONS

The intestinal appearance in conjunction with decreased body condition and weight loss with gastrointestinal signs is consistent with primary intestinal disease i.e., chronic IBD or other with associated suspected mesenteric lymphatic hyperplasia or reactive lymphadenitis. The potential for neoplastic infiltrative enteropathy with round cells such as lymphoma and emerging neoplastic lymphadenopathy, which may present in a similar sonographic manner, cannot be excluded. Likewise, concurrent low-grade to chronic pancreatitis or Triad Disease could be possible.

INVOICE

16212

Further assessment may include a GI panel to include PLI/TLI/Cobalamin/Folate, hepato-lymphatic FNA cytology, assuming normal clotting status +/- effusion analysis. Empirical therapy for IBD +/- Triad Disease with an assessment of clinical response, as-needed gastrointestinal support, and monitoring of body weight going forward would be reasonable.

DATE

2/16/23



PATIENT

Kris Upton

SPECIES

Feline

BREED

DSH

SEX

MN

AGE

2009

WEIGHT

5.6

INTERPRETED BY

R. McKenzie Daniel,
DVM, DABVP
(Canine and Feline)

IMAGING PERFORMED BY

Rebekah Jakum, CVT
ARDMS/RVT

HOSPITAL NAME

Easton AH

REFERRING VET

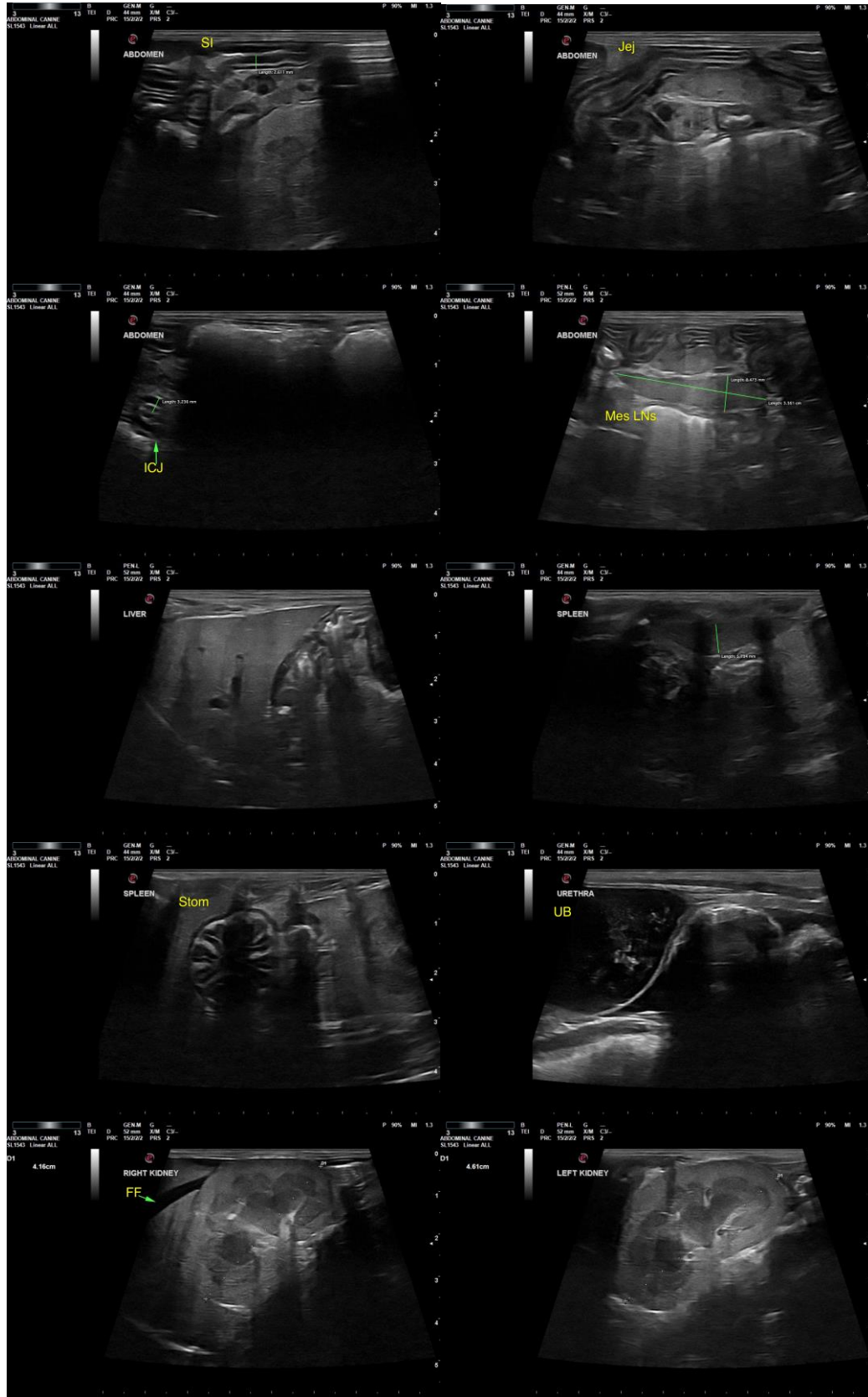
Dr. Yaswinski

INVOICE

16212

DATE

2/16/23





PATIENT

Kris Upton

SPECIES

Feline

BREED

DSH

SEX

MN

AGE

2009

WEIGHT

5.6

INTERPRETED BY

R. McKenzie Daniel,
DVM, DABVP
(Canine and Feline)

IMAGING

PERFORMED BY

Rebekah Jakum, CVT
ARDMS/RVT

HOSPITAL NAME

Easton AH

REFERRING VET

Dr. Yaswinski

INVOICE

16212

DATE

2/16/23

The information and recommendations provided are based on the images presented by the referring veterinarian/sonographer. No evaluation can be communicated regarding pathology that was not visible in the image/video clips provided.

Thank you for this referral. If the clinical or image interpretation does not parallel your findings or if I can be of any further assistance, please contact me.

R. McKenzie Daniel, DVM, DABVP (Canine/Feline Practice)
mac.daniel@sonopath.com