



## PATIENT

Brock Baxter

## SPECIES

Canine

## BREED

Greyhound Mix

## SEX

M/N

## AGE

10 years

## WEIGHT

20 kg

## INTERPRETED BY

R. McKenzie Daniel,  
DVM, DABVP  
(Canine and Feline)

## IMAGING PERFORMED BY

Dave Stasiuk RDMS,  
RDCE

## HOSPITAL NAME

Woodlands  
Veterinary Hospital

## REFERRING VET

Dr. Tom LeBoldus

## INVOICE

16202

## DATE

2/16/23

## PRESENTING CLINICAL SIGNS

Hx of MR. Prior echo done with Sonopath in June/July 2022. Reassess MR and chamber sizes.

## ULTRASONOGRAPHIC EXAMINATION OF THE HEART

CANINE	MR	TR	LA/AO	LA/AO	FS	EF	EPSS
<b>CARDIAC PARAMETERS</b>	<b>VMAX</b> (m/s)	<b>VMAX</b> (m/s)	(Boon method)	(Heart Base; Swe)	(%)	(%)	(cm)
<b>NORMAL PARAMETER</b>	4.5-5.5	<2.7	1.3	<1.3	28-40	40-100	<0.6
<b>PATIENT</b>				1.2	34	68	0.22
CANINE	HR	AV	PV	BODY WEIGHT	LA	LVIDd	LVIDs
<b>CARDIAC PARAMETERS</b>	(BPM)	<b>VMAX</b> (m/s)	<b>MAX</b> (m/s)	(kg)	2D short axis Base view (cm)	Avg; 2D and m-mode short axis (cm)	Avg; 2D and m-mode short axis (cm)
<b>NORMAL PARAMETER</b>	50-100	0.7-1.7	0.7-1.6				
<b>PATIENT</b>	NM	1.2	0.94		4.3	4.3	

## Cardiac Presentation

The echocardiogram in this patient demonstrated normal **left atrial** size based on 3 different LA measurement methods. Chamber volumes and echogenicity were normal. The cranial and caudal **mitral** valve leaflets presented vegetative thickening consistent with endocardiosis. Doppler indicated mild to moderate eccentric insufficiency. The **left ventricle** presented thicknesses with linear contour and was not dilated nor restricted. The **myocardium** presented normal echogenicity without subjective evidence of significant fibrotic or ischemic disease. **Contractility** of the ventricular walls was adequate and in normal range for this patient evidenced by the fractional shortening measurement and subjective evaluation of the different regions of the myocardium. The **left ventricular outflow** tract demonstrated normal laminar flow and subjective structural integrity. The **right atrium** and auricle revealed normal size, structure and content. No evidence of masses was noted or chamber overload. **Tricuspid** valvular assessment demonstrated adequate linear morphology. The **right ventricle** was of normal size (1/3 diameter of LV), chordae structure, myocardial echogenicity and thickness. **Pulmonic** tract assessment revealed normal valve structure, laminar flow, and diameter (approx. 1:1 pa/ao ratio). No visible **pericardial** or free pleura fluid was noted. No echographically detectable evidence of infiltrative disease was visible. The cranial **mediastinum and pericardial regions** were free of masses in the visible window.

## ULTRASONOGRAPHIC FINDINGS

- Static, compensated, chronic mitral valve disease (ACVIM B1)



**PATIENT**

Brock Baxter

**SPECIES**

Canine

**BREED**

Greyhound Mix

**SEX**

M/N

**AGE**

10 years

**WEIGHT**

20 kg

**INTERPRETED BY**

R. McKenzie Daniel,  
DVM, DABVP  
(Canine and Feline)

**IMAGING PERFORMED BY**

Dave Stasiuk RDMS,  
RDCS

**HOSPITAL NAME**

Woodlands  
Veterinary Hospital

**REFERRING VET**

Dr. Tom LeBoldus

**INVOICE**

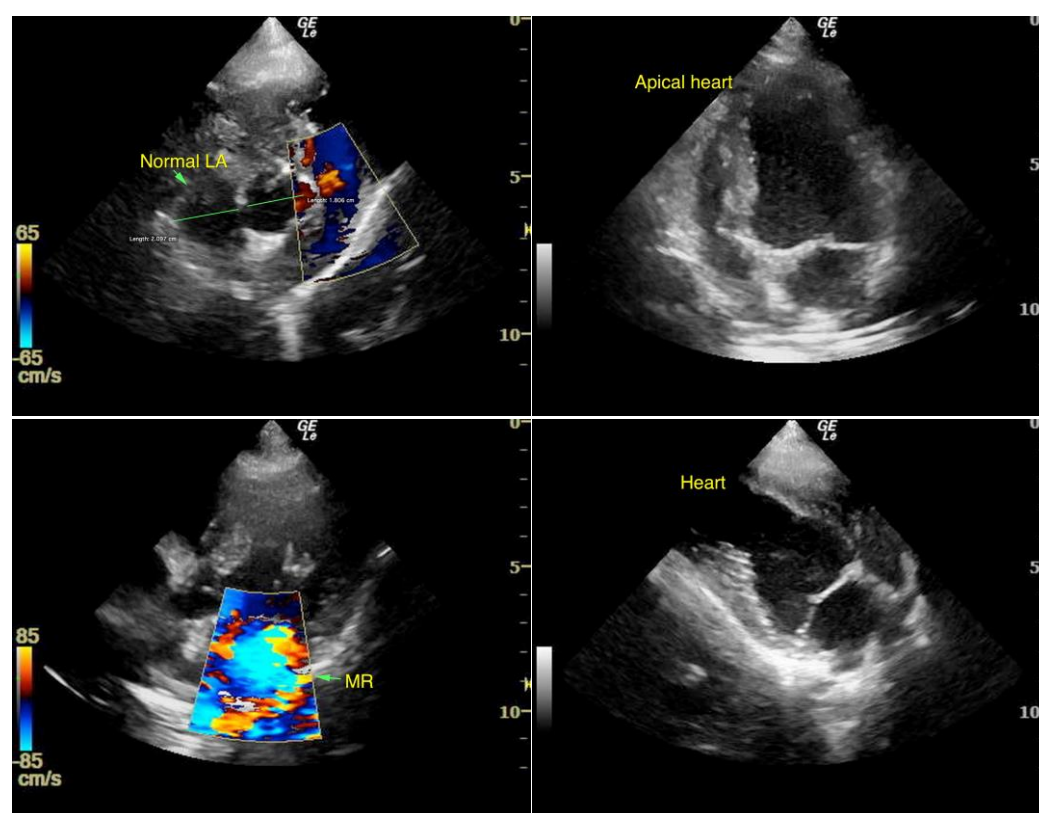
16202

**DATE**

2/16/23

**INTERPRETATION OF THE FINDINGS & FURTHER RECOMMENDATIONS**

No evidence of significant progression compared to the previous study with overall static cardiac presentation. The normal LA size continues to indicate that the risk of current and future complications secondary to MR is low. No indication for cardiac medications. Continued monitoring at this stage would be appropriate. However, the prognosis is variable and sonographic monitoring is recommended. Recheck echocardiogram is recommended in 6-12 months, sooner if clinical signs arise.



The information and recommendations provided are based on the images presented by the referring veterinarian/sonographer. No evaluation can be communicated regarding pathology that was not visible in the image/video clips provided.

Thank you for this referral. If the clinical or image interpretation does not parallel your findings or if I can be of any further assistance please contact me.

**R. McKenzie Daniel, DVM, DABVP (Canine / Feline Practice)**  
info@SonoPath.com