SonoPath
Clinical Sonography & Telecytology
EDUCATIONAL TELECONSULTATION SERVICES™

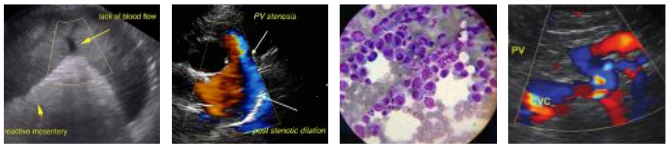

SonoPath.com™
1-800-838-4268 info@sonopath.com

PATIENT
Ady Farm Corgis

SPECIES
Canine

BREED
Corgi

SEX
F/S

AGE
5 years

WEIGHT
27

INTERPRETED BY
R. McKenzie Daniel, DVM, DABVP (Canine and Feline)

IMAGING PERFORMED BY
Nicole Gotfredson

HOSPITAL NAME
Buffalo Veterinary Clinic

REFERRING VET
Garry Gotfredson DVM

INVOICE
16191

DATE
2/16/23

PRESENTING CLINICAL SIGNS

Dog was previously diagnosed with a splenic nodule September 2022 while doing a pregnancy check. At that time mass measured 14mmx13mm. The dog then had C-section and the portion of the spleen that was visualized by the veterinarian appeared normal. Recheck ultrasound December 2022 and measured 14.2mmx15.6mm.

ULTRASONOGRAPHIC EXAMINATION OF THE ABDOMEN

Urinary System

The urinary bladder, trigone, cystourethral junction, and visible pelvic urethra to a depth of 3.0 cm exhibited normal thickness and tone. Anechoic urine was present in the lumen with no uroliths or sediment. The ureteral papillae were normal. The ureters were not visible which is normal. No evidence of inflammatory or neoplastic changes was noted.

No evidence of pathology was noted In the area of the uterine remnant.

The area of the aortic trifurcation was free of pathology.

Normal size and margination were present in the kidneys. A normal 1:3 cortex / medulla ratio and normal corticomedullary definition were maintained. The echogenicity of the cortex was similar to or slightly less than normal liver parenchyma while the medulla echogenicity was hypoechoic to the cortex with no evidence of pelvic dilation. The left kidney measured 5.2 cm in length. The right kidney measured 5.5 cm in length.

Adrenal Glands

The left adrenal gland was uniform in size and contour with a uniformly hypoechoic parenchyma. The left adrenal gland measured 0.55 cm width. The right adrenal gland was not definitively visualized.

Spleen

The spleen exhibited overall normal size with a primarily maintained symmetrical capsule contour and finely textured and homogenous parenchyma. A solitary, well-demarcated, spherical, uniform hypoechoic, subtly expansive nodule was present in the medial spleen measuring 1.6 cm x 1.5 cm.

Liver/ Gallbladder

The liver was subjectively normal in size, structure, and contour. The liver parenchyma was uniform and hypoechoic to the spleen with a mild coarse echotexture. The hepatic and portal vasculature were normal in appearance without signs of congestion. The gallbladder was non-distended in size with thin walls and primarily anechoic luminal content. The cystic and common bile ducts were normal.

Gastrointestinal

The stomach presented intact wall layering with a normal wall layer ratio. The lumen of the stomach contained echogenic, nonshadowing ingesta without signs of obstruction or foreign material. This is likely recent meal ingestion, the stomach was otherwise normal.

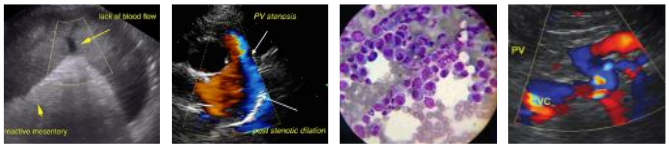

SonoPath.com™
1-800-838-4268 info@sonopath.com

PATIENT

Ady Farm Corgis

SPECIES

Canine

BREED

Corgi

SEX

F/S

AGE

5 years

WEIGHT

27

INTERPRETED BY

R. McKenzie Daniel, DVM, DABVP (Canine and Feline)

IMAGING PERFORMED BY

Nicole Gotfredson

HOSPITAL NAME

Buffalo Veterinary Clinic

REFERRING VET

Garry Gotfredson DVM

INVOICE

16191

DATE

2/16/23

The small intestine presented intact wall layering with 1:3 muscularis/mucosa ratio. The lumen of the small intestine was empty with no signs of ileus, obstruction, or foreign material.

Normal visible colon wall layers were present with apparent formed feces in lumen.

Pancreas

The parenchyma of the left limb, body, and right limb of the pancreas presented isoechoic to the adjacent omental fat. A normal curvilinear capsule contour of the pancreas was present. The visible pancreatic duct was normal. No signs of active inflammation or neoplastic disease were evident.

Free Abdomen

No omental masses, lymphadenopathy, or evidence of peritoneal free fluid were noted.

Rapid view of the heart revealed no evidence of pericardial masses or effusion in the visible window.

ULTRASONOGRAPHIC FINDINGS

- Solitary well-demarcated uniform hypoechoic subtly expansive splenic nodule
- Otherwise, sonographically normal abdomen

INTERPRETATION OF THE FINDINGS & FURTHER RECOMMENDATIONS

The confirmed splenic nodule appears to be of similar size compared to the previous measurement. Considerations may include hyperplasia, hematopoiesis, granuloma, or focal inflammation, while the potential for slow-progressing neoplastic criteria cannot be excluded.

Assuming normal clotting status and using a 25-gauge needle, ultrasound-guided FNA cytology of the splenic nodule is suggested for further clarification. Given that the splenic nodule appears to be of similar dimension compared to the previous study without overt evidence of significant progression, serial sonographic monitoring for evidence of progression pending recommended cytology would be reasonable.

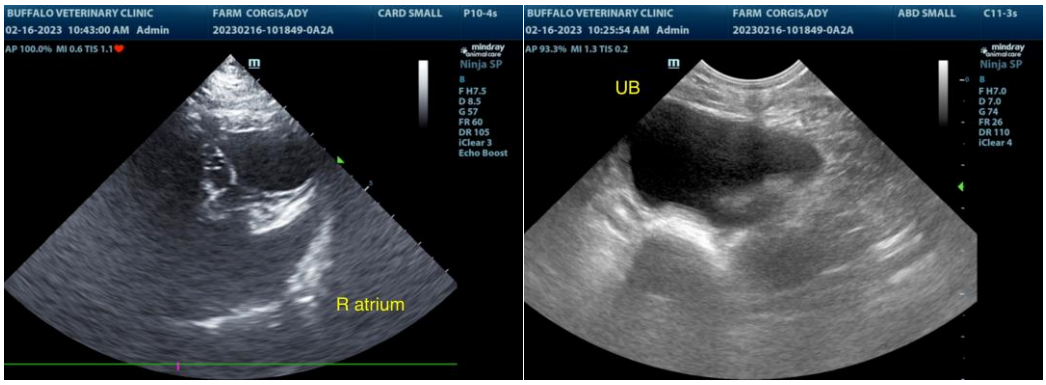

SonoPath

Clinical Sonography & Telecytology

EDUCATIONAL TELECONSULTATION SERVICES™

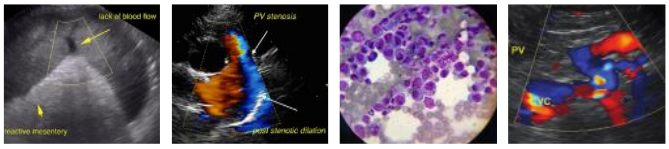

SonoPath.com™
1-800-838-4268 info@sonopath.com

PATIENT

Ady Farm Corgis

SPECIES

Canine

BREED

Corgi

SEX

F/S

AGE

5 years

WEIGHT

27

INTERPRETED BY

R. McKenzie Daniel, DVM, DABVP (Canine and Feline)

IMAGING PERFORMED BY

Nicole Gotfredson

HOSPITAL NAME

Buffalo Veterinary Clinic

REFERRING VET

Garry Gotfredson DVM

INVOICE

16191

DATE

2/16/23

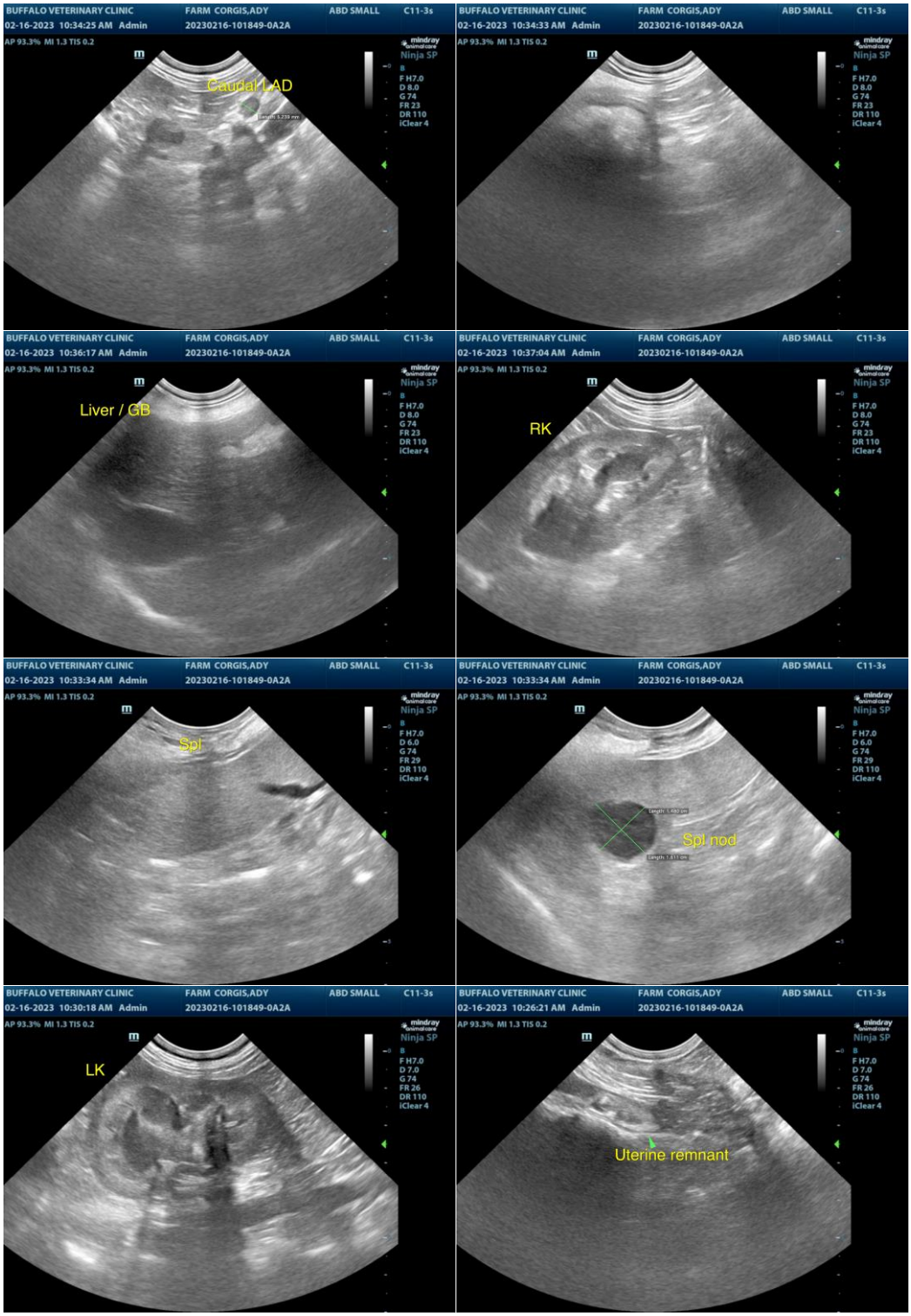

The information and recommendations provided are based on the images presented by the referring veterinarian/sonographer. No evaluation can be communicated regarding pathology that was not visible in the image/video clips provided.

SonoPath
Clinical Sonography & Telecytology
EDUCATIONAL TELECONSULTATION SERVICES™

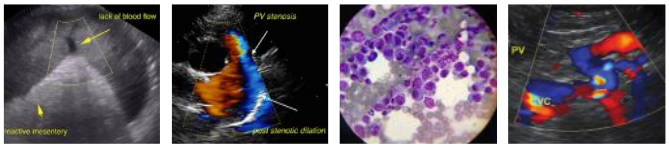

SonoPath.com™
1-800-838-4268 info@sonopath.com

PATIENT

Ady Farm Corgis

SPECIES

Canine

BREED

Corgi

SEX

F/S

AGE

5 years

WEIGHT

27

INTERPRETED BY

R. McKenzie Daniel, DVM, DABVP (Canine and Feline)

IMAGING PERFORMED BY

Nicole Gotfredson

HOSPITAL NAME

Buffalo Veterinary Clinic

REFERRING VET

Garry Gotfredson DVM

INVOICE

16191

DATE

2/16/23

Thank you for this referral. If the clinical or image interpretation does not parallel your findings or if I can be of any further assistance please contact me.

R. McKenzie Daniel, DVM, DABVP (Canine / Feline Practice)
info@SonoPath.com