



PATIENT

Fergie Blackwood

SPECIES

Feline

BREED

Bouvier Des Flanders

SEX

F/I

AGE

7 yrs, 6 mo

WEIGHT

40.05 kg

INTERPRETED BY

R. McKenzie Daniel,
DVM, DABVP
(Canine and Feline)

IMAGING PERFORMED BY

Dr. Brian Barnes

HOSPITAL NAME

Westview VH

REFERRING VET

Dr. Brian Barnes

INVOICE

16184

DATE

2/15/23

PRESENTING CLINICAL SIGNS

Senior Screen CBC - Neutrophils mildly decreased Chem - TCO2 30 (13-27) - Glob 21 (24-40) - Alb:Glob ratio 1.8 (0.7 - 1.5) - Chol 10.1 (3.4 - 8.9) Cardiopet proBNP 1181 (0-900) TT4 WNL Mild elevation BNP, Heart normal rhythm, no murmurs Lungs - Clear lungs sounds, NAF Pre anesthetic work up

ULTRASONOGRAPHIC EXAMINATION OF THE HEART & ABDOMEN

CANINE CARDIAC PARAMETERS	MR VMAX (m/s)	TR VMAX (m/s)	LA/AO (Boon method)	LA/AO (Heart Base; Swe)	FS (%)	EF (%)	EPSS (cm)
NORMAL PARAMETER	4.5-5.5	<2.7	1.3	<1.3	28-40	40-100	<0.6
PATIENT				1.35	30	58	0.4
CANINE CARDIAC PARAMETERS	HR (BPM)	AV VMAX (m/s)	PV MAX (m/s)	BODY WEIGHT (kg)	LA 2D short axis Base view (cm)	LVIDd Avg; 2D and m- mode short axis (cm)	LVIDs Avg; 2D and m-mode short axis (cm)
NORMAL PARAMETER	50-100	0.7-1.7	0.7-1.6				
PATIENT	NM	1.0	0.6		4.4	4.4	

Cardiac Presentation

The echocardiogram in this patient demonstrated normal **left atrial** size based on 3 separate methods of LA evaluation. The cranial and caudal **mitral** valve leaflets presented normal linear structure, extension in systole, and union in diastole with normal kinesis. No overt MR was present on Doppler. The **left ventricle** presented thicknesses with linear contour and was not dilated nor restricted. The **myocardium** presented normal echogenicity without subjective evidence of significant fibrotic or ischemic disease. **Contractility** of the ventricular walls was borderline subnormal as evidenced by the fractional shortening measurement and subjective evaluation of the different regions of the myocardium. The **left ventricular outflow** tract demonstrated normal laminar flow and subjective structural integrity. The **right atrium** and auricle revealed normal size, structure and content. No evidence of masses was noted. **Tricuspid** valvular assessment demonstrated adequate linear morphology and kinesis. Trace TR was noted on Doppler without evidence of clinical pulmonary hypertension, and considered incidental. The **right ventricle** was of normal size (1/3 diameter of LV), chordae structure, myocardial echogenicity and thickness. **Pulmonary outflow** tract assessment revealed normal valve structure, laminar flow, and diameter (approx.1:1 pa/ao ratio). No visible **pericardial** or free pleura fluid was noted. The cranial **mediastinum and pericardial and extra-cardiac regions** were free of masses in the visible window. No arrhythmia was noted.



PATIENT

Fergie Blackwood

SPECIES

Feline

BREED

Bouvier Des Flanders

SEX

F/I

AGE

7 yrs, 6 mo

WEIGHT

40.05 kg

INTERPRETED BY

R. McKenzie Daniel,
DVM, DABVP
(Canine and Feline)

**IMAGING
PERFORMED BY**

Dr. Brian Barnes

HOSPITAL NAME

Westview VH

REFERRING VET

Dr. Brian Barnes

INVOICE

16184

DATE

2/15/23

Urinary System

The urinary bladder, trigone, cystourethral junction, and visible pelvic urethra exhibited normal thickness and tone. Anechoic urine was present in the lumen with no uroliths or sediment. The ureteral papillae were normal. The ureters were not visible which is normal. No evidence of inflammatory or neoplastic changes was noted.

The uterus and area of ovaries were free of pathology.

The area of the aortic trifurcation was free of pathology.

Normal size and margination were present in the kidneys. A normal 1:3 cortex / medulla ratio and normal corticomedullary definition were maintained. The echogenicity of the cortex was similar to or slightly less than normal liver parenchyma while the medulla echogenicity was hypoechoic to the cortex with no evidence of pelvic dilation. The left kidney measured 6.8 cm in length. The right kidney measured 7.0 cm in length.

Adrenal Glands

The left adrenal gland was uniform in size and contour with a uniformly hypoechoic parenchyma. The left adrenal gland measured 2.2 cm length x 0.55 cm width at the caudal pole. The right adrenal gland was uniform in size and contour with a uniformly hypoechoic parenchyma. The right adrenal gland measured 2.5 cm length x 0.54 cm width at the caudal pole.

Spleen

The spleen exhibited a finely textured and homogenous parenchyma which was hyperechoic to the liver and renal cortical parenchyma. The capsule was smooth and regular without apparent expansion. The splenic vasculature at the hilus was normal in volume with no evidence of congestion or thrombosis. Acute to chronic inflammatory, neoplastic, or benign parenchyma changes were not noted.

Liver/ Gallbladder

The liver was subjectively normal in size, structure, and contour. The liver parenchyma was uniform and hypoechoic to the spleen with a mild coarse echotexture. The hepatic and portal vasculature were normal in appearance without signs of congestion. The gallbladder was non-distended in size with thin walls and primarily anechoic luminal content. The cystic and common bile ducts were normal.

Gastrointestinal

The stomach presented intact wall layering with a normal wall layer ratio. The lumen of the stomach was empty with no signs of ileus, obstruction, or foreign material.

The small intestine presented intact wall layering with 1:3 muscularis/mucosa ratio. The lumen of the small intestine was empty with no signs of ileus, obstruction, or foreign material.

Normal visible colon wall layers were present with apparent formed feces in lumen.



PATIENT

Fergie Blackwood

SPECIES

Feline

BREED

Bouvier Des Flanders

SEX

F/I

AGE

7 yrs, 6 mo

WEIGHT

40.05 kg

INTERPRETED BY

R. McKenzie Daniel,
DVM, DABVP
(Canine and Feline)

IMAGING PERFORMED BY

Dr. Brian Barnes

HOSPITAL NAME

Westview VH

REFERRING VET

Dr. Brian Barnes

INVOICE

16184

DATE

2/15/23

Pancreas

The parenchyma of the left limb, body, and right limb of the pancreas presented isoechoic to the adjacent omental fat. A normal curvilinear capsule contour of the pancreas was present. The visible pancreatic duct was normal. No signs of active inflammation or neoplastic disease were evident.

Free Abdomen

No overt lymphadenopathy or peritoneal effusion was present.

ULTRASONOGRAPHIC FINDINGS

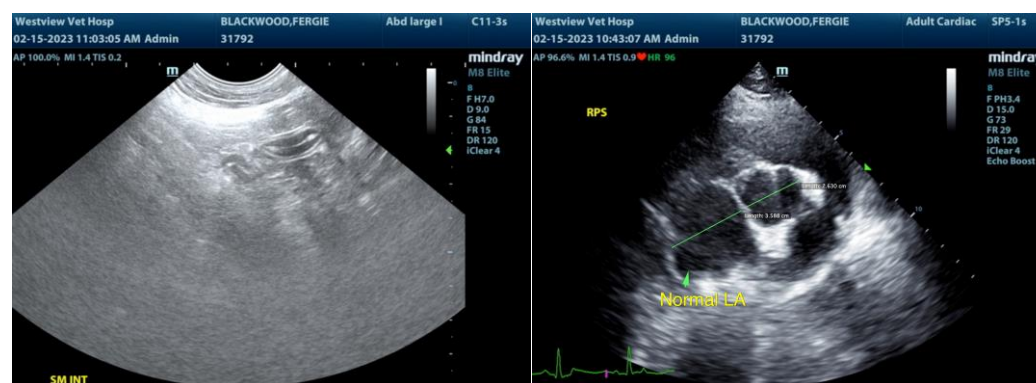
- Normal echocardiogram with borderline LV hypocontractility - Athletic state can present in this manner, DCM criteria was not present
- Sonographically unremarkable abdomen

INTERPRETATION OF THE FINDINGS & FURTHER RECOMMENDATIONS

Overall, no sonographic evidence of cardiac or abdominal visceral pathology.

The borderline subnormal LV contractility is suspected to be incidental or a patient variant assuming no clinical signs of heart disease. Ideally, recheck echocardiogram is recommended in 6 months, primarily to ensure nonobvious to emerging cardiomyopathy. No overt anesthetic contraindications, as well as no indication for cardiac medications.

Suggested anesthetic protocol may include opioid or Benzodiazepine pre-med, induction with Propofol or Alfaxalone, and appropriate gas anesthesia with avoidance of alpha 2 agonists.





PATIENT

Fergie Blackwood

SPECIES

Feline

BREED

Bouvier Des Flanders

SEX

F/I

AGE

7 yrs, 6 mo

WEIGHT

40.05 kg

INTERPRETED BY

R. McKenzie Daniel,
DVM, DABVP
(Canine and Feline)

IMAGING PERFORMED BY

Dr. Brian Barnes

HOSPITAL NAME

Westview VH

REFERRING VET

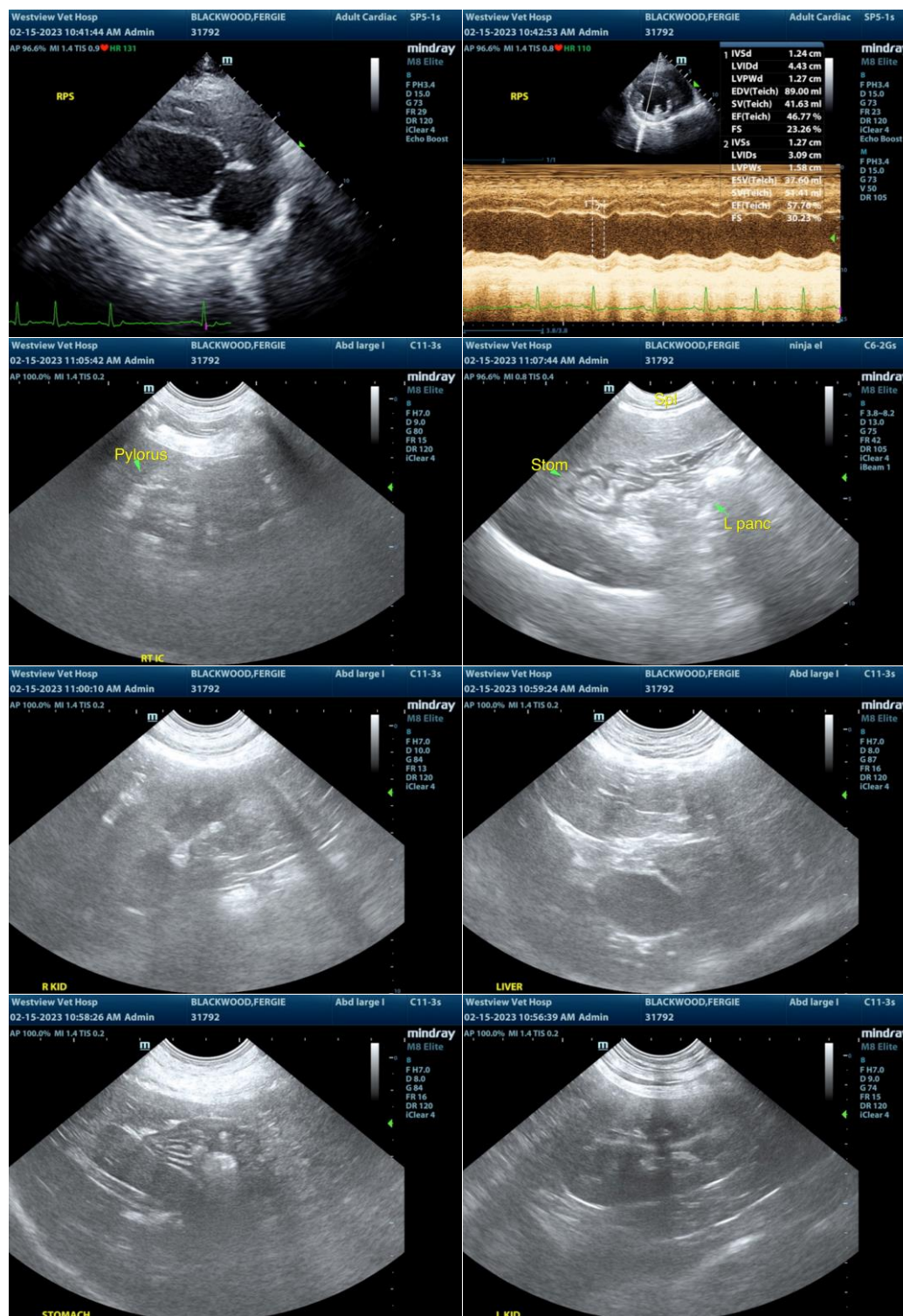
Dr. Brian Barnes

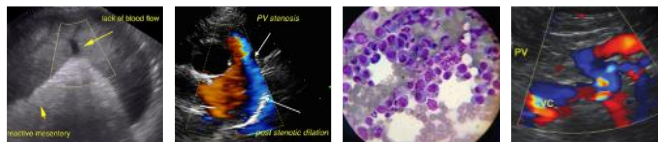
INVOICE

16184

DATE

2/15/23





PATIENT

Fergie Blackwood

SPECIES

Feline

BREED

Bouvier Des Flanders

SEX

F/I

AGE

7 yrs, 6 mo

WEIGHT

40.05 kg

INTERPRETED BY

R. McKenzie Daniel,
DVM, DABVP
(Canine and Feline)

IMAGING PERFORMED BY

Dr. Brian Barnes

HOSPITAL NAME

Westview VH

REFERRING VET

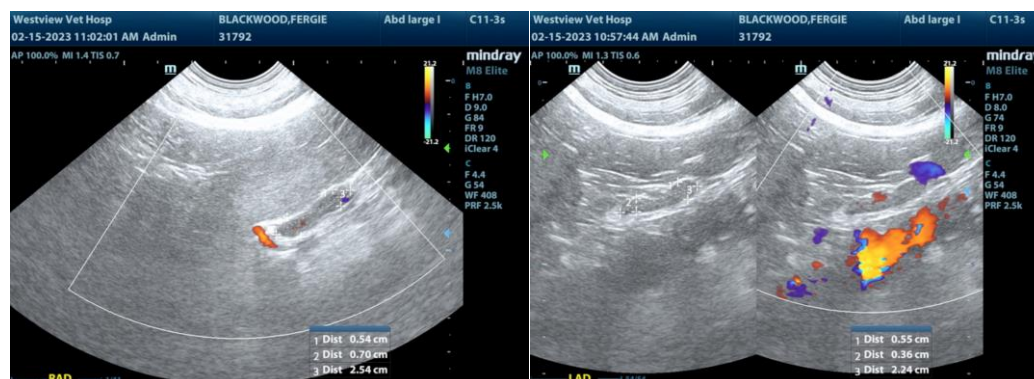
Dr. Brian Barnes

INVOICE

16184

DATE

2/15/23



The information and recommendations provided are based on the images presented by the referring veterinarian/sonographer. No evaluation can be communicated regarding pathology that was not visible in the image/video clips provided.

Thank you for this referral. If the clinical or image interpretation does not parallel your findings or if I can be of any further assistance please contact me.

R. McKenzie Daniel, DVM, DABVP (Canine / Feline Practice)
info@SonoPath.com