


**PATIENT**

Mia Arslanian

**SPECIES**

Canine

**BREED**

Chihuahua

**PRESENTING CLINICAL SIGNS**

History of atypical Addison's disease, controlled with Pred. 1 mg SID. In 12/20 a cytology of an enlarged submandibular lymph node revealed lymphoma no further treatment sought, but lymph node returned to normal and patient has had no issues. Now, both submandibular lymph nodes are enlarged and the patient has developed a grade 2/6 systolic heart murmur over the mitral valve.

Current med: Pred. 1 mg SID.

Abnormal PE/Chem/CBC/UA Results: Albumin 2.6, ALT 185, Alk. Phos. 744, GGT 387, glucose 147, Ca. 8.2, PLTs 609. U/A: pending.

**ULTRASONOGRAPHIC EXAMINATION OF THE ABDOMEN AND HEART**

SEX	CANINE CARDIAC PARAMETERS	MR VMAX (m/s)	TR VMAX (m/s)	LA/AO (Boon method)	LA/AO (Heart Base; Swe)	FS (%)	EF (%)	EPSS (cm)
FS								
AGE	NORMAL PARAMETER	4.5-5.5	<2.7	1.3	<1.3	28-40	40-100	<0.6
10yr	PATIENT		<2.0	1.3	1.3	48	82	0.2
WEIGHT	CANINE CARDIAC PARAMETERS	HR (BPM)	AV VMAX (m/s)	PV MAX (m/s)	BODY WEIGHT (kg)	LA 2D short axis Base view (cm)	LVIDd Avg; 2D and m-mode short axis (cm)	LVIDs Avg; 2D and m-mode short axis (cm)
5.3lb								
INTERPRETED BY	NORMAL PARAMETER	50-100	0.7-1.7	0.7-1.6				
R. McKenzie Daniel, DVM, DABVP (Canine and Feline)	PATIENT	123	1.2	0.84		2.0	2.0	

**Cardiac Presentation**

The echocardiogram in this patient demonstrated normal left atrial size based on 3 separate methods of LA evaluation. The cranial and caudal mitral valve leaflets presented normal linear structure, extension in systole, and union in diastole with normal kinesis. No overt MR on Doppler. The left ventricle presented thicknesses with linear contour and was not dilated nor restricted. The myocardium presented normal echogenicity without subjective evidence of significant fibrotic or ischemic disease. Contractility of the ventricular walls was adequate and in normal range for this patient evidenced by the fractional shortening measurement and subjective evaluation of the different regions of the myocardium. The left ventricular outflow tract demonstrated normal laminar flow and subjective structural integrity. Normal measured LVOT velocity. The right atrium and auricle revealed normal size, structure and content. No evidence of masses was noted. Tricuspid valvular assessment demonstrated adequate linear morphology and kinesis. Mild TR on Doppler. The right ventricle was of normal size (1/3 diameter of LV), chordae structure, myocardial echogenicity and thickness. Pulmonary outflow tract assessment revealed normal valve structure, laminar flow, and diameter (approx.1:1 pa/ao ratio). Normal measured RVOT velocity. No visible pericardial or free pleural fluid was noted. The cranial mediastinum and pericardial and extra-cardiac regions were free of masses in the visible window.

**Urinary System**
**IMAGING PERFORMED BY**

Kelly Vazquez

**HOSPITAL NAME**

Midland Park Veterinary Hospital

**REFERRING VET**

Dr. Shokoff

**INVOICE**

12953ag

**DATE**

02/13/2023



<b>PATIENT</b>	The urinary bladder, trigone, cystourethral junction, and visible pelvic urethra to a depth of 3 cm exhibited normal thickness and tone. Anechoic urine was present in the lumen with no uroliths or sediment. The ureteral papillae were normal. The ureters were not visible which is normal. No evidence of inflammatory or neoplastic changes were noted.
Mia Arslanian	
<b>SPECIES</b>	Normal size and margination were present in the kidneys. A normal 1:3 cortex / medulla ratio was maintained. The medulla and cortices were uniform in texture with some increased echogenicity and mild loss of corticomedullary symmetry and definition expected for the age of the patient. No evidence of pelvic dilation was present. The left kidney measured 3.3 cm in length. The right kidney measured 3.6 cm in length.
Canine	
<b>BREED</b>	The area of the aortic trifurcation was free of pathology.
Chihuahua	
<b>SEX</b>	The area of the iliac trifurcation was free of pathology including no evidence of medial, iliac or sublumbar lymphadenopathy.
FS	
<b>AGE</b>	<b>Adrenal Glands</b>
10yr	The left adrenal gland was uniform in size and contour with a uniformly hypoechoic parenchyma. The left adrenal gland measured 0.26 cm width at the caudal pole and 1.1 cm length. The right adrenal gland was uniform in size and contour with a uniformly hypoechoic parenchyma. The right adrenal gland measured 0.34 cm width at the caudal pole and 1.4 cm length.
<b>WEIGHT</b>	<b>Spleen</b>
5.3lb	The spleen exhibited normal size and contour with subtle parenchyma heterogeneity. A discrete hyperechoic non-disruptive perihilar nodule was present in the medial parenchyma. The splenic vasculature at the hilus was normal in volume with no evidence of congestion or thrombosis.
<b>INTERPRETED BY</b>	<b>Liver/Gallbladder</b>
R. McKenzie Daniel, DVM, DABVP (Canine and Feline)	The liver exhibited mild enlargement with minor parenchyma remodeling. An ill-defined uniform hyperechoic mass/lesion was present in the mid liver measuring 5.0 cm in diameter. The lesion did not appear to distort the hepatic capsule. The hepatic and portal vasculature were normal in appearance without signs of congestion. The gallbladder was non-distended in size with thin walls and primarily anechoic luminal content. Possible mild caudal gallbladder displacement owing to the liver mass/lesion was present. The cystic and common bile ducts were normal.
<b>IMAGING PERFORMED BY</b>	<b>Gastrointestinal</b>
Kelly Vazquez	The stomach presented intact wall layering with a normal wall layer ratio. The lumen of the stomach was empty with no signs of ileus, obstruction or foreign material.
<b>HOSPITAL NAME</b>	The small intestine presented intact wall layering with 1:3 muscularis/mucosa ratio. The lumen of the small intestine was empty with no signs of ileus, obstruction or foreign material.
Midland Park Veterinary Hospital	
<b>REFERRING VET</b>	Normal visible colon wall layers were present with apparent formed feces in lumen.
Dr. Shokoff	
<b>INVOICE</b>	<b>Pancreas</b>
12953ag	The pancreas was normal in size and contour with isoechoic to heterogeneous parenchyma compared to adjacent omentum. No signs of active inflammation or neoplasia.
<b>DATE</b>	<b>Free Abdomen</b>
02/13/2023	No omental masses, overt lymphadenopathy or peritoneal effusion was present.



**PATIENT**

Mia Arslanian

**ULTRASONOGRAPHIC FINDINGS**

**SPECIES**

Canine

**BREED**

Chihuahua

- Normal echocardiogram
- Mild TR
- Non-specific hepatic intraparenchymal mass/lesion-hematopoiesis, hyperplasia, granuloma or neoplasia all potentials
- Mild age related renal changes
- Minor pancreatic remodeling-benign, likely age related pancreatic changes
- Benign splenic nodule-consistent with benign myelolipoma

**INTERPRETATION OF THE FINDINGS & FURTHER RECOMMENDATIONS**

**SEX**

FS

**AGE**

10yr

A definitive cause of the patient's murmur was not evident without evidence of structural or functional cardiomyopathy. No evidence of clinical issues such as left or right heart chamber enlargement, LV systolic dysfunction or clinical pulmonary hypertension was present. If no volume changes such as dehydration or anemia are present, a benign physiologic flow murmur or small flow abnormality/valvular insufficiency including non-obvious MR is suspected. Regardless, the lack of left or right heart chamber enlargement indicate that the hemodynamic effects of the murmur are low. No indication for cardiac medications. Continued conservative monitoring of the murmur is recommended. Recheck echocardiogram recommended in 6-12 months, sooner if murmur intensity increases or clinical signs suggestive of heart disease arise.

**WEIGHT**

5.3lb

Assuming normal clotting status and using a 25g needle, a hepatic mass/lesion FNA for screening cytology is warranted for further assessment. No evidence of intra-abdominal or pericardiac thoracic lymphadenopathy. Three view chest radiographs are recommended if not done to assess for occult thoracic pathology.

**INTERPRETED BY**

R. McKenzie Daniel,  
DVM, DABVP  
(Canine and Feline)

Empirical hepatosupportive medications such as Denamarin and Ursodiol may prove beneficial.

**IMAGING PERFORMED BY**

Kelly Vazquez

**HOSPITAL NAME**

Midland Park  
Veterinary Hospital

**REFERRING VET**

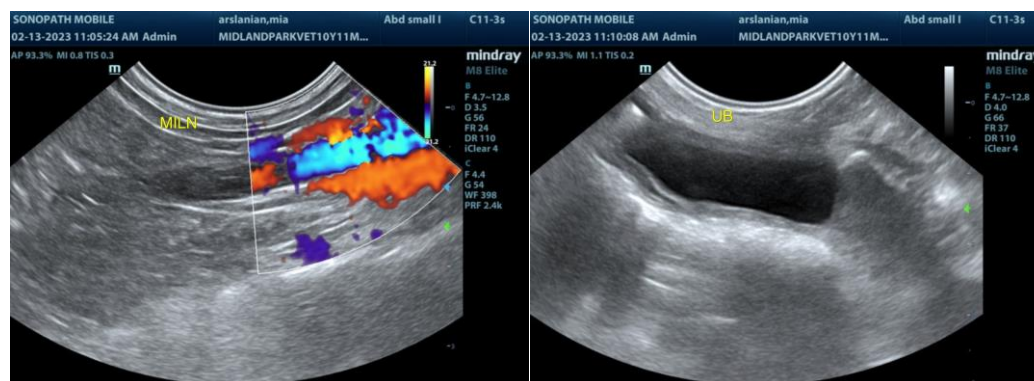
Dr. Shokoff

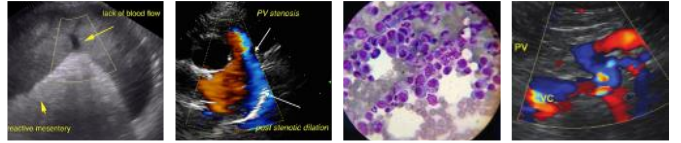
**INVOICE**

12953ag

**DATE**

02/13/2023





**PATIENT**

Mia Arslanian

**SPECIES**

Canine

**BREED**

Chihuahua

**SEX**

FS

**AGE**

10yr

**WEIGHT**

5.3lb

**INTERPRETED BY**

R. McKenzie Daniel,  
DVM, DABVP  
(Canine and Feline)

**IMAGING PERFORMED BY**

Kelly Vazquez

**HOSPITAL NAME**

Midland Park  
Veterinary Hospital

**REFERRING VET**

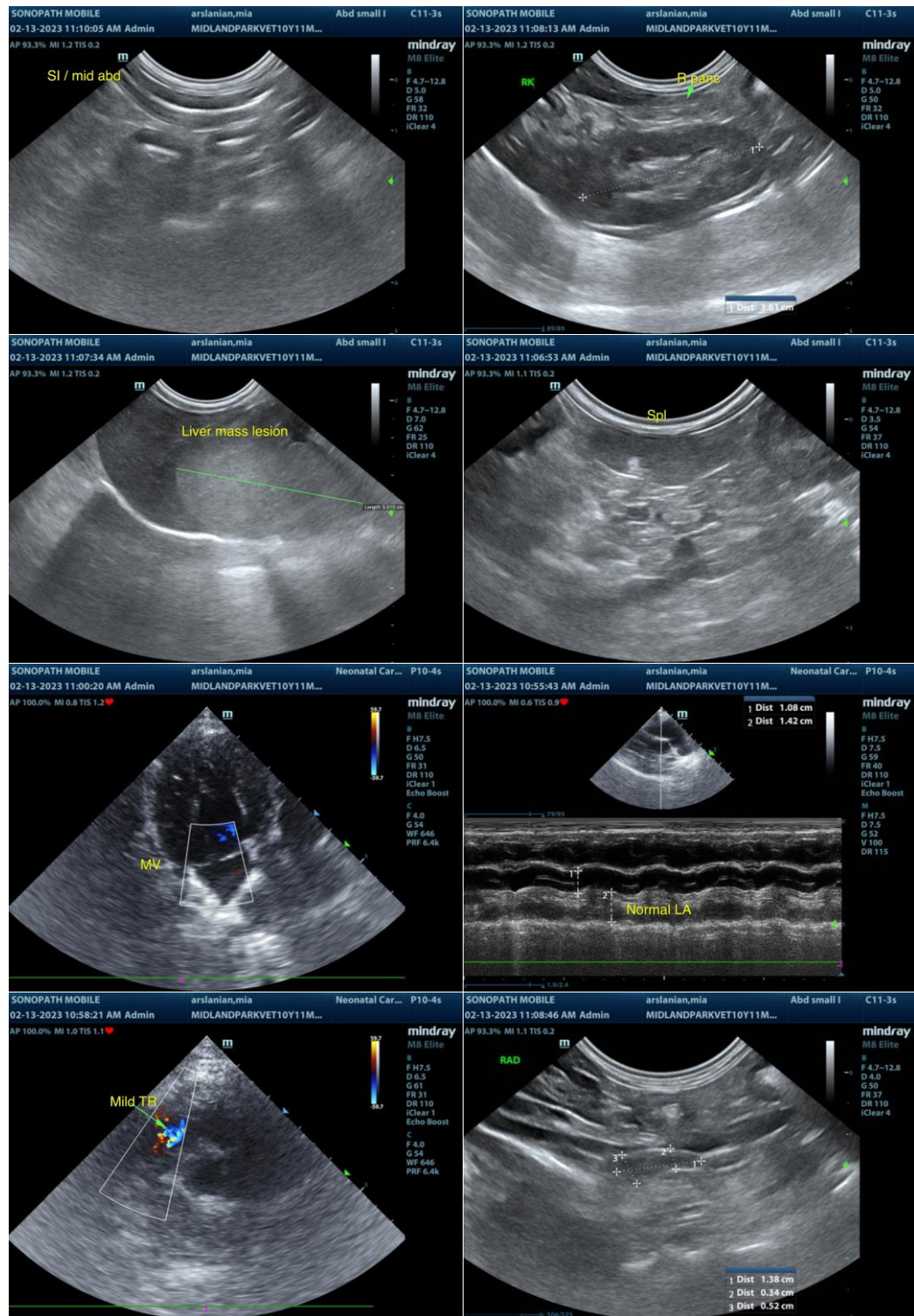
Dr. Shokoff

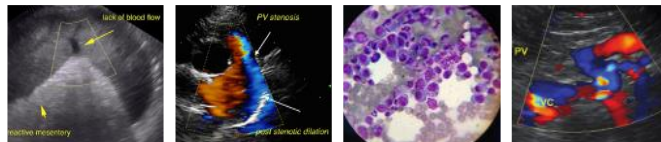
**INVOICE**

12953ag

**DATE**

02/13/2023





**PATIENT**

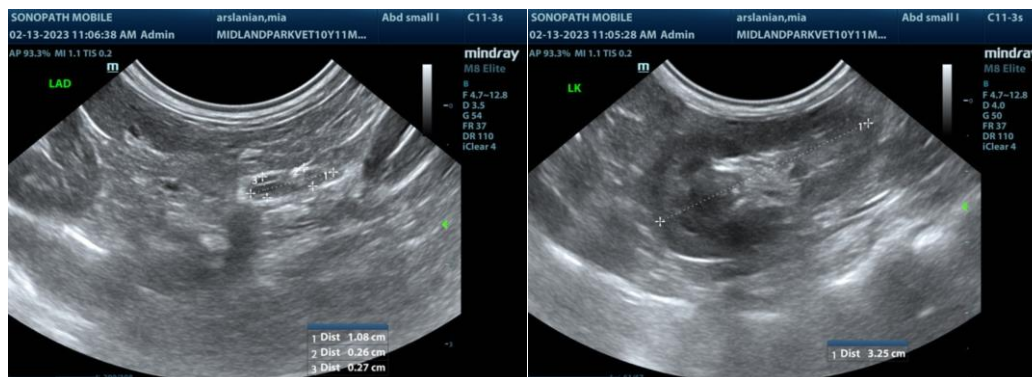
Mia Arslanian

**SPECIES**

Canine

**BREED**

Chihuahua



**SEX**

FS

**AGE**

10yr

**WEIGHT**

5.3lb

The information and recommendations provided are based on the images presented by the referring veterinarian/sonographer. No evaluation can be communicated regarding pathology that was not visible in the image/video clips provided.

Thank you for this referral. If the clinical or image interpretation does not parallel your findings or if I can be of any further assistance, please contact me.

R. McKenzie Daniel, DVM, DABVP (Canine/Feline Practice)  
[mac.daniel@sonopath.com](mailto:mac.daniel@sonopath.com)

**INTERPRETED BY**

R. McKenzie Daniel,  
DVM, DABVP  
(Canine and Feline)

**IMAGING PERFORMED BY**

Kelly Vazquez

**HOSPITAL NAME**

Midland Park  
Veterinary Hospital

**REFERRING VET**

Dr. Shokoff

**INVOICE**

12953ag

**DATE**

02/13/2023