



PATIENT PRESENTING CLINICAL SIGNS

Lady Bug Amaral Vomiting; weight loss. Sedated with torb/dexdom

SPECIES ULTRASONOGRAPHIC EXAMINATION OF THE ABDOMEN

Feline Urinary System

The urinary bladder, trigone, cystourethral junction, and visible pelvic urethra exhibited normal thickness and tone. Anechoic urine was present in the lumen with no uroliths or sediment. The ureteral papillae were normal. The ureters were not visible which is normal. No evidence of inflammatory or neoplastic changes were noted.

BREED

DLH

SEX

FS

Normal renal size with asymmetrical margination was present in both kidneys. The renal cortex presented uniformly increased in echogenicity with uniform echotexture. The renal cortex appeared to be hypertrophied resulting in an altered cortex: medulla ratio. Mild loss of corticomedullary distinction was also present. Mild pinpoint to dystrophic medullary mineral was present. The renal medullary volume was subjectively reduced. The left kidney measured 2.8 cm in length. The right kidney measured 3.4 cm in length.

AGE

20yr

The area of the aortic trifurcation was free of pathology.

Adrenal Glands

WEIGHT

9lb

The bilateral adrenal glands were normal in size and contour. Pinpoint areas of mineralization were present without capsular distortion or overt tumors. This is an age-related finding and not pathological. The left adrenal gland measured 0.30 width and the right adrenal gland measured 0.31 width.

INTERPRETED BY

R. McKenzie Daniel, DVM,
DABVP (Canine and Feline)

Spleen

The spleen exhibited a finely textured and homogenous parenchyma which was hyperechoic to the liver and renal cortical parenchyma. The capsule was smooth and regular without apparent expansion. The splenic vasculature at the hilus was normal in volume with no evidence of congestion or thrombosis. Acute to chronic inflammatory, neoplastic, or benign parenchyma changes were not noted. The spleen measured 0.91 cm in width at the level of the hilus.

IMAGING PERFORMED BY

Pamela Harrigan, RDCS

Liver/Gallbladder

The liver was mildly enlarged with evidence of minor congestive criteria likely owing to sedation. Generalized mild non-uniform increased parenchyma echogenicity with discrete hypoechoic nodules was present and focal to intermittent cortical cysts. The gallbladder was non-distended in size with thin walls and primarily anechoic luminal content with mild congealed non-organized echogenic debris. The cystic and common bile ducts were normal.

HOSPITAL NAME

Mashpee Veterinary Hospital

REFERRING VET

Dr. Oldham

Gastrointestinal

The stomach presented intact wall layering with a normal wall layer ratio. The lumen of the stomach was empty with no signs of ileus, obstruction or foreign material. The ventral gastric body wall measured 0.23 cm in diameter.

INVOICE

12959ag

The small intestine presented intact wall layering with 1:3 muscularis/mucosa ratio. Mildly thickened upper duodenum with indistinct wall layer detail was present. The thickened upper duodenum wall measured 0.31 cm in width. By comparison intact duodenum wall measured 0.23 cm in width. The jejunum wall measured 0.20 cm in width. The lumen of the small intestine was empty with no signs of ileus, obstruction or foreign material.

DATE

02/13/2023

Normal visible colon wall layers were present with apparent formed feces in lumen.



PATIENT

Pancreas

Lady Bug Amaral

The pancreas presented hypoechoic to heterogeneous echogenicity compared to adjacent omental fat. Mild asymmetrical capsule margination was present with mild variable parenchymal swelling and mild peripancreatic reactivity / inflammation. No overt evidence of neoplasia. Minor right limb pancreatic duct dilation was present.

SPECIES

Feline

Free Abdomen

BREED

No omental masses, overt lymphadenopathy or peritoneal effusion was present.

DLH

ULTRASONOGRAPHIC FINDINGS

SEX

FS

- Moderate chronic renal changes with pinpoint dystrophic medullary mineral
- Mildly thickened upper duodenum
- Suspect chronic active pancreatitis
- Mild hepatic parenchyma hyperechogenicity with intermittent discrete nodules and cortical cysts
- Mild gallbladder debris

AGE

20yr

INTERPRETATION OF THE FINDINGS & FURTHER RECOMMENDATIONS

Potential causes of the vomiting and weight loss may include suspected chronic active pancreatitis, chronic inflammatory enteropathy with potential for triad disease if evidence of hepatic enzyme elevation. Assessment for evidence of cranial abdominal or subxiphoid discomfort on palpation which may allude to pancreatitis is suggested. A GI panel to include PLI/TLI/Cobalamin/Folate is recommended. Three view chest radiographs are recommended if not done to assess for occult thoracic pathology. Full CBC/Chem/UA is suggested to assess for hepatic enzyme elevation or other comorbidities which may be contributing factors.

WEIGHT

9lb

INTERPRETED BY

R. McKenzie Daniel, DVM,
 DABVP (Canine and Feline)

IMAGING PERFORMED BY

Pamela Harrigan, RDCS

HOSPITAL NAME

Mashpee Veterinary
 Hospital

REFERRING VET

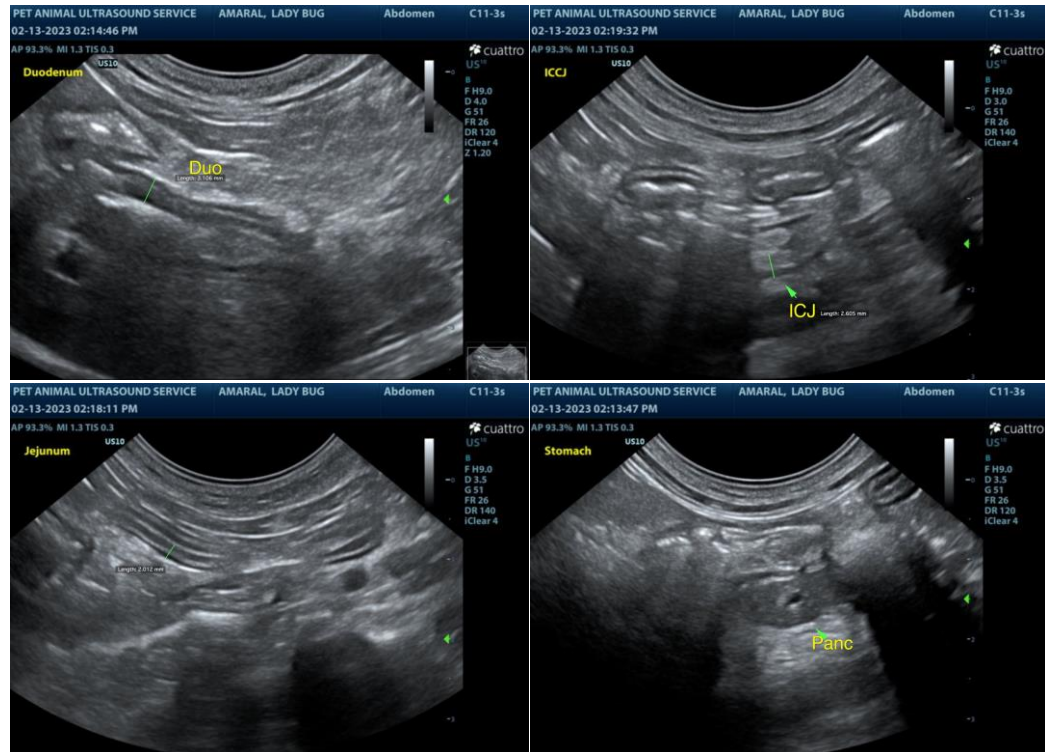
Dr. Oldham

INVOICE

12959ag

DATE

02/13/2023





PATIENT

Lady Bug Amaral

SPECIES

Feline

BREED

DLH

SEX

FS

AGE

20yr

WEIGHT

9lb

INTERPRETED BY

R. McKenzie Daniel, DVM,
 DABVP (Canine and Feline)

IMAGING PERFORMED BY

Pamela Harrigan, RDCS

HOSPITAL NAME

Mashpee Veterinary
 Hospital

REFERRING VET

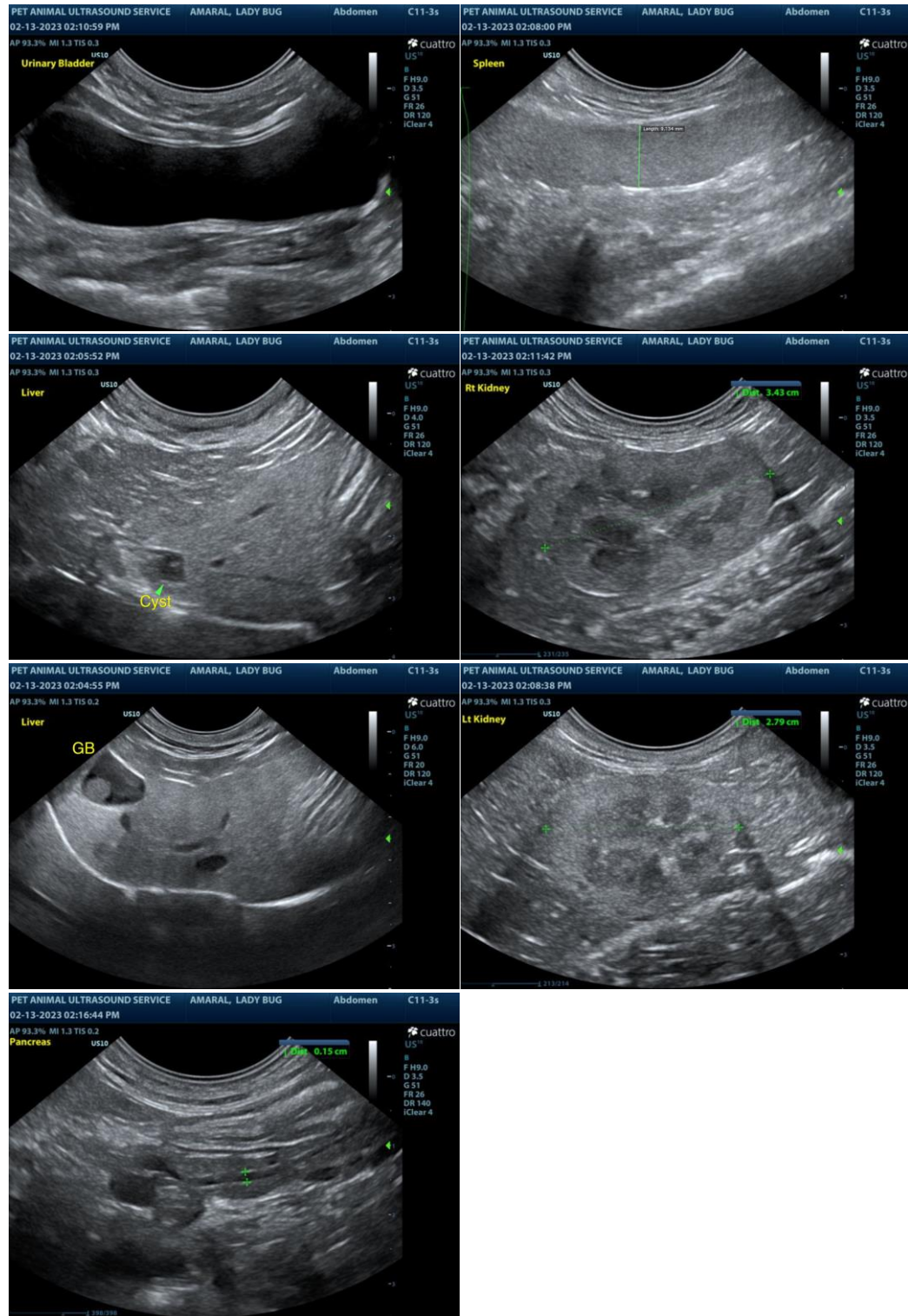
Dr. Oldham

INVOICE

12959ag

DATE

02/13/2023



The information and recommendations provided are based on the images presented by the referring veterinarian/sonographer. No evaluation can be communicated regarding pathology that was not visible in the image/video clips provided.

Thank you for this referral. If the clinical or image interpretation does not parallel your findings or if I



PATIENT

Lady Bug Amaral

can be of any further assistance please contact me.

R. McKenzie Daniel, DVM, DABVP (Canine / Feline Practice)

info@SonoPath.com

SPECIES

Feline

BREED

DLH

SEX

FS

AGE

20yr

WEIGHT

9lb

INTERPRETED BY

R. McKenzie Daniel, DVM,
DABVP (Canine and Feline)

**IMAGING
PERFORMED BY**

Pamela Harrigan, RDMS

HOSPITAL NAME

Mashpee Veterinary
Hospital

REFERRING VET

Dr. Oldham

INVOICE

12959ag

DATE

02/13/2023