



PATIENT

Bentley Conner

SPECIES

Canine

BREED

French Bulldog

SEX

Male

AGE

10

WEIGHT

15

INTERPRETED BY

R. McKenzie Daniel,
DVM, DABVP
(Canine and Feline)

IMAGING PERFORMED BY

Jenn

HOSPITAL NAME

Rockaway AH

REFERRING VET

Dr. Bednar

INVOICE

13334

DATE

2/12/22

PRESENTING CLINICAL SIGNS

Resp distress r/o cardiac vs lung pathology Current meds Lasix, Torb, Metro Unasyn
Abnormal PE/Chem/CBC/UA Results: increased TP ALT, Tbili

ULTRASONOGRAPHIC EXAMINATION OF THE HEART

CANINE CARDIAC PARAMETERS	MR VMAX (m/s)	TR VMAX (m/s)	LA/AO (Boon method)	LA/AO (Heart Base; Swe)	FS (%)	EF (%)	EPSS (cm)
NORMAL PARAMETER	4.5-5.5	<2.7	1.3	<1.6	28-40	40-100	<0.6
PATIENT			1.37	1.38	43	77.3	0.3
CANINE CARDIAC PARAMETERS	HR (BPM)	AV VMAX (m/s)	PV MAX (m/s)	BODY WEIGHT (kg)	LA 2D short axis Base view (cm)	LVIDd Avg; 2D and m-mode short axis (cm)	LVIDs Avg; 2D and m-mode short axis (cm)
NORMAL PARAMETER	50-100	0.7-1.7	0.7-1.6	BELOW	BELOW	BELOW	BELOW
PATIENT	233	0.8	1.0		2.6	2.4	

Cardiac Presentation

The echocardiogram in this patient demonstrated normal **left atrial** size and structure. Chamber volume and blood echogenicity were normal. The cranial and caudal **mitral** valve leaflets presented minor irregular age-related changes that are not clinically significant at this time with adequate extension in systole and union in diastole. The **left ventricle** presented normal free wall and septal thicknesses with linear contour. The **myocardium** presented some echogenic remodeling consistent with expected age-related change. **Contractility** of the ventricular walls was adequate and in normal range for this breed and patient size. The **left ventricular outflow** tract demonstrated normal laminar flow with subjectively unremarkable structure. Subjective assessment of the **right atrium** and auricle revealed normal size, structure and content. No evidence of masses was noted. **Tricuspid** valvular assessment demonstrated expected findings for this age patient. The **right ventricle** was of normal size (1/3 diameter of LV), echogenicity and thickness. **Pulmonic** tract assessment revealed normal valve structure, laminar flow, and diameter (approx. 1:1 pa/ao ratio). No dilation due to heartworm disease, cuor pulmonale, stenosis, or pulmonic hypertension was noted. No visible **pericardial** or free pleural fluid was noted. The **mediastinum** was free of masses in the visible window.

ULTRASONOGRAPHIC FINDINGS

- Overtly normal cardiac structure and function



PATIENT

Bentley Conner

SPECIES

Canine

BREED

French Bulldog

SEX

Male

AGE

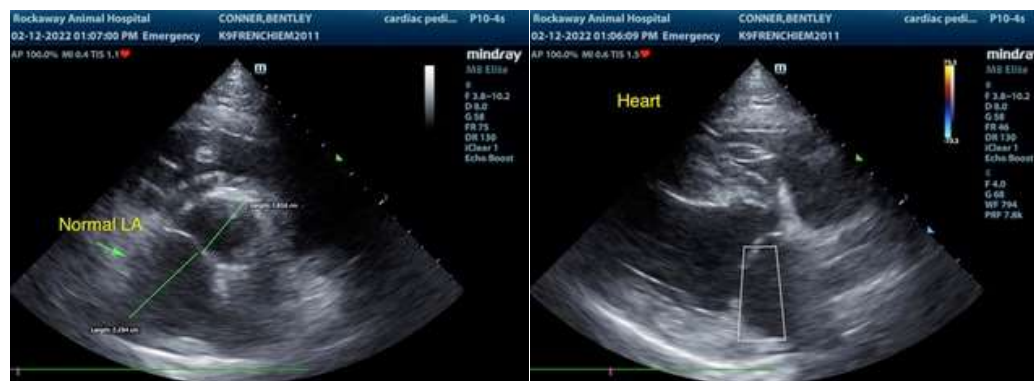
10

WEIGHT

15

INTERPRETATION OF THE FINDINGS & FURTHER RECOMMENDATIONS

No evidence of structural or functional cardiomyopathy including no evidence of LV systolic dysfunction, RA/RV enlargement, or overt evidence of clinical pulmonary hypertension. The cardiac presentation was not overtly consistent with underlying cardiac disease as a cause of respiratory signs in this patient and suggests a probable primary airway component to the respiratory distress. No indication for cardiac medications was evident. As-needed respiratory support is recommended.



INTERPRETED BY

R. McKenzie Daniel,
DVM, DABVP
(Canine and Feline)

IMAGING PERFORMED BY

Jenn

The information and recommendations provided are based on the images presented by the referring veterinarian/sonographer. No evaluation can be communicated regarding pathology that was not visible in the image/video clips provided.

Thank you for this referral. If the clinical or image interpretation does not parallel your findings or if I can be of any further assistance please contact me.

R. McKenzie Daniel, DVM, DABVP (Canine / Feline Practice)
info@SonoPath.com

HOSPITAL NAME

Rockaway AH

REFERRING VET

Dr. Bednar

INVOICE

13334

DATE

2/12/22