



PATIENT

Uzi Raeburn, Drew

SPECIES

Canine

BREED

Shepherd Mix

SEX

MN

AGE

3.5 years

WEIGHT

41.70 kg

INTERPRETED BY

R. McKenzie Daniel,
DVM, DABVP
(Canine and Feline)

IMAGING PERFORMED BY

Carlie Koltek, RVT

HOSPITAL NAME

Tuxedo AH

REFERRING VET

Dr. Mooi
(Centennial AH)

INVOICE

10628

DATE

2/11/26

PRESENTING CLINICAL SIGNS

History:

- AUS for staging purpose (dx with cutaneous mast cell tumor)
- Current meds: Meloxicam 7.5mg tablet - Give 1/2 SID

Abnormal PE/Chem/CBC/UA Results: CBC: RBC 8.5 5.8 - 8.5 x10¹²/L HgB 199 133 - 197 g/L Hct 0.59 0.39 - 0.56 L/L CHEM: ALT 16 U/L (19-107) Pending: FNA of spleen collected today - no prominent lymph nodes to sample

ULTRASONOGRAPHIC EXAMINATION OF THE ABDOMEN

Urinary System

The urinary bladder, trigone, cystourethral junction, and visible pelvic urethra to a depth of 3.0 cm exhibited normal thickness and tone. Anechoic urine was present in the lumen with no uroliths or sediment. The ureteral papillae were normal. The ureters were not visible which is normal. No evidence of inflammatory or neoplastic changes was noted.

The area of the residual prostate appeared normal and free of pathology

No evidence of pathology in the area of the aortic trifurcation.

Normal size and margination were present in the kidneys. A normal 1:3 cortex / medulla ratio and normal corticomedullary definition were maintained. The echogenicity of the cortex was similar to or slightly less than normal liver parenchyma while the medulla echogenicity was hypoechoic to the cortex with no evidence of pelvic dilation. The left kidney measured 6.8 cm in length. The right kidney measured 6.5 cm in length.

Adrenal Glands

The left adrenal gland was uniform in size and contour with a uniformly hypoechoic parenchyma. The left adrenal gland measured 0.55 cm width at the caudal pole. The right adrenal gland was uniform in size and contour with a uniformly hypoechoic parenchyma. The right adrenal gland measured 0.62 cm width at the caudal pole.

Spleen

The spleen exhibited a finely textured and homogenous parenchyma which was hyperechoic to the liver and renal cortical parenchyma. The capsule was smooth and regular without apparent expansion. The splenic vasculature at the hilus was normal in volume with no evidence of congestion or thrombosis. Acute to chronic inflammatory, neoplastic, or benign parenchyma changes were not noted.

Liver/Gallbladder

The liver was subjectively normal in size, structure, and contour. Normal hepatic vascular volume was present. The liver parenchyma was uniform and hypoechoic to the spleen with a mild coarse echotexture. The hepatic and portal vasculature were normal in appearance without signs of congestion. The gallbladder was non-distended in size with thin walls and primarily anechoic luminal content. The cystic and common bile ducts were normal.



PATIENT

Uzi Raeburn, Drew

SPECIES

Canine

BREED

Shepherd Mix

SEX

MN

AGE

3.5 years

WEIGHT

41.70 kg

INTERPRETED BY

R. McKenzie Daniel,
DVM, DABVP
(Canine and Feline)

IMAGING PERFORMED BY

Carlie Koltek, RVT

HOSPITAL NAME

Tuxedo AH

REFERRING VET

Dr. Mooi
(Centennial AH)

INVOICE

10628

DATE

2/11/26

Gastrointestinal

The stomach presented intact wall layering with a normal wall layer ratio. The lumen of the stomach was empty without evidence of retained ingesta, fluid, or foreign material.

The small intestine presented intact wall layering with 1:3 muscularis/mucosa ratio. The lumen of the small intestine was empty with no signs of ileus, obstruction, or foreign material.

Normal visible colon wall layers were present with formed feces in lumen.

Pancreas

The parenchyma of the left limb, body and right limb of the pancreas presented isoechoic to the adjacent omental fat. A normal curvilinear capsule contour of the pancreas was present. The visible pancreatic duct was normal. No signs of active inflammation or neoplastic disease were evident.

Free Abdomen

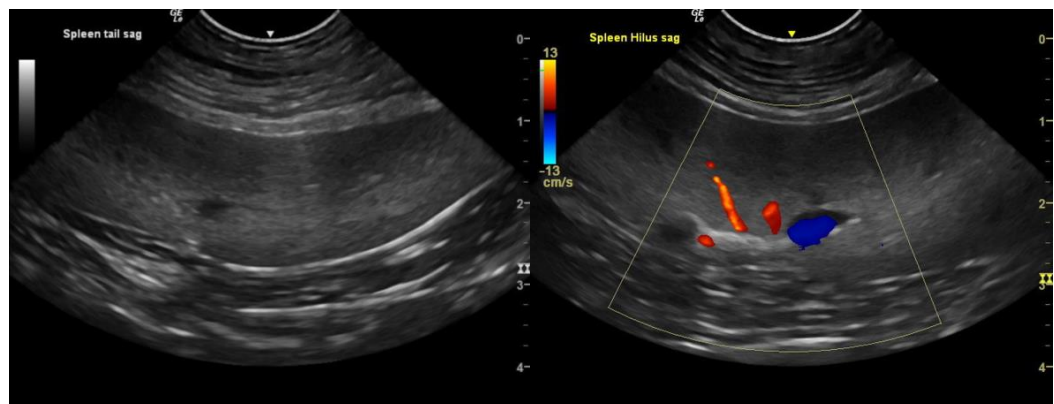
No overt lymphadenopathy or peritoneal effusion was present.

ULTRASONOGRAPHIC FINDINGS

- Sonographically normal abdomen

INTERPRETATION OF THE FINDINGS & FURTHER RECOMMENDATIONS

There is no sonographic evidence of intrabdominal or retroperitoneal primary or metastatic neoplastic criteria. Correlation with pending screening splenic FNA cytology is recommended with possible oncology consult and sonographic monitoring based on oncology recommendations.





PATIENT

Uzi Raeburn, Drew

SPECIES

Canine

BREED

Shepherd Mix

SEX

MN

AGE

3.5 years

WEIGHT

41.70 kg

INTERPRETED BY

R. McKenzie Daniel,
DVM, DABVP
(Canine and Feline)

IMAGING PERFORMED BY

Carlie Koltek, RVT

HOSPITAL NAME

Tuxedo AH

REFERRING VET

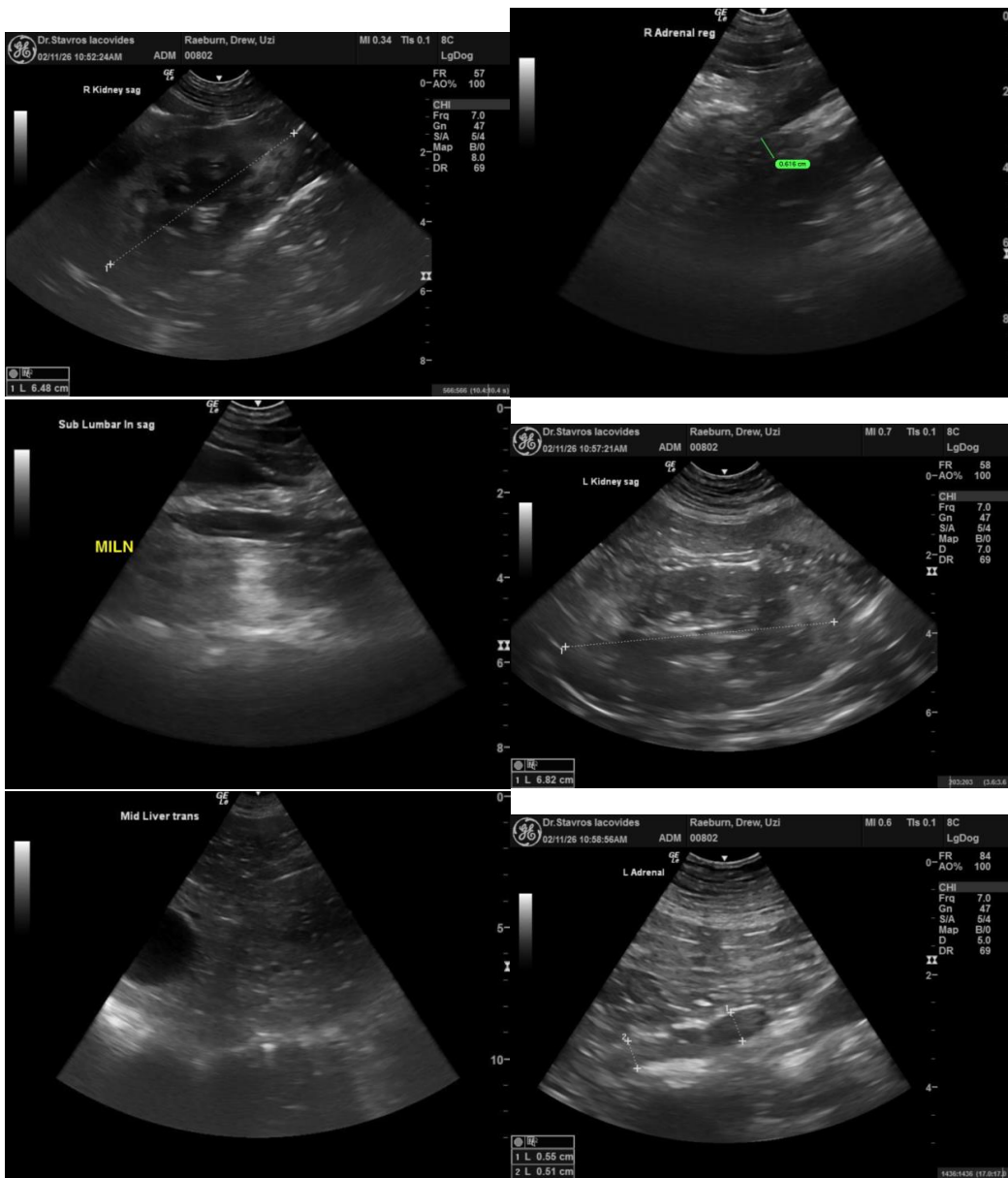
Dr. Mooi
(Centennial AH)

INVOICE

10628

DATE

2/11/26





PATIENT

Uzi Raeburn, Drew

SPECIES

Canine

BREED

Shepherd Mix

SEX

MN

AGE

3.5 years

WEIGHT

41.70 kg

INTERPRETED BY

R. McKenzie Daniel,
DVM, DABVP
(Canine and Feline)

IMAGING PERFORMED BY

Carlie Koltek, RVT

HOSPITAL NAME

Tuxedo AH

REFERRING VET

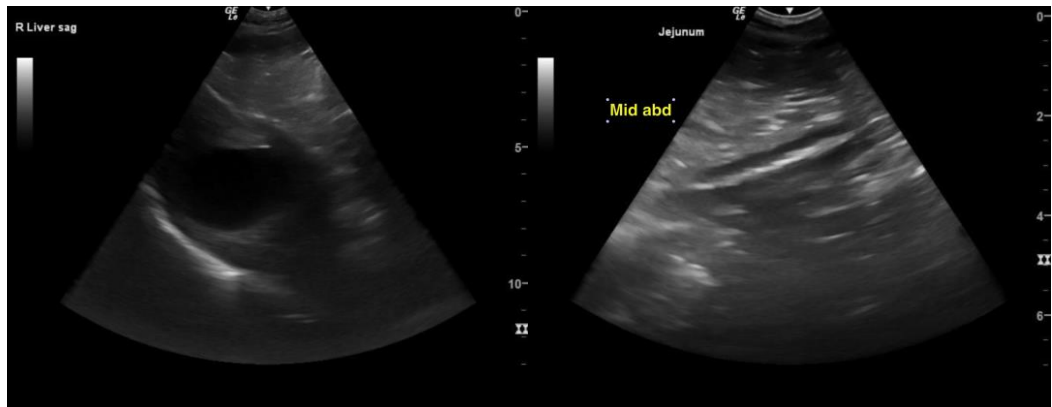
Dr. Mooi
(Centennial AH)

INVOICE

10628

DATE

2/11/26



The information and recommendations provided are based on the images presented by the referring veterinarian/sonographer. No evaluation can be communicated regarding pathology that was not visible in the image/video clips provided.

Thank you for this referral. If the clinical or image interpretation does not parallel your findings or if I can be of any further assistance, please contact me.

R. McKenzie Daniel, DVM, DABVP (Canine/Feline Practice)
info@sonopath.com