



PATIENT

Molly Graham,
Amanda

SPECIES

Canine

BREED

Sheepadoodle

SEX

FS

AGE

12 years

WEIGHT

26.7 kg

INTERPRETED BY

R. McKenzie Daniel,
DVM, DABVP
(Canine and Feline)

IMAGING PERFORMED BY

Carlie Koltek, RVT

HOSPITAL NAME

Tuxedo AH

REFERRING VET

Dr. Bongiorno

INVOICE

10626

DATE

2/11/26

PRESENTING CLINICAL SIGNS

History:

- AGASACA. Anal gland surgically removed end of November. No further treatments. Follow-up AUS to assess for any metastasis.
- Current meds: phenobarb, fluoxetine

Abnormal PE/Chem/CBC/UA Results: 3 view thoracic radiographs taken today

ULTRASONOGRAPHIC EXAMINATION OF THE ABDOMEN

Urinary System

The urinary bladder, trigone, cystourethral junction, and visible pelvic urethra to a depth of 3.0 cm exhibited normal thickness and tone. Anechoic urine was present in the lumen with no uroliths or sediment. The ureteral papillae were normal. The ureters were not visible which is normal. No evidence of inflammatory or neoplastic changes were noted.

No evidence of medial iliac or sublumbar lymphadenopathy/masses.

Normal size and margination were present in the kidneys. A normal 1:3 cortex / medulla ratio was maintained. The medulla and cortices were uniform in texture with some increased echogenicity and mild loss of corticomedullary symmetry and definition expected for the age of the patient. No evidence of pelvic dilation was present. The left kidney measured 6.1 cm in length. The right kidney measured 5.9 cm in length.

Adrenal Glands

The left adrenal gland was uniform in size and contour with a uniformly hypoechoic parenchyma. The left adrenal gland measured 0.48 cm width at the caudal pole. The right adrenal gland was uniform in size and contour with a uniformly hypoechoic parenchyma. The right adrenal gland measured 0.63 cm width at the caudal pole.

Spleen

The spleen exhibited a finely textured and homogenous parenchyma which was hyperechoic to the liver and renal cortical parenchyma. The splenic vasculature at the hilus was normal in volume with no evidence of congestion or thrombosis. Mild perihilar medial capsule asymmetrical contour, suspect emerging medial capsule fibrosis, and potential emerging perihilar myelolipomas were noted.

Liver/ Gallbladder

The liver was subjectively normal in size, structure, and contour. Normal hepatic vascular volume was present. The liver parenchyma was uniform and hypoechoic to the spleen with a mild coarse echotexture. The hepatic and portal vasculature were normal in appearance without signs of congestion. The gallbladder was non-distended in size with thin walls and primarily anechoic luminal content. The cystic and common bile ducts were normal.

Gastrointestinal

The stomach presented intact wall layering with a normal wall layer ratio. The lumen of the stomach was empty without evidence of retained ingesta, fluid, or foreign material.



PATIENT

Molly Graham,
Amanda

SPECIES

Canine

BREED

Sheepadoodle

SEX

FS

AGE

12 years

WEIGHT

26.7 kg

INTERPRETED BY

R. McKenzie Daniel,
DVM, DABVP
(Canine and Feline)

IMAGING PERFORMED BY

Carlie Koltek, RVT

HOSPITAL NAME

Tuxedo AH

REFERRING VET

Dr. Bongiorno

INVOICE

10626

DATE

2/11/26

The small intestine presented intact wall layering with 1:3 muscularis/mucosa ratio. The lumen of the small intestine was empty with no signs of ileus, obstruction, or foreign material.

Normal visible colon wall layers were present with formed feces in lumen.

Pancreas

The parenchyma of the left limb, body and right limb of the pancreas presented isoechoic to the adjacent omental fat. A normal curvilinear capsule contour of the pancreas was present. The visible pancreatic duct was normal. No signs of active inflammation or neoplastic disease was evident.

Free Abdomen

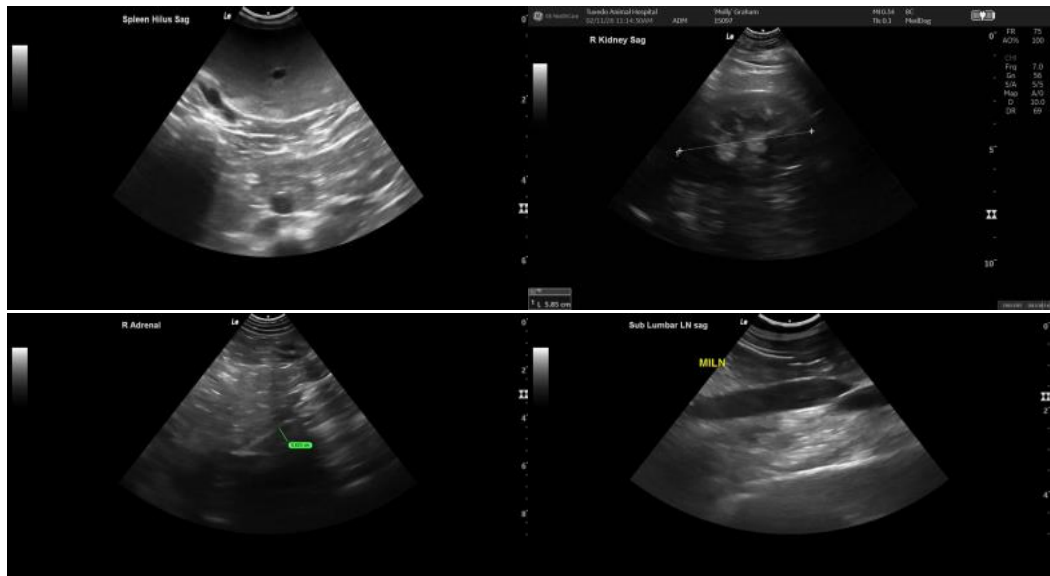
No overt lymphadenopathy or peritoneal effusion was present.

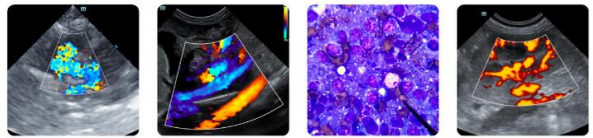
ULTRASONOGRAPHIC FINDINGS

- Mild age-related renal changes
- Mild benign splenic changes – perihilar medical capsule fibrosis and possible emerging myelolipomas probable

INTERPRETATION OF THE FINDINGS & FURTHER RECOMMENDATIONS

There is no evidence of intrabdominal or retroperitoneal primary or metastatic neoplastic criteria. Continued sonographic monitoring based on oncology recommendations is indicated.





PATIENT

Molly Graham,
Amanda

SPECIES

Canine

BREED

Sheepadoodle

SEX

FS

AGE

12 years

WEIGHT

26.7 kg

INTERPRETED BY

R. McKenzie Daniel,
DVM, DABVP
(Canine and Feline)

IMAGING PERFORMED BY

Carlie Koltek, RVT

HOSPITAL NAME

Tuxedo AH

REFERRING VET

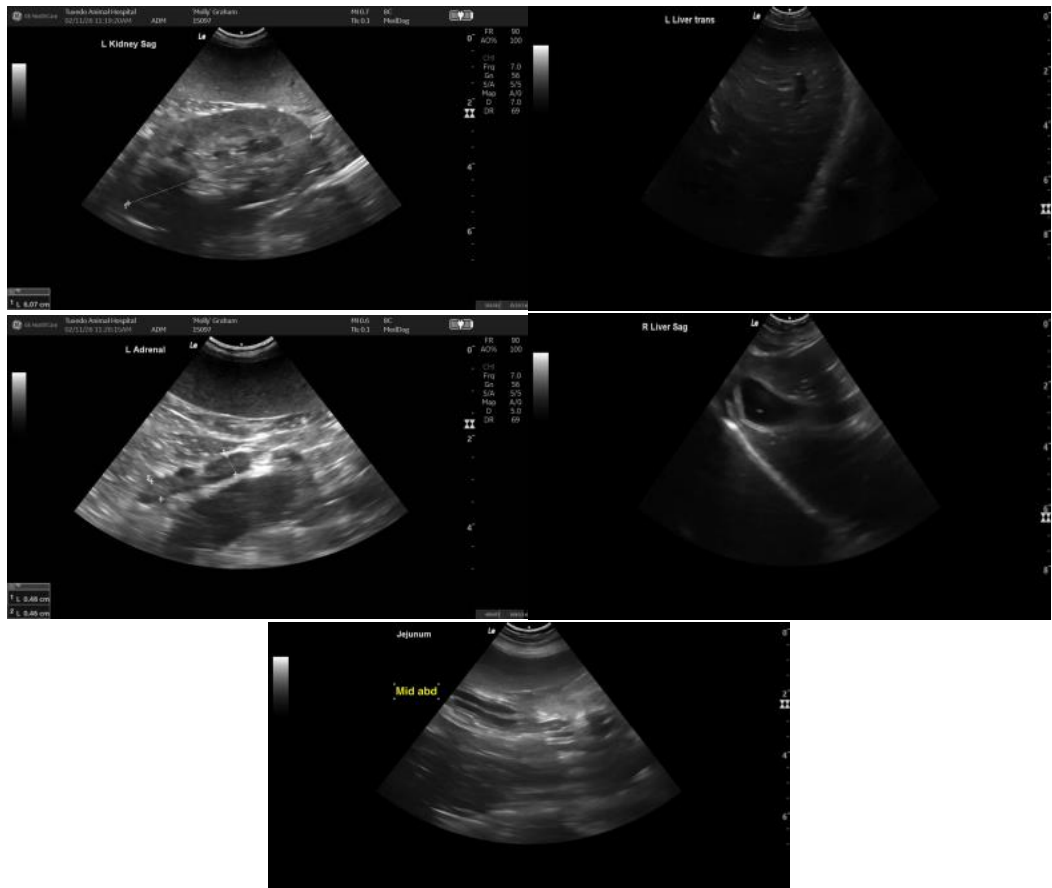
Dr. Bongiorno

INVOICE

10626

DATE

2/11/26



The information and recommendations provided are based on the images presented by the referring veterinarian/sonographer. No evaluation can be communicated regarding pathology that was not visible in the image/video clips provided.

Thank you for this referral. If the clinical or image interpretation does not parallel your findings or if I can be of any further assistance, please contact me.

R. McKenzie Daniel, DVM, DABVP (Canine/Feline Practice)
info@sonopath.com