



**PATIENT**

Tullulah Schneider

**SPECIES**

Canine

**BREED**

Sheltie

**SEX**

F/S

**AGE**

4 years

**WEIGHT**

24

**INTERPRETED BY**

R. McKenzie Daniel,  
DVM, DABVP  
(Canine and Feline)

**IMAGING PERFORMED BY**

Dr. Brita Kiffney

**HOSPITAL NAME**

Northshore VH

**REFERRING VET**

Dr. Brita Kiffney

**INVOICE**

16043

**DATE**

2/1/23

**PRESENTING CLINICAL SIGNS**

recurrent UTI's - and has a urolith in bladder. This was documented initially 12/22

Abnormal PE/Chem/CBC/UA Results: urine culture from 12/22 Status: Staphylococcus pseudintermedius- see attached sensitivity treated with doxycycline. The stone doesn't appear to have shrunk (on rads 12/22 was 1.2 cm , now is about the same

Total # of Files Uploaded: 1

**ULTRASONOGRAPHIC EXAMINATION OF THE URINARY SYSTEM**

**Urinary System**

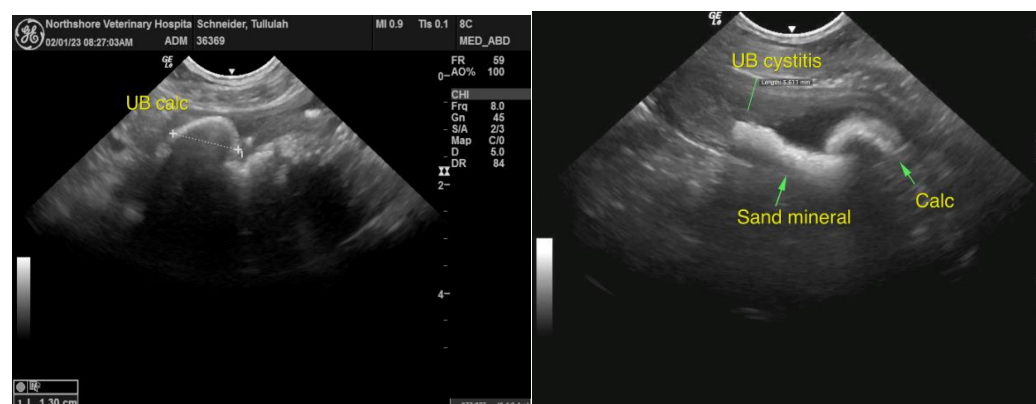
The urinary bladder was non-distended yet exhibited mild irregularly thickened ventroapical to dorsoapical urinary bladder wall with mild asymmetrical luminal surface contour. Potential for micropolypliod changes is noted. A solitary calculus measuring approximately 1.3 cm in diameter along with moderate dependent mineral / sand, and mild nondependent particulate sediment were present. No evidence of urinary bladder tumors was noted. The ventral urinary bladder wall width measured 0.56 cm width. The urethra exhibited normal structure and tone to a depth of 3.0 cm. No evidence of post urinary obstructive criteria was noted.

**ULTRASONOGRAPHIC FINDINGS**

- Cystitis with cystic calculus and moderate luminal mineral

**INTERPRETATION OF THE FINDINGS & FURTHER RECOMMENDATIONS**

Cystostomy with urinary bladder flush, as well as urinary bladder biopsies for histopathology with tissue C/S are warranted as the cystic calculus and concurrent moderate luminal mineral likely indicate nidus for recurrent infection. Potential for embedded mural infection could also be possible. No evidence of neoplastic criteria was noted.



The information and recommendations provided are based on the images presented by the referring veterinarian/sonographer. No evaluation can be communicated regarding pathology



**PATIENT**

Tullulah Schneider

**SPECIES**

Canine

**BREED**

Sheltie

**SEX**

F/S

**AGE**

4 years

**WEIGHT**

24

**INTERPRETED BY**

R. McKenzie Daniel,  
DVM, DABVP  
(Canine and Feline)

**IMAGING  
PERFORMED BY**

Dr. Brita Kiffney

**HOSPITAL NAME**

Northshore VH

**REFERRING VET**

Dr. Brita Kiffney

**INVOICE**

16043

**DATE**

2/1/23

**that was not visible in the image/video clips provided.**

Thank you for this referral. If the clinical or image interpretation does not parallel your findings or if I can be of any further assistance please contact me.

**R. McKenzie Daniel, DVM, DABVP (Canine / Feline Practice)**  
**info@SonoPath.com**