



PATIENT

Sasha Tyler

SPECIES

Feline

BREED

DMH

SEX

FS

AGE

17yr

WEIGHT

7.6lb

INTERPRETED BY

R. McKenzie Daniel,
DVM, DABVP
(Canine and Feline)

IMAGING PERFORMED BY

Christina Wagner

HOSPITAL NAME

Angeles Clinic for
Animals

REFERRING VET

Christina Wagner

INVOICE
23204

DATE
12/9/2025

PRESENTING CLINICAL SIGNS

Owner reports smaller urine clumps in litter box and some vocalizing after leaving litter box in recent weeks. When I went to perform an ultrasound guided cysto, saw bladder wall changes - mass?

Abnormal PE/Chem/CBC/UA Results: UA - USG 1.024, 2+ blood, increased epithelial cells (voided sample/table top collection).

LIMITED ULTRASONOGRAPHIC EXAMINATION OF THE URINARY BLADDER

The submitted study contained five videos of the urinary bladder only.

The urinary bladder was normal in size and tone. An irregular mural mass lesion was present in the area of the ventroapical to apical urinary bladder wall exhibiting asymmetrical luminal surface contour and evidence of adhered to mural mineralization. The mass lesion measured ~ 2.0 by 1 by 1.3 cm.

No evidence of obstruction to urine outflow with anechoic urine present. The visualized urethra was normal in structure, tone and depth to 2 cm.

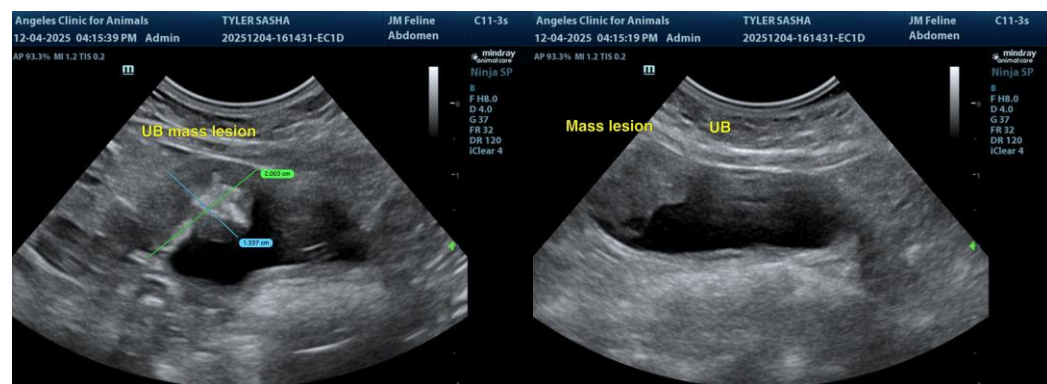
ULTRASONOGRAPHIC FINDINGS

Primary

- Apical urinary bladder mass lesion with evidence of adhered to mural mineralization.

INTERPRETATION OF THE FINDINGS & FURTHER RECOMMENDATIONS

The urinary bladder mass lesion is highly suggestive of neoplastic criteria given evidence of mural mineralization, i.e. transitional cell carcinoma. Chronic cystitis and adhered lumen surface mineral thought less likely given evidence of progression compared to the previous study. Correlation with cytospin cytology, a free catch urine sample to assess for neoplastic transitional cells +/- urine C/S is recommended.



The information and recommendations provided are based on the images presented by the referring veterinarian/sonographer. No evaluation can be communicated regarding pathology that was not visible in the image/video clips provided.



PATIENT

Sasha Tyler

Thank you for this referral. If the clinical or image interpretation does not parallel your findings or if I can be of any further assistance, please contact me.

SPECIES

Feline

R. McKenzie Daniel, DVM, DABVP (Canine/Feline Practice)

info@sonopath.com

BREED

DMH

SEX

FS

AGE

17yr

WEIGHT

7.6lb

INTERPRETED BY

R. McKenzie Daniel,
DVM, DABVP
(Canine and Feline)

**IMAGING
PERFORMED BY**

Christina Wagner

HOSPITAL NAME

Angeles Clinic for
Animals

REFERRING VET

Christina Wagner

**INVOICE
23204**

DATE
12/9/2025