

PATIENT

Nova Doherty

SPECIES

Canine

BREED

Mixed

SEX

FS

AGE

10 yrs

WEIGHT

~50 lbs.

INTERPRETED BY

R. McKenzie Daniel,
DVM, DABVP
(Canine and Feline)

IMAGING PERFORMED BY

Sara Hansen

HOSPITAL NAME

West Hills AH

REFERRING VET

Dr. Remcho

INVOICE

10436

DATE

12/9/25

PRESENTING CLINICAL SIGNS

Presentation and clinical exam findings: Elevated proBNP found on routine labwork. 4/6 murmur appreciated on exam today Altered labwork values: ProBNP 1723

Radiograph findings: Rads done 12/24 showed thorax WNL

ULTRASONOGRAPHIC EXAMINATION OF THE HEART

CANINE CARDIAC PARAMETERS	MR VMAX (m/s)	TR VMAX (m/s)	LA/AO (M-Mode)	LA/AO (Heart Base; Swe)	FS (%)	EF (%)	EPSS (cm)
NORMAL PARAMETER	4.5-5.5	<2.7	1.3	Up to 1.6	28-40	40-100	<0.6
PATIENT	5.5			1.25	47	78	0.2
CANINE CARDIAC PARAMETERS	HR (BPM)	AV VMAX (m/s)	PV MAX (m/s)	BODY WEIGHT (kg)	LAD LA MAX 4 Chamber	LVIDd Avg; 2D and m-mode short axis (cm)	LVIDs Avg; 2D and m-mode short axis (cm)
NORMAL PARAMETER	50-100	0.7-1.7	0.7-1.6				
PATIENT	NM	1.6	1.3		4.1	3.7	

Cardiac Presentation

The echocardiogram in this patient demonstrated normal **left atrial** size based on 2 different LA measurement methods. Chamber volumes and echogenicity were normal. The cranial and caudal **mitral** valve leaflets presented mild thickening consistent with mild endocardiosis with no valvular prolapse. Doppler indicated mild eccentric MR (MR velocity 5.5 m/s). The **left ventricle** presented thicknesses with linear contour and was not dilated nor restricted. The **myocardium** presented normal echogenicity without subjective evidence of significant fibrotic or ischemic disease. **Contractility** of the ventricular walls was adequate and in normal range for this patient evidenced by the fractional shortening measurement and subjective evaluation of the different regions of the myocardium. The **left ventricular outflow** tract demonstrated normal laminar flow and subjective structural integrity. The **right atrium** and auricle revealed normal size, structure and content. No evidence of masses was noted or chamber overload. **Tricuspid** valvular assessment demonstrated adequate linear morphology. The **right ventricle** was of normal size (1/3 diameter of LV), chordae structure, myocardial echogenicity and thickness. **Pulmonic** tract assessment revealed normal valve structure, laminar flow, and diameter (approx. 1:1 pa/ao ratio). No visible **pericardial** or free pleura fluid was noted. No echographically detectable evidence of cardiac / pericardial tumors was visible.



PATIENT

Nova Doherty

SPECIES

Canine

BREED

Mixed

SEX

FS

AGE

10 yrs

WEIGHT

~50 lbs.

INTERPRETED BY

R. McKenzie Daniel,
 DVM, DABVP
 (Canine and Feline)

IMAGING PERFORMED BY

Sara Hansen

HOSPITAL NAME

West Hills AH

REFERRING VET

Dr. Remcho

INVOICE

10436

DATE

12/9/25

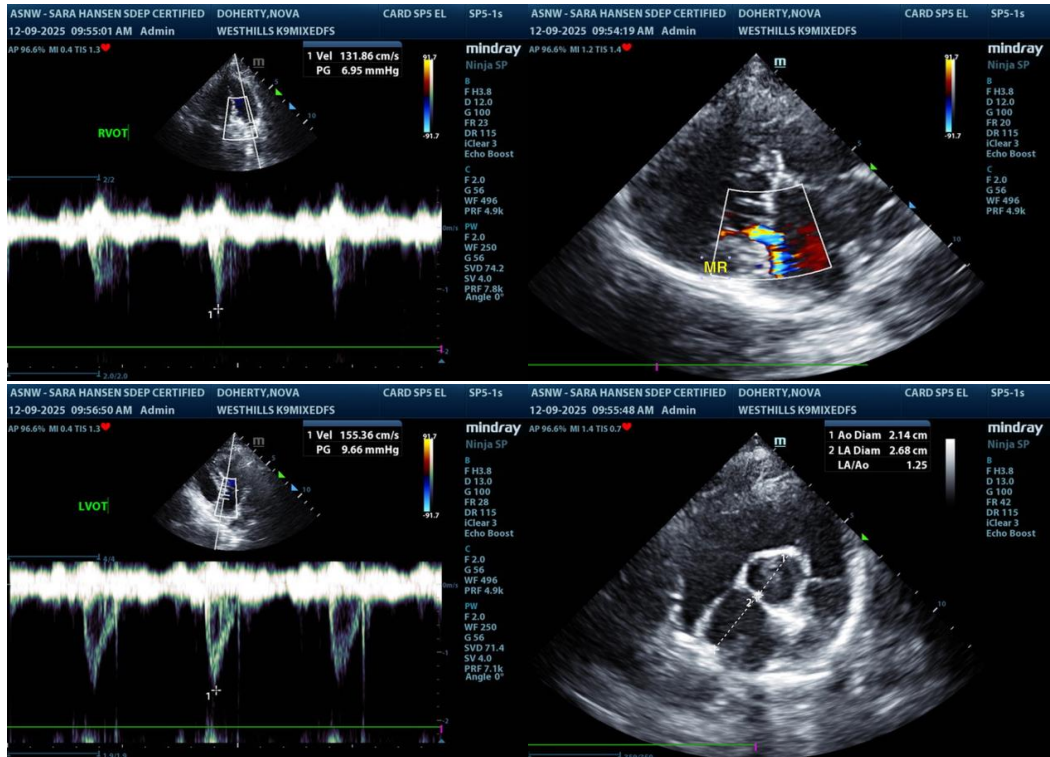
ULTRASONOGRAPHIC FINDINGS

- Chronic mitral valve disease (B1)

INTERPRETATION OF THE FINDINGS & FURTHER RECOMMENDATIONS

The cause of the murmur is chronic degenerative valvular changes with secondary eccentric mitral valve insufficiency. The lack of left atrial enlargement implies that the risk of complications secondary to mitral valve insufficiency is low at this time and, without current clinical signs, indicates that medical therapy is not required. Prognosis is considered variable and sonographic monitoring is recommended. Recheck echocardiogram is suggested in 6-12 months, sooner if clinical signs arise. There are no anesthetic contraindications if anesthesia is required.

Suggested anesthetic protocol may include opioid or Benzodiazepine pre-med, induction with Propofol or Alfaxalone, and appropriate gas anesthesia with avoidance of alpha 2 agonists.





PATIENT

Nova Doherty

SPECIES

Canine

BREED

Mixed

SEX

FS

AGE

10 yrs

WEIGHT

~50 lbs.

INTERPRETED BY

R. McKenzie Daniel,
DVM, DABVP
(Canine and Feline)

IMAGING PERFORMED BY

Sara Hansen

HOSPITAL NAME

West Hills AH

REFERRING VET

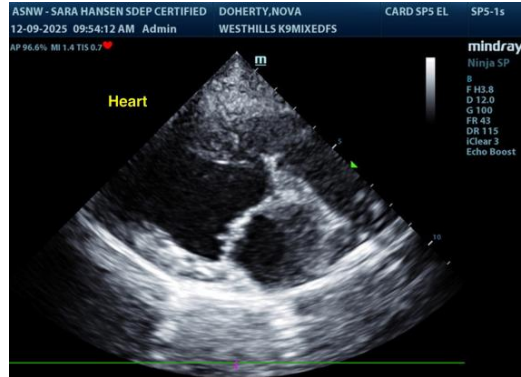
Dr. Remcho

INVOICE

10436

DATE

12/9/25



The information and recommendations provided are based on the images presented by the referring veterinarian/sonographer. No evaluation can be communicated regarding pathology that was not visible in the image/video clips provided.

Thank you for this referral. If the clinical or image interpretation does not parallel your findings or if I can be of any further assistance, please contact me.

R. McKenzie Daniel, DVM, DABVP (Canine/Feline Practice)
info@sonopath.com