



PATIENT

Maya Intorrella

SPECIES

Canine

BREED

Chihuahua

SEX

Female Spayed

AGE

9y 6m

WEIGHT

Pending

INTERPRETED BY

R. McKenzie Daniel,
DVM, DABVP
(Canine and Feline)

IMAGING PERFORMED BY

Shari Reffi, CVT

HOSPITAL NAME

Midland Park Vet Hosp

REFERRING VET

Dr. Shokoff

INVOICE

12896

DATE

12/9/25

PRESENTING CLINICAL SIGNS

History: Heart murmur, mid abd mass. Occ. cough. Radiographs revealed cardiomegaly, hepatomegaly and mid-abd mass (spleen vs liver?).

Meds: No current medications.

Abnormal PE/Chem/CBC/UA Results: Trig 341; PLT 479k

ULTRASONOGRAPHIC EXAMINATION OF THE HEART

CANINE CARDIAC PARAMETERS	MR VMAX (m/s)	TR VMAX (m/s)	LA/AO (M-Mode)	LA/AO (Heart Base; Swe)	FS (%)	EF (%)	EPSS (cm)
NORMAL PARAMETER	4.5-5.5	<2.7	1.3	Up to 1.6	28-40	40-100	<0.6
PATIENT	5.1	2.0	--	1.7	50	82	0.3
CANINE CARDIAC PARAMETERS	HR (BPM)	AV VMAX (m/s)	PV MAX (m/s)	BODY WEIGHT (kg)	LAD LA MAX 4 Chamber	LVIDd Avg; 2D and m-mode short axis (cm)	LVIDs Avg; 2D and m-mode short axis (cm)
NORMAL PARAMETER	50-100	0.7-1.7	0.7-1.6				
PATIENT	NM	1.1	0.7	--	2.9	2.6	--

Cardiac Presentation

The echocardiogram in this patient demonstrated moderate increased **left atrial** size with mild intra atrial septal deviation based on 2 different LA measurement methods. The cranial and caudal **mitral** valve leaflets presented thickening with mild valve prolapse. Moderate to significant eccentric MR velocity measuring 5.1 m/s. The **left ventricle** presented mild increased internal dimension. The **myocardium** presented normal echogenicity without subjective evidence of significant fibrotic or ischemic disease. **Contractility** of the ventricular walls was adequate and in normal range for this patient evidenced by the fractional shortening measurement and subjective evaluation of the different regions of the myocardium. The **left ventricular outflow** tract demonstrated normal laminar flow and subjective structural integrity. The **right atrium** and auricle revealed normal size, structure and content. No evidence of masses was noted or chamber overload. **Tricuspid** valvular assessment demonstrated mild thickening with mild TR noted on doppler. TR velocity measured 2.0 m/s. The **right ventricle** was of normal size (1/3 diameter of LV), chordae structure, myocardial echogenicity and thickness. **Pulmonic** tract assessment revealed normal valve structure, laminar flow, and diameter (approx.1:1 pa/ao ratio). No visible **pericardial** or free pleura fluid was noted. No echographically detectable evidence of cardiac / pericardial tumors was visible.



PATIENT

Maya Intorrella

SPECIES

Canine

BREED

Chihuahua

SEX

Female Spayed

AGE

9y 6m

WEIGHT

Pending

INTERPRETED BY

R. McKenzie Daniel,
 DVM, DABVP
 (Canine and Feline)

IMAGING PERFORMED BY

Shari Reffi, CVT

HOSPITAL NAME

Midland Park Vet Hosp

REFERRING VET

Dr. Shokoff

INVOICE

12896

DATE

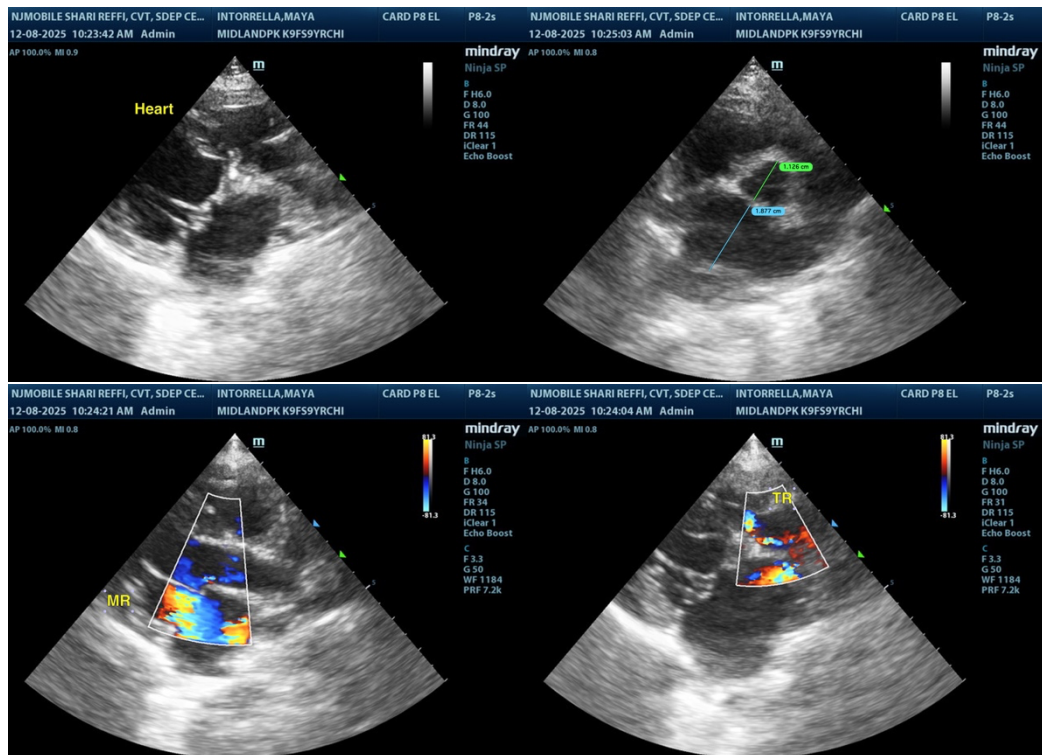
12/9/25

ULTRASONOGRAPHIC FINDINGS

- Chronic mitral valve disease (B2)

INTERPRETATION OF THE FINDINGS & FURTHER RECOMMENDATIONS

The cause of the murmur is chronic degenerative valvular changes with secondary eccentric mitral valve insufficiency. The left atrial enlargement implies that the risk of complication secondary to mitral valve insufficiency is elevated, yet overall, the heart appears stable. No other clinical issues such as LV systolic dysfunction or clinical pulmonary hypertension. Pimobendan 0.3 mg/kg BID is recommended. No overt indication for additional medication. Prognosis is considered variable and sonographic monitoring is recommended. Recheck echo cardiogram is suggested in 6 months, sooner if clinical signs arise. Anesthetic risk is considered moderately elevated yet likely mildly reduced once on Pimobendan for 3-5 days. If required, the following protocol is suggested with judicious IV fluid administration. Suggested anesthetic protocol may include opioid or Benzodiazepine pre-med, induction with Propofol or Alfaxalone, and appropriate gas anesthesia with avoidance of alpha 2 agonists.





PATIENT

Maya Intorrella

SPECIES

Canine

BREED

Chihuahua

SEX

Female Spayed

AGE

9y 6m

WEIGHT

Pending

INTERPRETED BY

R. McKenzie Daniel,
DVM, DABVP
(Canine and Feline)

**IMAGING
PERFORMED BY**

Shari Reffi, CVT

HOSPITAL NAME

Midland Park Vet Hosp

REFERRING VET

Dr. Shokoff

INVOICE

12896

DATE

12/9/25

The information and recommendations provided are based on the images presented by the referring veterinarian/sonographer. No evaluation can be communicated regarding pathology that was not visible in the image/video clips provided.

Thank you for this referral. If the clinical or image interpretation does not parallel your findings or if I can be of any further assistance, please contact me.

R. McKenzie Daniel, DVM, DABVP (Canine / Feline Practice)

info@sonopath.com