



PATIENT

Jackson Carpenter

SPECIES

Canine

BREED

Labrador Retriever

SEX

MN

AGE

8 years

WEIGHT

96.2 lbs.

INTERPRETED BY

R. McKenzie Daniel, DVM,
DABVP (Canine and
Feline)

IMAGING

PERFORMED BY

Pamela Harrigan, RDCS

HOSPITAL NAME

Anchor AH

REFERRING VET

Kristen Lavin, DVM

INVOICE

12787

DATE

12/9/21

PRESENTING CLINICAL SIGNS

Previously removed mast cell tumor with rough recovery. Two new lumps presents as MCTs on cytology. Ultrasound recommended for staging/met check. No current medications as patient was not tolerating pred and benadryl

Urinary System

The urinary bladder, trigone, cystourethral junction, and visible pelvic urethra to a depth of 5.0 cm exhibited normal thickness and tone. Anechoic urine was present in the lumen with no uroliths or sediment. The ureteral papillae were normal. The ureters were not visible which is normal. No evidence of inflammatory or neoplastic changes was noted.

The residual prostate was symmetrically normal in size with uniform parenchyma and slight coarse echotexture measuring 0.89 cm in diameter.

The area of the aortic trifurcation was free of pathology.

Normal size and margination were present in the kidneys. A normal 1:3 cortex / medulla ratio and normal corticomedullary definition were maintained. The echogenicity of the cortex was similar to or slightly less than normal liver parenchyma while the medulla echogenicity was hypoechoic to the cortex with no evidence of pelvic dilation. The left kidney measured 5.9 cm in length. The right kidney measured 6.6 cm in length.

Adrenal Glands

The left adrenal gland was uniform in size and contour with a uniformly hypoechoic parenchyma. The left adrenal gland measured 0.61 cm width at the caudal pole and 0.43 cm width at the cranial pole. The right adrenal gland was uniform in size and contour with a uniformly hypoechoic parenchyma. The right adrenal gland measured 0.59 cm width at the caudal pole and 0.63 cm width at the cranial pole.

Spleen

The spleen exhibited a finely textured and homogenous parenchyma which was hyperechoic to the liver and renal cortical parenchyma. The capsule was smooth and regular without apparent expansion. The splenic vasculature at the hilus was normal in volume with no evidence of congestion or thrombosis. Acute to chronic inflammatory, neoplastic, or benign parenchyma changes were not noted.

Liver/ Gallbladder

The liver was subjectively normal in size, structure, and contour. The liver parenchyma was uniform and hypoechoic to the spleen with a mild coarse echotexture. The hepatic and portal vasculature were normal in appearance without signs of congestion. The gallbladder was non-distended in size with thin walls and primarily anechoic luminal content. The cystic and common bile ducts were normal.

Gastrointestinal

The stomach presented intact wall layering with a normal wall layer ratio. The lumen of the stomach was empty with no signs of ileus, obstruction, or foreign material.



PATIENT

Jackson Carpenter

The small intestine presented intact wall layering with 1:3 muscularis/mucosa ratio. The lumen of the small intestine was empty with no signs of ileus, obstruction, or foreign material.

Normal visible colon wall layers were present with apparent formed feces in lumen.

SPECIES

Canine

Pancreas

The parenchyma of the left limb, body, and right limb of the pancreas presented isoechoic to the adjacent omental fat. A normal curvilinear capsule contour of the pancreas was present. The visible pancreatic duct was normal. No signs of active inflammation or neoplastic disease were evident.

BREED

Labrador Retriever

Free Abdomen

No overt lymphadenopathy or peritoneal effusion was present.

SEX

MN

ULTRASONOGRAPHIC FINDINGS

Primary Findings

- Sonographically unremarkable abdomen

AGE

8 years

INTERPRETATION OF THE FINDINGS & FURTHER RECOMMENDATIONS

No evidence of visceral pathology, specifically no evidence of intraabdominal metastasis from cutaneous mast cell tumor. Screening splenic or hepatosplenic FNA, assuming normal clotting status, could be considered if recommended by an oncologist. Otherwise, sonographic monitoring of the abdomen based on oncology recommendations is suggested.

WEIGHT

96.2 lbs.

INTERPRETED BY

R. McKenzie Daniel, DVM,
 DABVP (Canine and
 Feline)

IMAGING

PERFORMED BY

Pamela Harrigan, RDCS

HOSPITAL NAME

Anchor AH

REFERRING VET

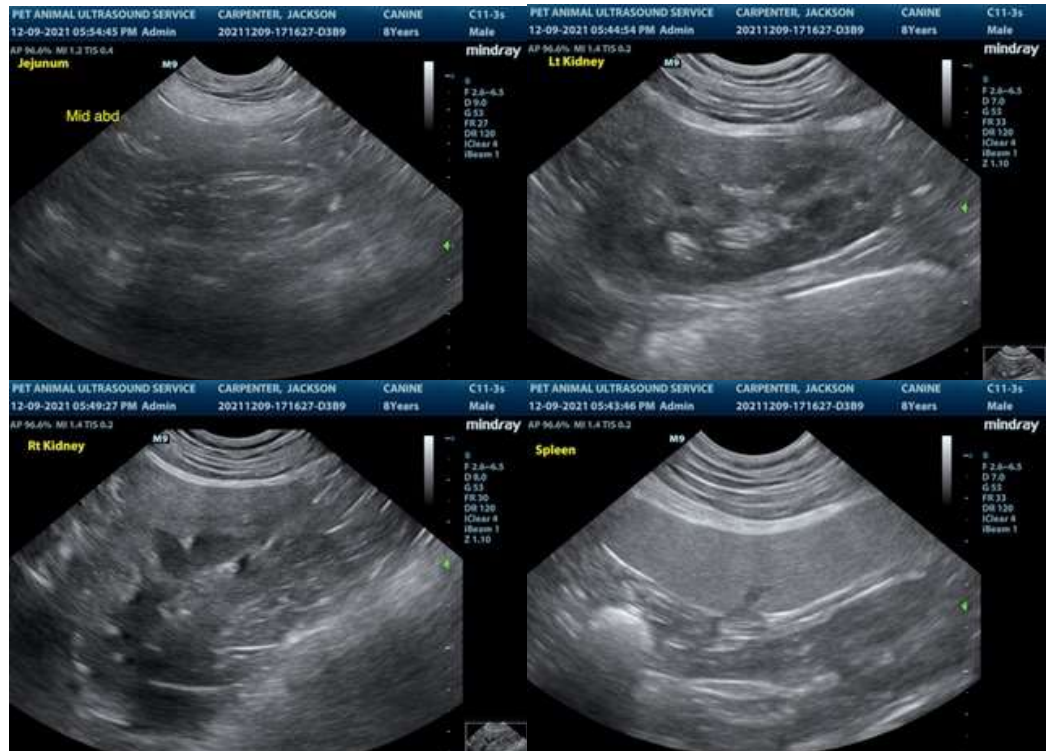
Kristen Lavin, DVM

INVOICE

12787

DATE

12/9/21





PATIENT

Jackson Carpenter

SPECIES

Canine

BREED

Labrador Retriever

SEX

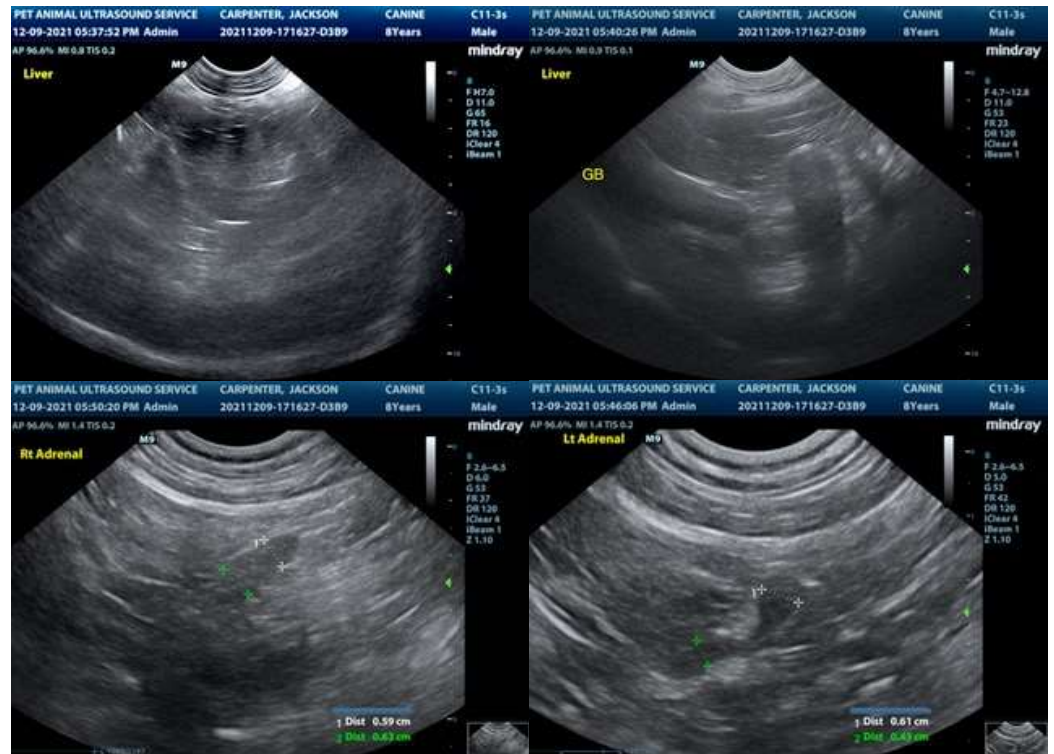
MN

AGE

8 years

WEIGHT

96.2 lbs.



INTERPRETED BY

R. McKenzie Daniel, DVM,
 DABVP (Canine and Feline)

IMAGING PERFORMED BY

Pamela Harrigan, RDCS

HOSPITAL NAME

Anchor AH

REFERRING VET

Kristen Lavin, DVM

INVOICE

12787

DATE

12/9/21

The information and recommendations provided are based on the images presented by the referring veterinarian. No evaluation can be communicated regarding pathology that was not visible in the image/video clips provided.

Thank you for this referral. If the clinical or image interpretation does not parallel your findings or if I can be of any further assistance please contact me.

R. McKenzie Daniel, DVM, DABVP (Canine / Feline Practice)
info@SonoPath.com