



## PATIENT

Sophie Mott

## SPECIES

Canine

## BREED

Sheltie

## SEX

Spayed Female

## AGE

14 Years

## WEIGHT

27

## INTERPRETED BY

R. McKenzie Daniel,  
DVM, DABVP

## IMAGING PERFORMED BY

Marco Litchfield

## HOSPITAL NAME

Sova Animal Hospital

## REFERRING VET

Dr. Ammeraal

## INVOICE

12628

## DATE

12/08/25

## PRESENTING CLINICAL SIGNS

Pet has a history of enlarged adrenal gland on left side, Large gallbladder debris.

Abnormal PE/Chem/CBC/UA Results: U pro/crea 6.2, ALKP 1631, ALT 796, AST 71, BUN/CREA 42, CHOL 566, GGT 13, B/C ratio 38, NEUT 78% blood was drawn 11/3/25, ALT and ALKP ran in house today ALT 222, ALKP 1262.

## ULTRASONOGRAPHIC EXAMINATION OF THE ABDOMEN

### Urinary System

The urinary bladder, trigone, cystourethral junction, and visible pelvic urethra to a depth of 2.0 cm exhibited normal thickness and tone. Anechoic urine was present in the lumen with no uroliths, urine mineral, calculi or sediment. The ureteral papillae were normal. The ureters were not visible which is normal. No evidence of inflammatory or neoplastic change were noted.

Normal size and margination was present in the kidneys. A normal 1:3 cortex / medulla ratio was maintained. The medulla and cortices were uniform in texture with some increased echogenicity and mild to moderate indistinct corticomedullary border demarcation expected for the age of the patient. No evidence of pelvic dilation was present. The left kidney measured 5.0 cm in length. The right kidney measured 5.0 cm in length.

### Adrenal Glands

The left adrenal gland was enlarged in size exhibiting nonhomogenous nonmineralized parenchyma. The left adrenal gland measured approximately 2.2 cm in diameter.

The right adrenal gland was indistinctly visualized exhibiting subjective age-related changes with no obvious pathology. The right adrenal gland subjectively measured 0.62 cm width at the caudal pole.

### Spleen

The spleen exhibited a finely textured and homogenous parenchyma which was hyperechoic to the liver and renal cortical parenchyma. The capsule was smooth and regular without apparent expansion. The splenic vasculature at the hilus was normal in volume with no evidence of congestion or thrombosis. Acute to chronic inflammatory, neoplastic, or benign parenchyma changes were not noted.

### Liver

The liver revealed generalized hepatomegaly with primarily symmetrical capsule contour and nonhomogenous parenchyma with parenchymal remodeling and mild variable coarse echotexture.

The gallbladder was distended in size with echogenic thickening of the gallbladder wall. There was biliary sludge that appeared to be non-mobile and organized. A stellate pattern to the organized biliary sludge was present. No evidence of wall inflammation or edema. The common bile duct was not visualized.

### Gastrointestinal

The stomach presented intact wall layering with a normal wall layer ratio. The lumen of the stomach was empty with no signs of ileus, obstruction or foreign material.



## PATIENT

Sophie Mott

The small intestine presented intact wall layering with 1:3 muscularis/mucosa ratio. The lumen of the small intestine was empty with no signs of ileus, obstruction or foreign material.

## SPECIES

Canine

Normal visible colon wall layers were present with apparent formed feces in lumen.

## BREED

Sheltie

## Pancreas

The parenchyma of the left limb, body and right limb of the pancreas presented isoechoic to the adjacent omental fat. A normal curvilinear capsule contour of the pancreas was present. The visible pancreatic duct was normal. No signs of active inflammation or neoplastic disease was evident.

## SEX

Spayed Female

## Free Abdomen

No overt lymphadenopathy or peritoneal effusion was present.

## AGE

14 Years

## ULTRASONOGRAPHIC FINDINGS

- Enlarged nonhomogenous left adrenal gland- hyperplasia, functional versus nonfunctional adenoma, tumor possible.
- Enlarged mild nonhomogenous liver- chronic vacuolar hepatopathy, inflammatory/immune mediated disease, hyperplasia, fibrosis, nonobstructive cholestasis, infiltrative neoplasia (less likely) or combination possible.
- Immature gallbladder mucocele.
- Mild chronic renal changes.

## WEIGHT

27

## INTERPRETATION OF THE FINDINGS & FURTHER RECOMMENDATIONS

## INTERPRETED BY

R. McKenzie Daniel,  
DVM, DABVP

Adrenal work up with LDDST if clinical signs are consistent with Cushing's syndrome as well as serial monitoring of systemic BP for evidence of hypertension +/- urine metanephrine level if hypertension is recommended. Hepatic FNA cytology (assuming normal clotting status) could be considered for further clarification. Empirical therapy for protein losing nephropathy is indicated if persistent or progressive elevated UPC and if systemic hypertension. Sonographic monitoring of the liver, gallbladder and left adrenal gland for evidence of progression is indicated assuming advanced imaging or potential surgery is not a potential.

## IMAGING PERFORMED BY

Marco Litchfield

## HOSPITAL NAME

Sova Animal Hospital

## REFERRING VET

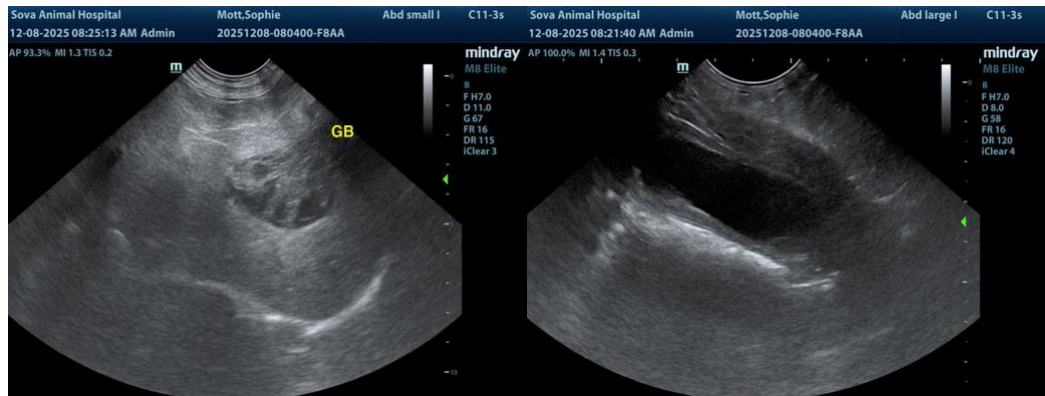
Dr. Ammeraal

## INVOICE

12628

## DATE

12/08/25





**PATIENT**

Sophie Mott

**SPECIES**

Canine

**BREED**

Sheltie

**SEX**

Spayed Female

**AGE**

14 Years

**WEIGHT**

27

**INTERPRETED BY**

R. McKenzie Daniel,  
DVM, DABVP

**IMAGING PERFORMED BY**

Marco Litchfield

**HOSPITAL NAME**

Sova Animal Hospital

**REFERRING VET**

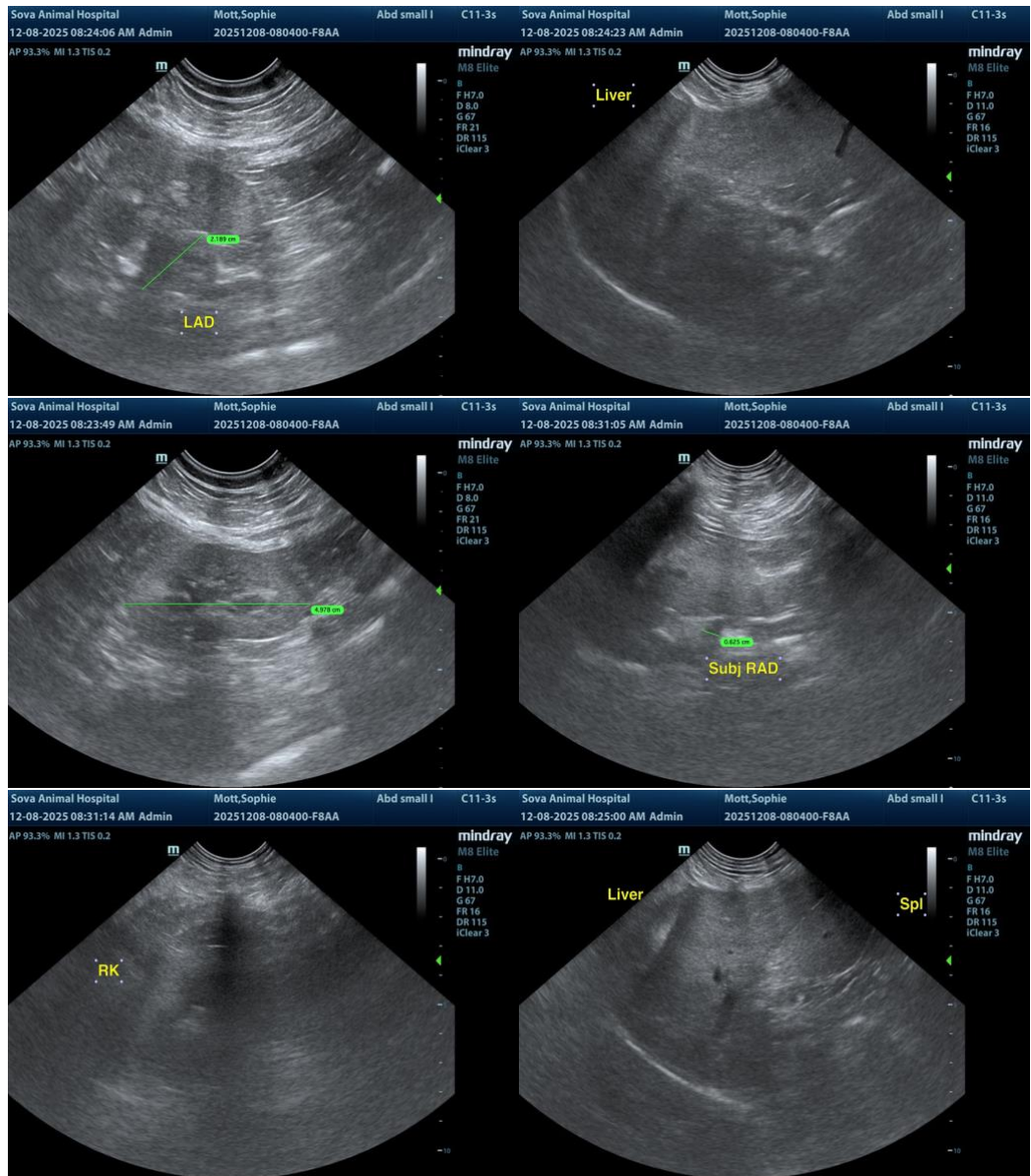
Dr. Ammeraal

**INVOICE**

12628

**DATE**

12/08/25



The information and recommendations provided are based on the images presented by the referring veterinarian/sonographer. No evaluation can be communicated regarding pathology that was not visible in the image/video clips provided.

Thank you for this referral. If the clinical or image interpretation does not parallel your findings or if I can be of any further assistance, please contact me.

R. McKenzie Daniel, DVM, DABVP (Canine / Feline Practice)

[info@SonoPath.com](mailto:info@SonoPath.com)