



PATIENT PRESENTING CLINICAL SIGNS

PATIENT Zoey Appleton
PRESENTING CLINICAL SIGNS History: Long history of managed pituitary hyperadrenocorticism, significant weight loss, decreased appetite, normal interest in food for duration of 10 months, possible nausea, elevated cPL, concern for intratumoral necrosis of right lateral thorax SQ mass

SPECIES

Canine
 Medication: Vetoryl, Denamarin

ALP 539, ALT 94, GGT 8. CBC – Mild lymphopenia and thrombocytosis.

BREED

ULTRASONOGRAPHIC EXAMINATION OF THE ABDOMEN AND SQ MASS

Lab Mix

Urinary System

SEX

FS

The urinary bladder, trigone, cystourethral junction, and visible pelvic urethra to a depth of 3.0 cm exhibited normal thickness and tone. Anechoic urine was present in the lumen with no uroliths or sediment. The ureteral papillae were normal. The ureters were not visible which is normal. No evidence of inflammatory or neoplastic changes were noted.

AGE

12 years

Normal size and margination were present in the kidneys. A normal 1:3 cortex / medulla ratio and normal corticomedullary definition were maintained. The echogenicity of the cortex was similar to or slightly less than normal liver parenchyma while the medulla echogenicity was hypoechoic to the cortex with no evidence of pelvic dilation. The left kidney measured 6.5 cm. The right kidney measured 5.8 cm.

WEIGHT

48 Pounds

Adrenal Glands

Bilateral symmetrical adrenal gland enlargement with uniformly hypoechoic parenchyma was present. The left adrenal gland measured 0.75 cm at the cranial pole and 1.1 cm at the caudal pole. The right adrenal gland measured 1.7 cm at the cranial pole and 0.86 cm at the caudal pole.

INTERPRETED BY

R. McKenzie Daniel,
 DVM, DABVP
 (Canine and Feline)

Spleen

The spleen was normal in size and contour and exhibited primarily finely textured and homogenous parenchyma which was hyperechoic to the liver and renal cortical parenchyma. Multifocal, well-defined, symmetrical, echogenic nodules were present throughout the cranial to caudal parenchyma. The capsule was smooth and regular without apparent expansion. The splenic vasculature at the hilus was normal in volume with no evidence of congestion or thrombosis. Acute to chronic inflammatory or neoplastic changes were not noted. The echogenic nodules tend to trend benign and are most consistent with benign hyperplasia or myelolipomas.

IMAGING PERFORMED BY

Rebekah Jakum, CVT
 ARDMS/RVT

Liver

The liver was mildly enlarged. The liver parenchyma was mildly nonuniform and hypoechoic to the spleen with a moderate coarse echotexture and subjective mild to benign parenchymal remodeling. Intermittent uniformly echogenic, non-expansive intraparenchymal nodules were present. The hepatic and portal vasculature were normal in appearance without signs of congestion. The gallbladder was non distended in size with mild, echogenic, nonmineralized biliary sludge. The cystic duct and common bile ducts were normal without evidence of dilation.

HOSPITAL NAME

Alburtis AH

REFERRING VET

Dr. Smith

Gastrointestinal

INVOICE

33351

The stomach presented intact wall layering with a normal wall layer ratio. The lumen of the stomach was empty with no signs of ileus, obstruction or foreign material.

DATE

12.8.2021

The small intestine presented intact wall layering with 1:3 muscularis/mucosa ratio. The lumen of the small intestine was empty with no signs of ileus, obstruction or foreign material.



PATIENT Normal visible colon wall layers were present with apparent formed feces in lumen.

Zoey Appleton **Pancreas**

The parenchyma of the left limb, body and right limb of the pancreas presented isoechoic to the adjacent omental fat. A normal curvilinear capsule contour of the pancreas was present. The visible pancreatic duct was normal. No signs of active inflammation or neoplastic disease was evident.

SPECIES

Canine

Free Abdomen

BREED

No omental masses, lymphadenopathy or peritoneal effusion.

Lab Mix

A moderately sized to large mixed echogenic subcutaneous mass in the area of the right thorax was present. The mass measured approximately 10-11 cm in diameter, but potentially larger, as the entire mass would not fit into a single viewing window. Overt evidence of areas of intratumoral fluid accumulation or abscessation was not definitively evident. Potential for focal areas of mineralization possible.

SEX

FS

ULTRASONOGRAPHIC FINDINGS

AGE

12 years

- Mixed echogenic subcutaneous mass right thorax
- Mild hepatomegaly with non-uniform to focal echogenic nodular parenchyma – subjectively benign.
- Benign splenic nodules – likely consistent with benign myelolipomas.
- Bilateral adrenomegaly – consistent with PDH.
- Sonographically unremarkable to mildly heterogeneous pancreas
- Mild to moderate gallbladder debris (non-mucocele)

WEIGHT

48 Pounds

INTERPRETATION OF THE FINDINGS & FURTHER RECOMMENDATIONS

INTERPRETED BY

R. McKenzie Daniel,
DVM, DABVP
(Canine and Feline)

Potential for low-grade to chronic pancreatitis or structurally insignificant gastrointestinal disease (given the patient’s weight loss) and gastrointestinal signs may be possible. Further assessment may include GI panel to include PLI, TLI, cobalamin and folate. The right thorax subcutaneous mass was not overtly consistent with fat echogenicity with concern for potential neoplastic process warranted. If not done, ultrasound guided FNA of the subcutaneous mass or biopsy suggested for further clarification. If not recently done, 3-view chest radiographs would be suggested to assess for intrathoracic pathology. Continued as needed gastrointestinal support or conservative therapy for low-grade to chronic pancreatitis recommended.

IMAGING PERFORMED BY

Rebekah Jakum, CVT
ARDMS/RVT

HOSPITAL NAME

Alburtis AH

REFERRING VET

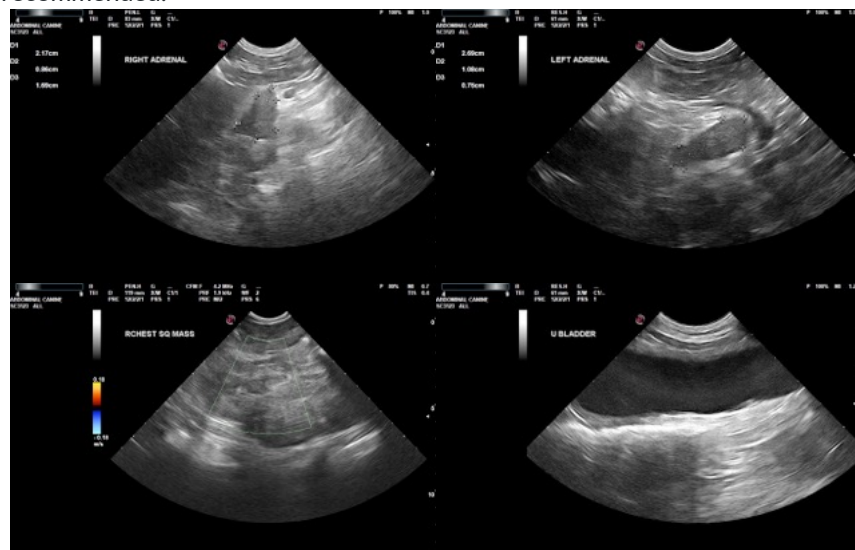
Dr. Smith

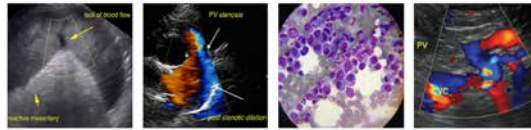
INVOICE

33351

DATE

12.8.2021





PATIENT

Zoey Appleton

SPECIES

Canine

BREED

Lab Mix

SEX

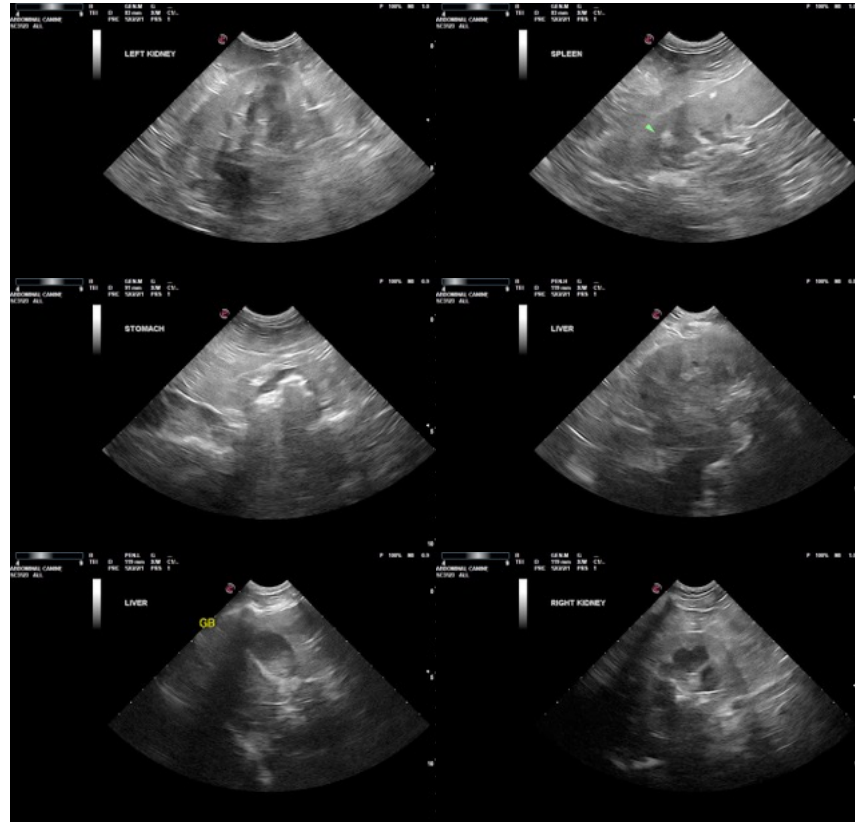
FS

AGE

12 years

WEIGHT

48 Pounds



INTERPRETED BY

R. McKenzie Daniel,
DVM, DABVP
(Canine and Feline)

**IMAGING
PERFORMED BY**

Rebekah Jakum, CVT
ARDMS/RVT

HOSPITAL NAME

Alburtis AH

REFERRING VET

Dr. Smith

INVOICE

33351

DATE

12.8.2021

The information and recommendations provided are based on the images presented by the referring veterinarian. No evaluation can be communicated regarding pathology that was not visible in the image/video clips provided.

Thank you for this referral. If the clinical or image interpretation does not parallel your findings or if I can be of any further assistance please contact me.

R. McKenzie Daniel, DVM, DABVP (Canine/Feline Practice)
mac.daniel@sonopath.com