



PATIENT

Linus Sammarco

SPECIES

Felinke

BREED

DSH

SEX

MN

AGE

8 years

WEIGHT

18.4

INTERPRETED BY

R. McKenzie Daniel,
DVM, DABVP
(Canine and Feline)

**IMAGING
PERFORMED BY**

Dana Nause, DVM

HOSPITAL NAME

Fredon AH

REFERRING VET

Tech

INVOICE

12763

DATE

12/7/21

PRESENTING CLINICAL SIGNS

Sneezing, vomiting, lethargic, decreased appetite
Abnormal PE/Chem/CBC/UA Results: wnl

ULTRASONOGRAPHIC EXAMINATION OF THE ABDOMEN

Urinary System

The urinary bladder, trigone, cystourethral junction, and visible pelvic urethra to a depth of 2.0 cm exhibited normal thickness and tone. Anechoic urine was present in the lumen with no uroliths or sediment. The ureteral papillae were normal. The ureters were not visible which is normal. No evidence of inflammatory or neoplastic changes was noted.

The area of the aortic trifurcation was free of pathology.

Normal size and margination were present in the kidneys. A normal 1:3 cortex / medulla ratio and normal corticomedullary definition were maintained. The echogenicity of the cortex was similar to or slightly less than normal liver parenchyma while the medulla echogenicity was hypoechoic to the cortex with no evidence of pelvic dilation. The left kidney measured 4.3 cm in length. The right kidney measured 4.3 cm in length.

Adrenal Glands

The left adrenal gland was uniform in size and contour with a uniformly hypoechoic parenchyma. The left adrenal gland measured 0.52 cm width. The area of the right adrenal gland was free of overt pathology, although not definitively visualized.

Spleen

The spleen exhibited a finely textured and homogenous parenchyma which was hyperechoic to the liver and renal cortical parenchyma. The capsule was smooth and regular without apparent expansion. The splenic vasculature at the hilus was normal in volume with no evidence of congestion or thrombosis. Acute to chronic inflammatory, neoplastic, or benign parenchyma changes were not noted.

Liver/ Gallbladder

The liver was subjectively normal in size, structure, and contour. The liver parenchyma was uniform and hypoechoic to the spleen with a mild coarse echotexture. The hepatic and portal vasculature were normal in appearance without signs of congestion. The gallbladder was non-distended in size with thin walls and primarily anechoic luminal content. The cystic and common bile ducts were normal.

Gastrointestinal

The stomach presented intact wall layering with a normal wall layer ratio. The lumen of the stomach was empty without evidence of retained ingesta, fluid, or foreign material and mild luminal gas. The gastric body wall width measured 0.28 cm. The pylorus wall width measured 0.36 cm.

The small intestine presented intact wall layering with 1:3 muscularis/mucosa ratio. The lumen of the small intestine was empty with no signs of ileus, obstruction, or foreign material. The jejunum wall width measured 0.26 cm.



PATIENT

Normal visible colon wall layers were present with apparent formed feces in lumen.

Linus Sammarco

Pancreas

SPECIES

The parenchyma of the left limb, body, and right limb of the pancreas presented isoechoic to the adjacent omental fat. A normal curvilinear capsule contour of the pancreas was present. The visible pancreatic duct was normal. No signs of active inflammation or neoplastic disease were evident.

Felinke

BREED

Free Abdomen

DSH

No overt lymphadenopathy or peritoneal effusion was present. Subjective increased amount of intraabdominal falciform fat was present.

SEX

ULTRASONOGRAPHIC FINDINGS

MN

Primary Findings

AGE

- Sonographically unremarkable abdomen

8 years

INTERPRETATION OF THE FINDINGS & FURTHER RECOMMENDATIONS

WEIGHT

No evidence of significant visceral, specifically gastrointestinal or pancreatic, pathology as an obvious cause of the patient's decreased appetite and vomiting. The potential for structurally insignificant inflammatory gastroenteropathy or low grade to chronic pancreatitis, both of which may present in normal sonographic manner, cannot be excluded.

18.4

INTERPRETED BY

R. McKenzie Daniel,
DVM, DABVP
(Canine and Feline)

Empirically, GI support +/- hairball therapy if clinically indicated, is recommended. Three view chest radiographs are suggested to assess for or rule out thoracic or esophageal pathology which may account for the patient's clinical signs.

IMAGING PERFORMED BY

Dana Nause, DVM

HOSPITAL NAME

Fredon AH

REFERRING VET

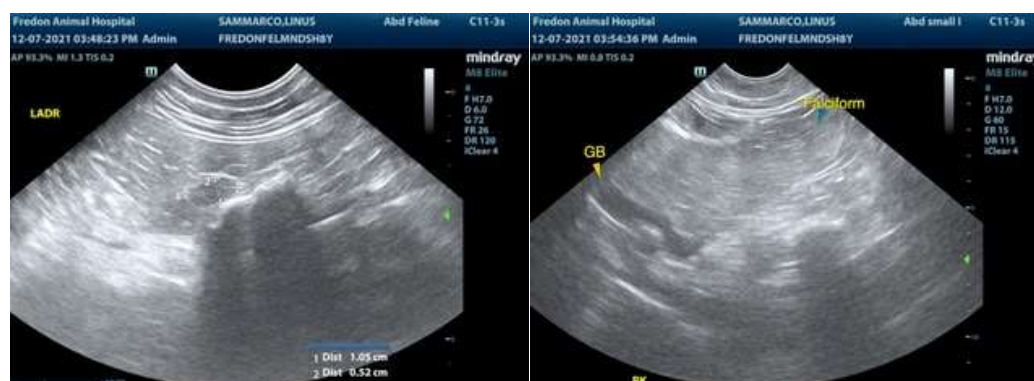
Tech

INVOICE

12763

DATE

12/7/21





PATIENT

Linus Sammarco

SPECIES

Felinke

BREED

DSH

SEX

MN

AGE

8 years

WEIGHT

18.4

INTERPRETED BY

R. McKenzie Daniel,
DVM, DABVP
(Canine and Feline)

IMAGING PERFORMED BY

Dana Nause, DVM

HOSPITAL NAME

Fredon AH

REFERRING VET

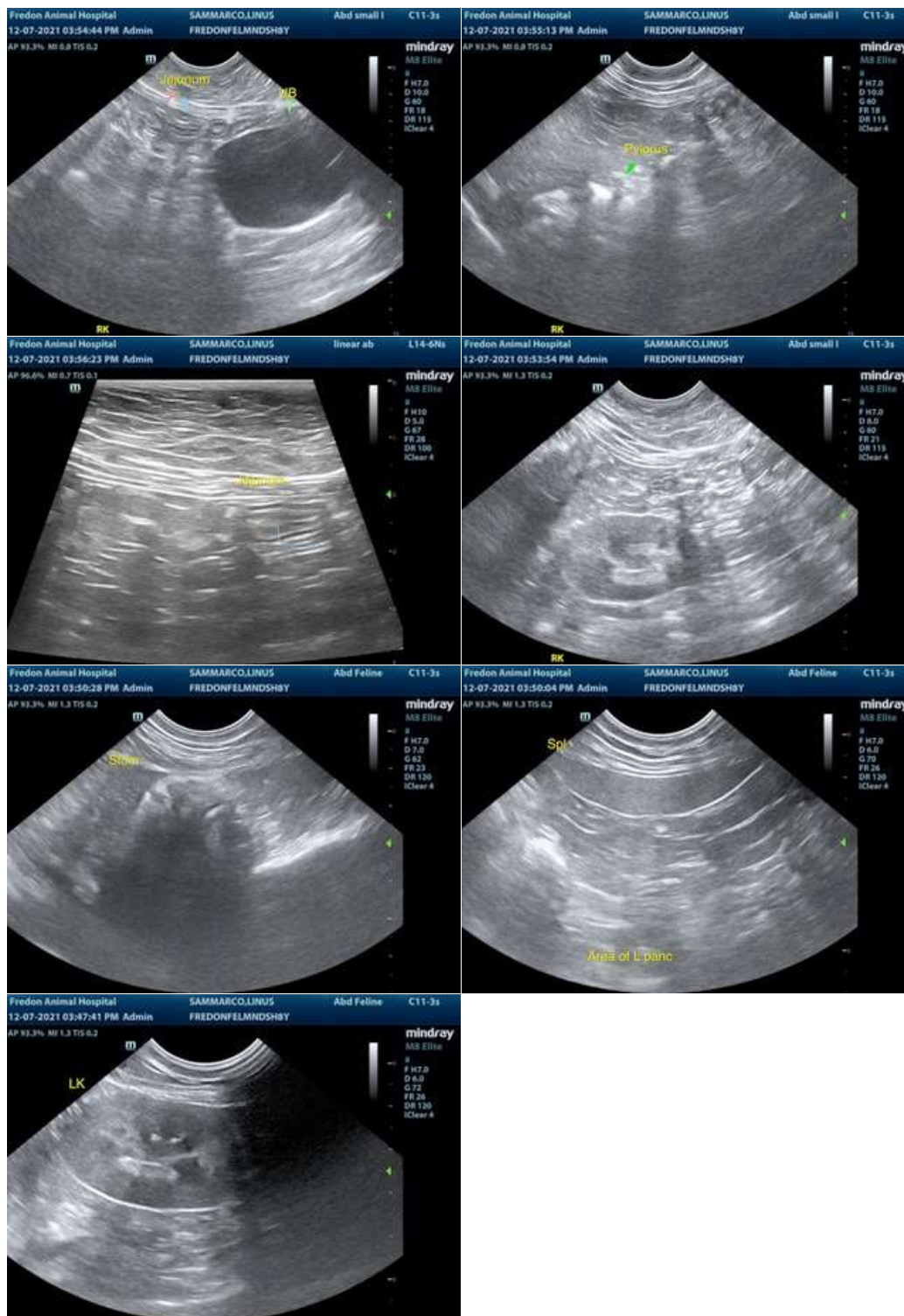
Tech

INVOICE

12763

DATE

12/7/21



The information and recommendations provided are based on the images presented by the referring veterinarian. No evaluation can be communicated regarding pathology that was not visible in the image/video clips provided.



PATIENT

Linus Sammarco

Thank you for this referral. If the clinical or image interpretation does not parallel your findings or if I can be of any further assistance please contact me.

SPECIES

Felinke

R. McKenzie Daniel, DVM, DABVP (Canine / Feline Practice)

info@SonoPath.com

BREED

DSH

SEX

MN

AGE

8 years

WEIGHT

18.4

INTERPRETED BY

R. McKenzie Daniel,
DVM, DABVP
(Canine and Feline)

**IMAGING
PERFORMED BY**

Dana Nause, DVM

HOSPITAL NAME

Fredon AH

REFERRING VET

Tech

INVOICE

12763

DATE

12/7/21