



PATIENT

Gizmo Leedholm

PRESENTING CLINICAL SIGNS

History: History of tenismus. Prostatomegally seen on x ray

SPECIES

Canine

ULTRASONOGRAPHIC EXAMINATION OF THE ABDOMEN

Urinary System

The urinary bladder, trigone and cystourethral junction exhibited normal thickness and tone. Anechoic urine was present in the lumen with no uroliths or sediment. The ureteral papillae were normal. The ureters were not visible which is normal. No evidence of inflammatory or neoplastic changes were noted.

BREED

Pitbull

The prostate was subjectively moderately enlarged in size with intact, symmetrical capsule contour. The margins of the gland were intact and able to be differentiated from the surrounding tissue. The prostatic parenchyma was mildly echogenic to heteroechoic without parenchymal mineralization. The prostate measured 4.5 cm in diameter.

SEX

Intact Male

Normal size and margination were present in the kidneys. A normal 1:3 cortex / medulla ratio and normal corticomedullary definition were maintained. The echogenicity of the cortex was similar to or slightly less than normal liver parenchyma while the medulla echogenicity was hypoechoic to the cortex with no evidence of pelvic dilation. The left kidney measured 5.4 cm in length. The right kidney measured 5.7 cm in length.

AGE

7

WEIGHT

22 kg

Adrenal Glands

The left adrenal gland was uniform in size and contour with a uniformly hypoechoic parenchyma. The left adrenal gland measured 0.63 cm width at the caudal pole and 0.51 cm width at the cranial pole.

INTERPRETED BY

R. McKenzie Daniel,
DVM, DABVP
(Canine and Feline)

The right adrenal gland was uniform in size and contour with a uniformly hypoechoic parenchyma. The right adrenal gland measured 0.47 cm width at the caudal pole and 0.62 cm width at the cranial pole.

IMAGING PERFORMED BY

Dr. Belan

Spleen

The spleen exhibited a finely textured and homogenous parenchyma which was hyperechoic to the liver and renal cortical parenchyma. The capsule was smooth and regular without apparent expansion. The splenic vasculature at the hilus was normal in volume with no evidence of congestion or thrombosis. Acute to chronic inflammatory, neoplastic, or benign parenchyma changes were not noted.

HOSPITAL NAME

Ramsay VC

Liver

The liver was subjectively normal in size, structure, and contour. The liver parenchyma was uniform and hypoechoic to the spleen with a mild coarse echotexture. The hepatic and portal vasculature were normal in appearance without signs of congestion. The gallbladder was non-distended in size with thin walls and primarily anechoic luminal content. The cystic and common bile ducts were normal.

REFERRING VET

Dr. Gupta

Gastrointestinal

The stomach presented intact wall layering with a normal wall layer ratio. Minor retained nonshadowing chyme was present.

INVOICE

19057

The small intestine presented intact wall layering with 1:3 muscularis/mucosa ratio. The lumen of the small intestine was empty with no signs of ileus, obstruction or foreign material.

DATE

12/6/22



PATIENT

Gizmo Leedholm

The colon walls presented intact yet subjective mild prominent wall layering with mild thickened to echogenic submucosa. The descending colon was empty with descending colon wall potentially measuring 0.5 cm – 0.6 cm wall width.

SPECIES

Canine

Pancreas

The parenchyma of the left limb, body and right limb of the pancreas presented isoechoic to the adjacent omental fat. A normal curvilinear capsule contour of the pancreas was present. The visible pancreatic duct was normal. No signs of active inflammation or neoplastic disease was evident.

BREED

Pitbull

Free Abdomen

Discrete, mildly prominent medial iliac lymph nodes were present. The lymph nodes were essentially isoechoic to adjacent omentum without evidence of peripheral inflammation or neoplastic criteria and maintaining a normal width: length ratio (<0.5). This is an incidental finding. An example of lymph node measured 0.63 cm diameter.

SEX

Intact Male

Intermittent, mildly prominent mesenteric lymph nodes were present. The lymph nodes were essentially isoechoic to adjacent omentum without evidence of peripheral inflammation or neoplastic criteria and maintaining a normal width: length ratio (<0.5). This is an incidental finding.

AGE

7

ULTRASONOGRAPHIC FINDINGS

WEIGHT

22 kg

- Benign prostatic hyperplasia, minor potential for prostatitis
- Suspect mild descending colitis

INTERPRETATION OF THE FINDINGS & FURTHER RECOMMENDATIONS

INTERPRETED BY

R. McKenzie Daniel,
DVM, DABVP
(Canine and Feline)

Prostatic sampling is required for further definition, although prostatitis is considered less likely based on sonographic appearance without evidence of prostatic neoplastic criteria. The moderate prostatomegaly may be impinging somewhat on the ventral aspect of the associated regional descending colon, although subjectively the degree of prostatic enlargement was not overtly consistent with significant colonic impingement, potentially indicating concurrent descending colon inflammation as a contributing factor. If no evidence of concurrent mucoid or bloody diarrhea, neutering is likely ideal in this patient, while empirical therapy for colitis, if clinically indicated, may be considered.

IMAGING PERFORMED BY

Dr. Belan

HOSPITAL NAME

Ramsay VC

REFERRING VET

Dr. Gupta

INVOICE

19057

DATE

12/6/22



PATIENT

Gizmo Leedholm

SPECIES

Canine

BREED

Pitbull

SEX

Intact Male

AGE

7

WEIGHT

22 kg

INTERPRETED BY

R. McKenzie Daniel,
DVM, DABVP
(Canine and Feline)

IMAGING PERFORMED BY

Dr. Belan

HOSPITAL NAME

Ramsay VC

REFERRING VET

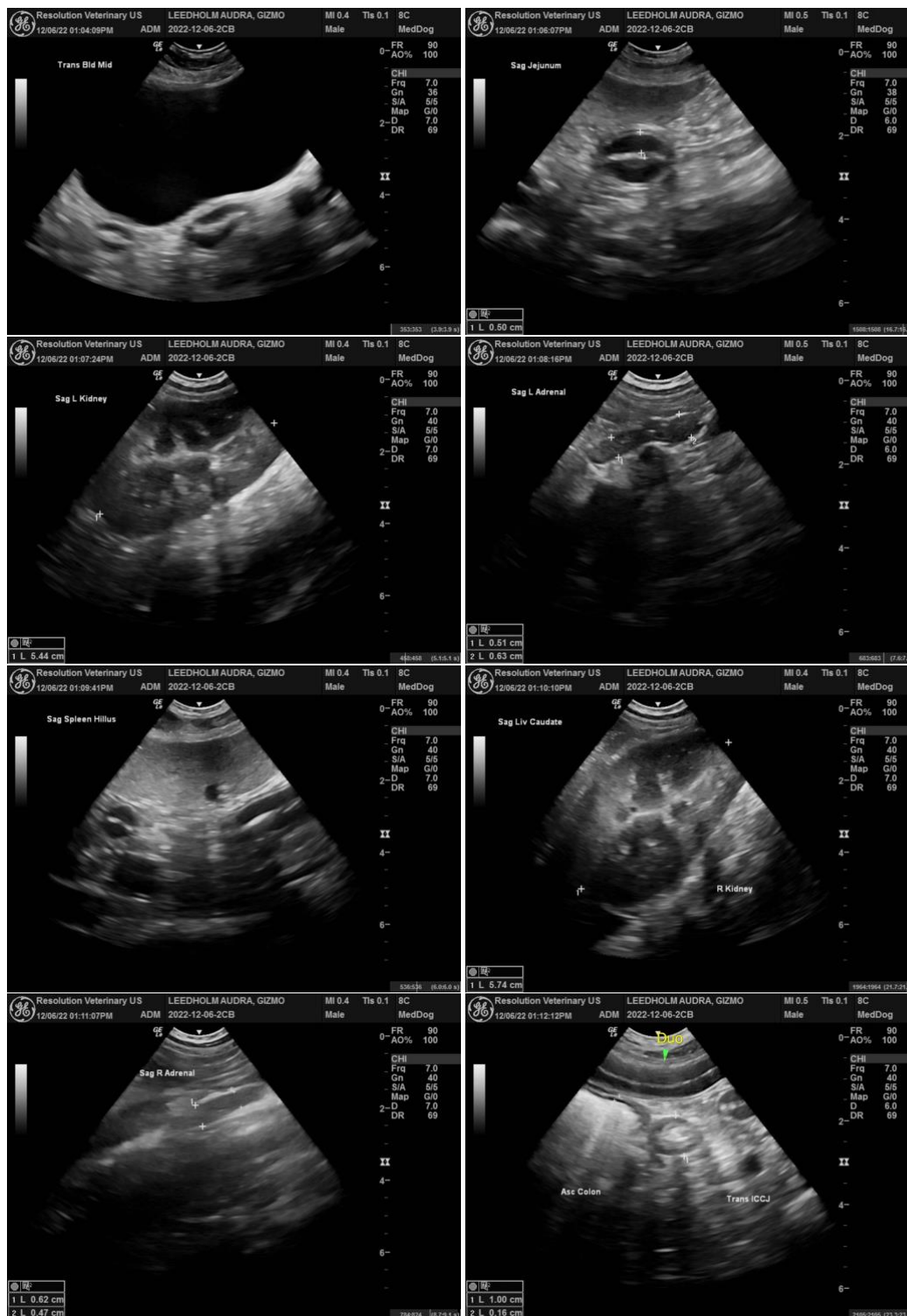
Dr. Gupta

INVOICE

19057

DATE

12/6/22





PATIENT

Gizmo Leedholm

SPECIES

Canine

BREED

Pitbull

SEX

Intact Male

AGE

7

WEIGHT

22 kg

INTERPRETED BY

R. McKenzie Daniel,
DVM, DABVP
(Canine and Feline)

IMAGING PERFORMED BY

Dr. Belan

HOSPITAL NAME

Ramsay VC

REFERRING VET

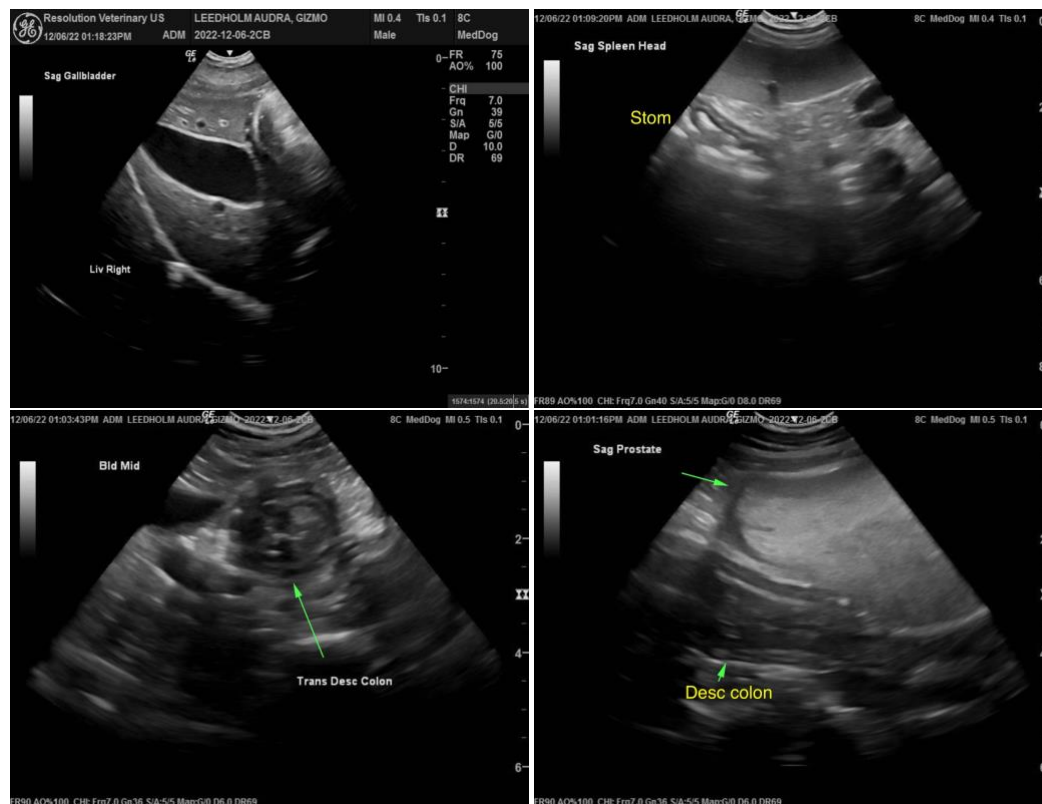
Dr. Gupta

INVOICE

19057

DATE

12/6/22



The information and recommendations provided are based on the images presented by the referring veterinarian. No evaluation can be communicated regarding pathology that was not visible in the image/video clips provided.

Thank you for this referral. If the clinical or image interpretation does not parallel your findings or if I can be of any further assistance please contact me.

R. McKenzie Daniel, DVM, DABVP (Canine / Feline Practice)
info@SonoPath.com