



**PATIENT PRESENTING CLINICAL SIGNS**

Tiggey Lugo drooling, fpl abnormal  
Abnormal PE/Chem/CBC/UA Results: fpl abnormal

**SPECIES ULTRASONOGRAPHIC EXAMINATION OF THE ABDOMEN**

Feline

**Urinary System**

**BREED**

DSH

The urinary bladder, trigone, cystourethral junction, and visible pelvic urethra to a depth of 2.0 cm exhibited normal thickness and tone. Primarily anechoic urine was present in the lumen. Mild non-dependent particulate sediment was present without evidence of calculus formation. The ureteral papillae were normal. The ureters were not visible which is normal. No evidence of inflammatory or neoplastic mural changes were noted.

**SEX**

Spayed Female

The area of the aortic trifurcation was free of pathology.

**AGE**

11 Years

Normal size and margination were present in the kidneys. A normal 1:3 cortex / medulla ratio and normal corticomedullary definition were maintained. The echogenicity of the cortex was similar to or slightly less than normal liver parenchyma while the medulla echogenicity was hypoechoic to the cortex with no evidence of pelvic dilation. The left kidney measured 3.5 cm. The right kidney measured 3.9 cm.

**Adrenal Glands**

**WEIGHT**

10.4 Pounds

The adrenal glands were uniform in size and contour with a uniformly hypoechoic parenchyma. The left adrenal gland measured 0.46 cm in width. The right adrenal gland measured 0.40 cm.

**Spleen**

**INTERPRETED BY**

R. McKenzie Daniel,  
DVM, DABVP  
(Canine and Feline)

The spleen exhibited a finely textured and homogenous parenchyma which was hyperechoic to the liver and renal cortical parenchyma. The spleen measured 0.82 cm in width. The capsule was smooth and regular without apparent expansion. The splenic vasculature at the hilus was normal in volume with no evidence of congestion or thrombosis. Acute to chronic inflammatory, neoplastic, or benign parenchyma changes were not noted.

**IMAGING PERFORMED BY**

Jessica Miller

**Liver**

**HOSPITAL NAME**

Newton Vet Hospital

The liver was subjectively normal in size, structure, and contour. The liver parenchyma was uniform and hypoechoic to the spleen with a mild coarse echotexture. The hepatic and portal vasculature were normal in appearance without signs of congestion. The gallbladder was non-distended in size with anechoic content extending into a mildly dilated cystic duct. The common bile duct was normal. No evidence of post-hepatic obstruction.

**REFERRING VET**

Dr. Kim

**Gastrointestinal**

**INVOICE**

33282

The stomach presented intact wall layering with a normal wall layer ratio. The lumen of the stomach was empty with no signs of ileus, obstruction or foreign material. Pylorus wall measured 0.30 cm.

The small intestine presented intact wall layering with 1:3 muscularis/mucosa ratio. The lumen of the small intestine was empty with no signs of ileus, obstruction or foreign material. Duodenum wall measured 0.23 cm. Jejunum wall measured 0.27 cm. Ileocolic wall measured 0.38 cm.

Normal visible colon wall layers were present with apparent formed feces in lumen.

**DATE**

12/6/21



**PATIENT**

**Pancreas**

Tiggey Lugo

The pancreas was normal in size and contour with isoechoic to heterogeneous parenchyma compared to adjacent omentum. No signs of active inflammation or neoplasia.

**SPECIES**

**Free Abdomen**

Feline

Intermittent mildly prominent colic lymph nodes were present. Example of lymph node measured 0.32 cm in width. These lymph nodes were homogenous, mildly hypoechoic and smoothly margined. A normal width: length ratio was maintained (<0.5). Evidence of perilymphatic inflammation was evident.

**BREED**

DSH

No effusion.

**SEX**

Spayed Female

- Mild urinary bladder sediment
- Early age related renal changes
- Mild heterogeneous pancreas
- Sonographically unremarkable gastrointestinal tract

**AGE**

11 Years

**INTERPRETATION OF THE FINDINGS & FURTHER RECOMMENDATIONS**

The urinary bladder sediment may suggest cellular / crystalline debris or mucus. Cystocentesis for UA +/- C/S if evidence of inflammatory cells is recommended.

**WEIGHT**

10.4 Pounds

The sonographic appearance of the pancreas was not overtly consistent with active pancreatitis. However, low-grade or chronic pancreatitis may be present and ultrasonographically normal. Likewise, the possibility of structurally insignificant gastroenteropathy cannot be excluded.

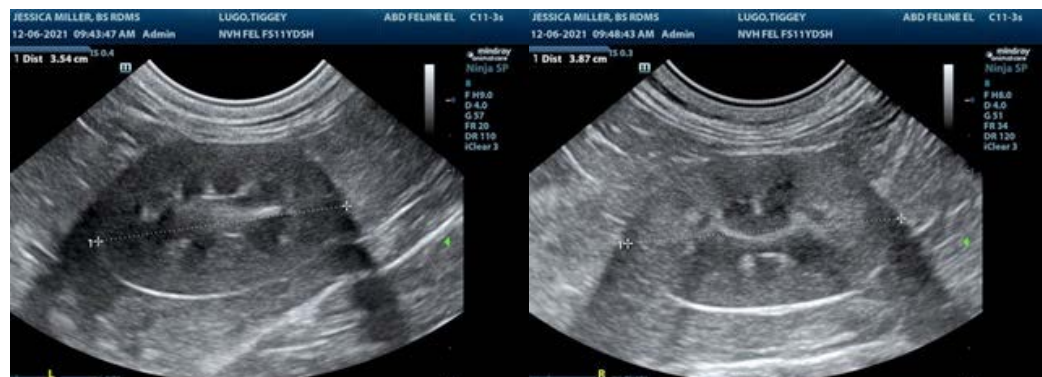**INTERPRETED BY**

R. McKenzie Daniel,  
DVM, DABVP  
(Canine and Feline)

Assuming no evidence of oral disease and no evidence of thoracic or esophageal pathology on 3-view chest radiographs, as needed gastrointestinal support and conservative therapy for potential low-grade to chronic pancreatitis is recommended. Recheck sonogram would be appropriate if continued clinical signs to assess for progressive inflammatory gastrointestinal or pancreatic changes.

**IMAGING PERFORMED BY**

Jessica Miller



**HOSPITAL NAME**

Newton Vet Hospital

**REFERRING VET**

Dr. Kim

**INVOICE**

33282

**DATE**

12/6/21



**PATIENT**

Tiggey Lugo

**SPECIES**

Feline

**BREED**

DSH

**SEX**

Spayed Female

**AGE**

11 Years

**WEIGHT**

10.4 Pounds

**INTERPRETED BY**

R. McKenzie Daniel,  
DVM, DABVP  
(Canine and Feline)

**IMAGING PERFORMED BY**

Jessica Miller

**HOSPITAL NAME**

Newton Vet Hospital

**REFERRING VET**

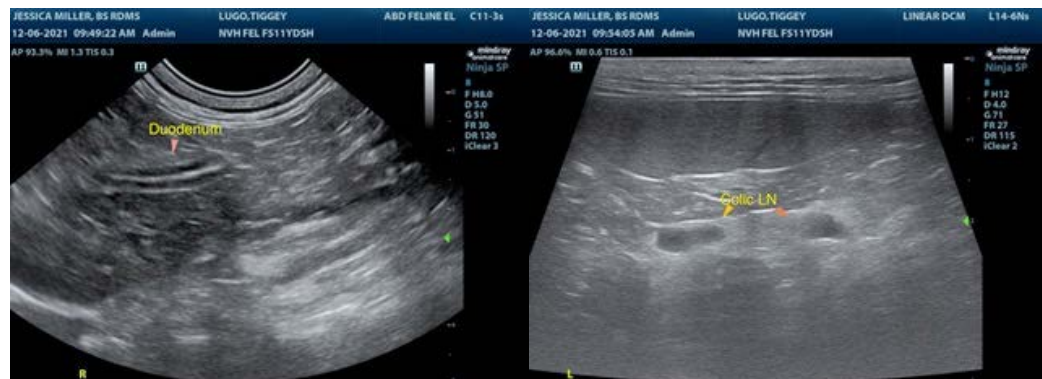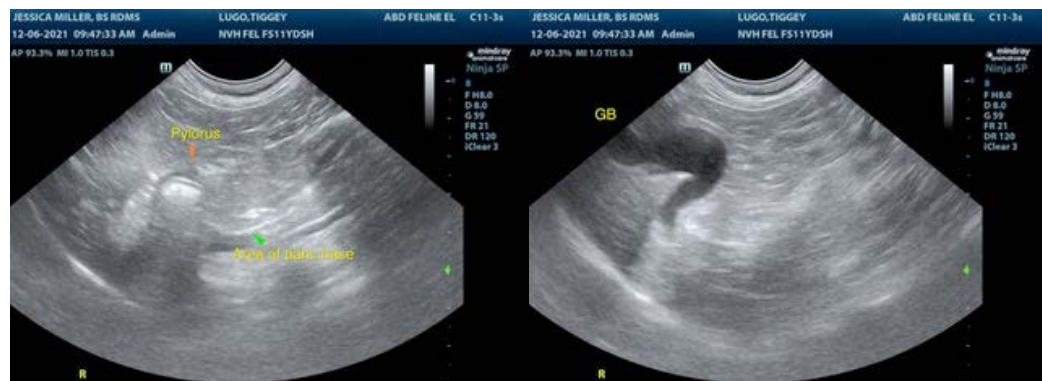
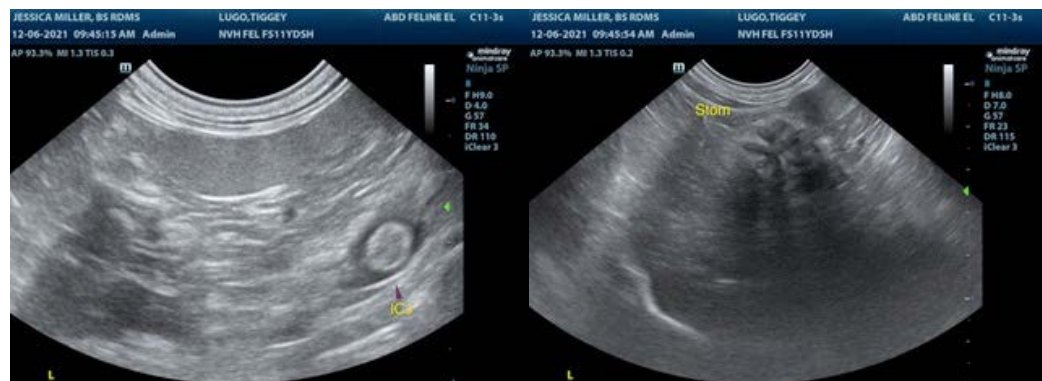
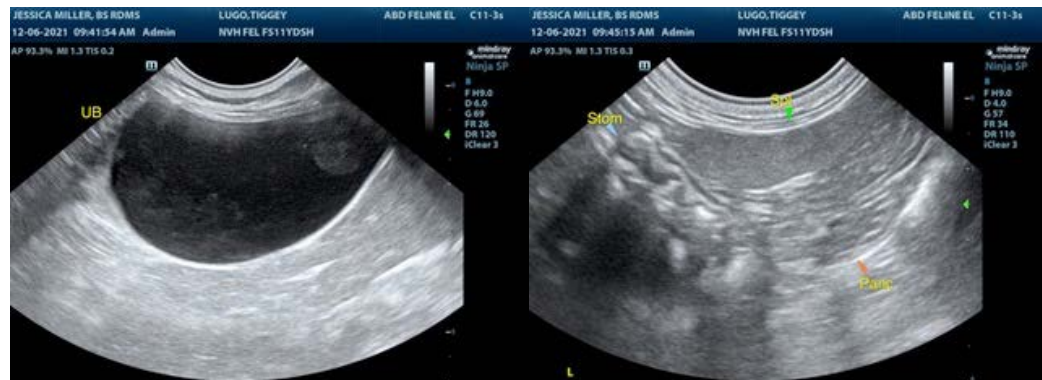
Dr. Kim

**INVOICE**

33282

**DATE**

12/6/21





**PATIENT**

Tiggey Lugo

**SPECIES**

Feline

**BREED**

DSH

**SEX**

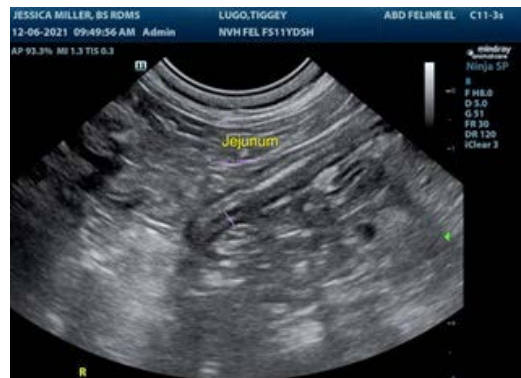Spayed Female

**AGE**

11 Years

**WEIGHT**

10.4 Pounds



The information and recommendations provided are based on the images presented by the referring veterinarian. No evaluation can be communicated regarding pathology that was not visible in the image/video clips provided.

Thank you for this referral. If the clinical or image interpretation does not parallel your findings or if I can be of any further assistance please contact me.

**R. McKenzie Daniel, DVM, DABVP (Canine / Feline Practice)**  
info@SonoPath.com

**INTERPRETED BY**

R. McKenzie Daniel,  
DVM, DABVP  
(Canine and Feline)

**IMAGING PERFORMED BY**

Jessica Miller

**HOSPITAL NAME**

Newton Vet Hospital

**REFERRING VET**

Dr. Kim

**INVOICE**

33282

**DATE**

12/6/21