



PATIENT	PRESENTING CLINICAL SIGNS
Hazel Pazmino	P presented three weeks ago for diarrhea with blood that lasted for one week, fecal test was done (NEG) and was sent home with antibiotics (metro 100mg) and probiotics but meds did not work. O came back 4 days after and P was sent with Tylosin 10 mg and i/d diet (dry)- P got better afterwards, but last Friday (Dec 2nd) diarrhea came back even while on medication, only lasting 24hrs. Stool has been normal over the weekend. Eating and drinking normal as well as BAR. GI panel is currently being done.
SPECIES	
Canine	
BREED	ULTRASONOGRAPHIC EXAMINATION OF THE ABDOMEN
Shih Tzu	Urinary System
SEX	The urinary bladder, trigone, cystourethral junction, and visible pelvic urethra to a depth of 1 cm exhibited normal thickness and tone. Anechoic urine was present in the lumen with no uroliths or sediment. The ureteral papillae were normal. The ureters were not visible which is normal. No evidence of inflammatory or neoplastic changes were noted.
FS	
AGE	Normal size and margination were present in the kidneys. A normal 1:3 cortex / medulla ratio and normal corticomedullary definition were maintained. The echogenicity of the cortex was similar to or slightly less than normal liver parenchyma while the medulla echogenicity was hypoechoic to the cortex with no evidence of pelvic dilation. The left kidney measured 3.9 cm in length. The right kidney measured 4.5 cm in length.
5yr	
WEIGHT	The area of the aortic trifurcation was free of pathology.
11.6	Adrenal Glands
INTERPRETED BY	The left adrenal gland was uniform in size and contour with a uniformly hypoechoic parenchyma. The left adrenal gland measured 0.42 cm width at the caudal pole and 0.38 cm width at the cranial pole. The right adrenal gland was indistinctly visualized without overt pathology.
R. McKenzie Daniel, DVM, DABVP (Canine and Feline)	Spleen
IMAGING PERFORMED BY	The spleen exhibited a finely textured and homogenous parenchyma which was hyperechoic to the liver and renal cortical parenchyma. The capsule was smooth and regular without apparent expansion. The splenic vasculature at the hilus was normal in volume with no evidence of congestion or thrombosis. Acute to chronic inflammatory, neoplastic, or benign parenchyma changes were not noted.
Dr. Kim	Liver
HOSPITAL NAME	The liver was subjectively normal in size, structure, and contour. The liver parenchyma was uniform and hypoechoic to the spleen with a mild coarse echotexture. The hepatic and portal vasculature were normal in appearance without signs of congestion. The gallbladder was non-distended in size with thin walls and primarily anechoic luminal content. The cystic and common bile ducts were normal.
Ridgefield Park Animal Hospital	Gastrointestinal
REFERRING VET	The stomach presented intact wall layering with a normal wall layer ratio. The lumen of the stomach contained mild non-shadowing ingesta/chyme with no signs of ileus, obstruction or foreign material.
Dr. Kim	The small intestine presented intact wall layering with 1:3 muscularis/mucosa ratio. The lumen of the small intestine was empty with no signs of ileus, obstruction or foreign material.
INVOICE	Normal visible colon wall layers were present with apparent semi formed to soft feces in lumen.
12378ag	
DATE	
12/05/2022	



PATIENT

Pancreas

Hazel Pazmino

The parenchyma of the left limb, body and right limb of the pancreas presented isoechoic to the adjacent omental fat. A normal curvilinear capsule contour of the pancreas was present. The visible pancreatic duct was normal. No signs of active inflammation or neoplastic disease was evident.

SPECIES

Canine

Free Abdomen

No omental masses, overt lymphadenopathy or peritoneal effusion was present.

BREED

Shih Tzu

ULTRASONOGRAPHIC FINDINGS

- Sonographically unremarkable GI tract/colon with mild gastric ingesta

INTERPRETATION OF THE FINDINGS & FURTHER RECOMMENDATIONS

SEX

FS

Overall, there is no overt evidence of significant abdominal visceral specifically gastroenterocolic pathology as a definitive cause of the patient's clinical signs. At times the sonographic presentation of the gastrointestinal tract may not correlate with reported recent/recurrent gastrointestinal signs. In patients with ongoing GI signs, considerations including dietary intolerance / food hypersensitivity even with recent bland diet, occult parasitism, dysbiosis/primary low-grade colitis, inflammatory bowel disease or low grade to chronic pancreatitis-both of which may present sonographically normal or other are possible. A less likely consideration is infiltrative neoplasia. Correlation with pending GI panel is recommended.

AGE

5yr

WEIGHT

11.6

Empirically, a limited antigen or hydrolyzed diet trial with potential long term dietary therapy, prophylactic deworming (Panacur 50 mg/kg SID x 5 consecutive days with repeat protocol in 3 weeks even if fecal testing is negative), high colony count probiotic (Provable or Visbiome), +/- antibiotic trial (although long term antibiotic therapy may contribute to alternations in GI flora) and as needed gastrointestinal support with assessment of clinical response may prove beneficial.

INTERPRETED BY

R. McKenzie Daniel,
DVM, DABVP
(Canine and Feline)

IMAGING PERFORMED BY

Dr. Kim

HOSPITAL NAME

Ridgefield Park
Animal Hospital

REFERRING VET

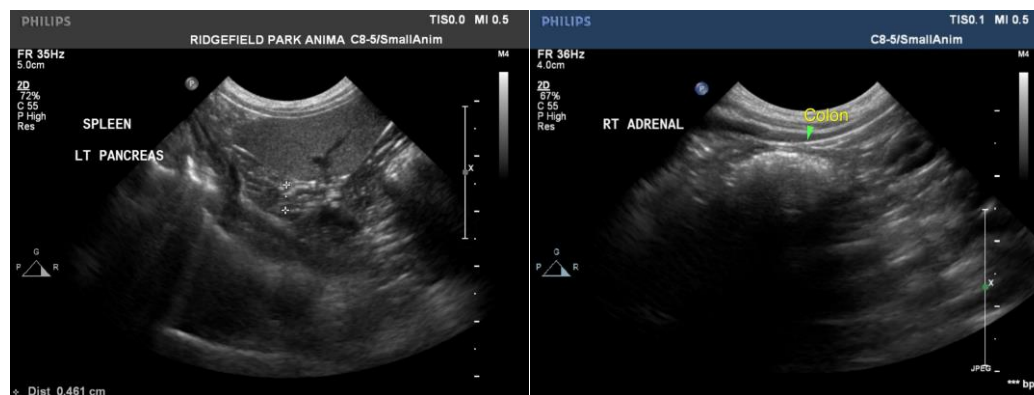Dr. Kim

INVOICE

12378ag

DATE

12/05/2022





PATIENT

Hazel Pazmino

SPECIES

Canine

BREED

Shih Tzu

SEX

FS

AGE

5yr

WEIGHT

11.6

INTERPRETED BY

R. McKenzie Daniel,
DVM, DABVP
(Canine and Feline)

IMAGING PERFORMED BY

Dr. Kim

HOSPITAL NAME

Ridgefield Park
Animal Hospital

REFERRING VET

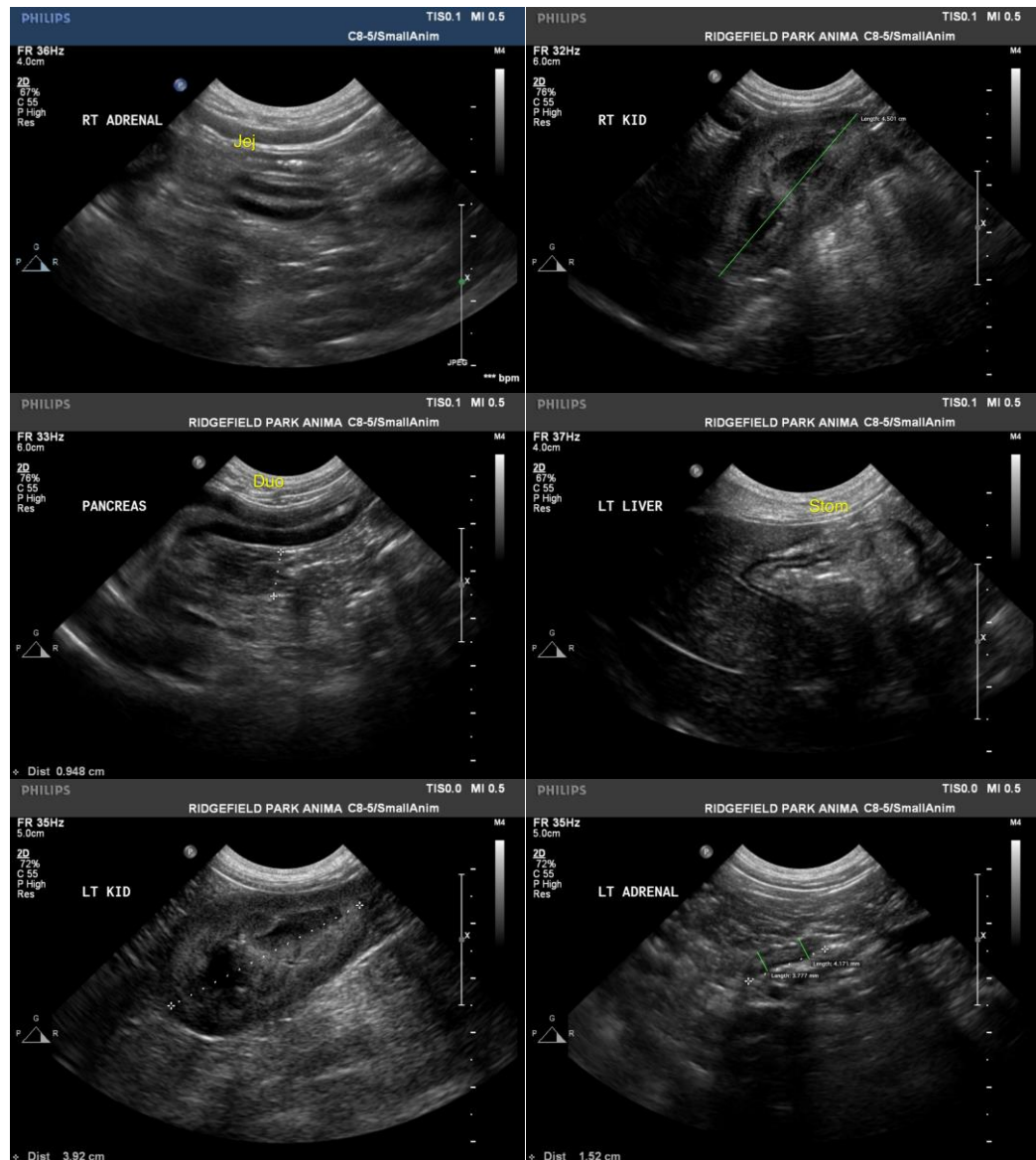
Dr. Kim

INVOICE

12378ag

DATE

12/05/2022



The information and recommendations provided are based on the images presented by the referring veterinarian/sonographer. No evaluation can be communicated regarding pathology that was not visible in the image/video clips provided.

Thank you for this referral. If the clinical or image interpretation does not parallel your findings or if I can be of any further assistance, please contact me.

R. McKenzie Daniel, DVM, DABVP (Canine/Feline Practice)
mac.daniel@sonopath.com