


**PATIENT**

Binx VanDunk

**PRESENTING CLINICAL SIGNS**

Chronic coughing even while on Hycodan 5mg (1/2 tab BID), No murmur detected on PE and no issues noted on radiographs

**SPECIES**

Canine

**ULTRASONOGRAPHIC EXAMINATION OF THE HEART**
**BREED**

Pug Mix

**SEX**

FS

**AGE**

16yr

**WEIGHT**

35

CANINE CARDIAC PARAMETERS	MR VMAX (m/s)	TR VMAX (m/s)	LA/AO (Boon method)	LA/AO (Heart Base; Swe)	FS (%)	EF (%)	EPSS (cm)
NORMAL PARAMETER	4.5-5.5	<2.7	1.3	<1.3	28-40	40-100	<0.6
PATIENT				1.1	50	85	0.2
CANINE CARDIAC PARAMETERS	HR (BPM)	AV VMAX (m/s)	PV MAX (m/s)	BODY WEIGHT (kg)	LA 2D short axis Base view (cm)	LVIDd Avg; 2D and m-mode short axis (cm)	LVIDs Avg; 2D and m-mode short axis (cm)
NORMAL PARAMETER	50-100	0.7-1.7	0.7-1.6				
PATIENT	NM	NM	NM		2.5	2.5	

**Cardiac Presentation**

The echocardiogram in this patient demonstrated normal left atrial size based on 3 separate methods of LA evaluation. The cranial and caudal mitral valve leaflets presented normal linear structure, extension in systole, and union in diastole with normal kinesis. The left ventricle presented thicknesses with linear contour and was not dilated nor restricted. The myocardium presented normal echogenicity without subjective evidence of significant fibrotic or ischemic disease. Contractility of the ventricular walls was adequate and in normal range for this patient evidenced by the fractional shortening measurement and subjective evaluation of the different regions of the myocardium. The left ventricular outflow tract demonstrated normal laminar flow and subjective structural integrity. The right atrium and auricle revealed normal size, structure and content. No evidence of masses was noted. Tricuspid valvular assessment demonstrated adequate linear morphology and kinesis. The right ventricle was of normal size (1/3 diameter of LV), chordae structure, myocardial echogenicity and thickness. Pulmonary outflow tract assessment revealed normal valve structure, laminar flow, and diameter (approx. 1:1 pa/ao ratio). No visible pericardial or free pleura fluid was noted. The cranial mediastinum and pericardial and extra-cardiac regions were free of masses in the visible window.

**ULTRASONOGRAPHIC FINDINGS**

- Normal echocardiogram

**INTERPRETATION OF THE FINDINGS & FURTHER RECOMMENDATIONS**

No evidence of structural or functional cardiomyopathy was present in this study as a cause or contributing factor to the patient's coughing. No evidence of clinical issues such as LV systolic dysfunction, clinical pulmonary hypertension, significant valvular insufficiencies or stenotic disease were present. The coughing is non-cardiogenic in origin and suspected to be secondary to chronic upper or lower airway disease. No indication for cardiac medication.

**INTERPRETED BY**

 R. McKenzie Daniel,  
 DVM, DABVP  
 (Canine and Feline)

**IMAGING PERFORMED BY**

Hope Brossman

**HOSPITAL NAME**

 Animal Mansion  
 Veterinary Hospital

**REFERRING VET**

Dr. Bertoldo

**INVOICE**

12363ag

**DATE**

12/05/2022



**PATIENT**

Binx VanDunk

**SPECIES**

Canine

**BREED**

Pug Mix

**SEX**

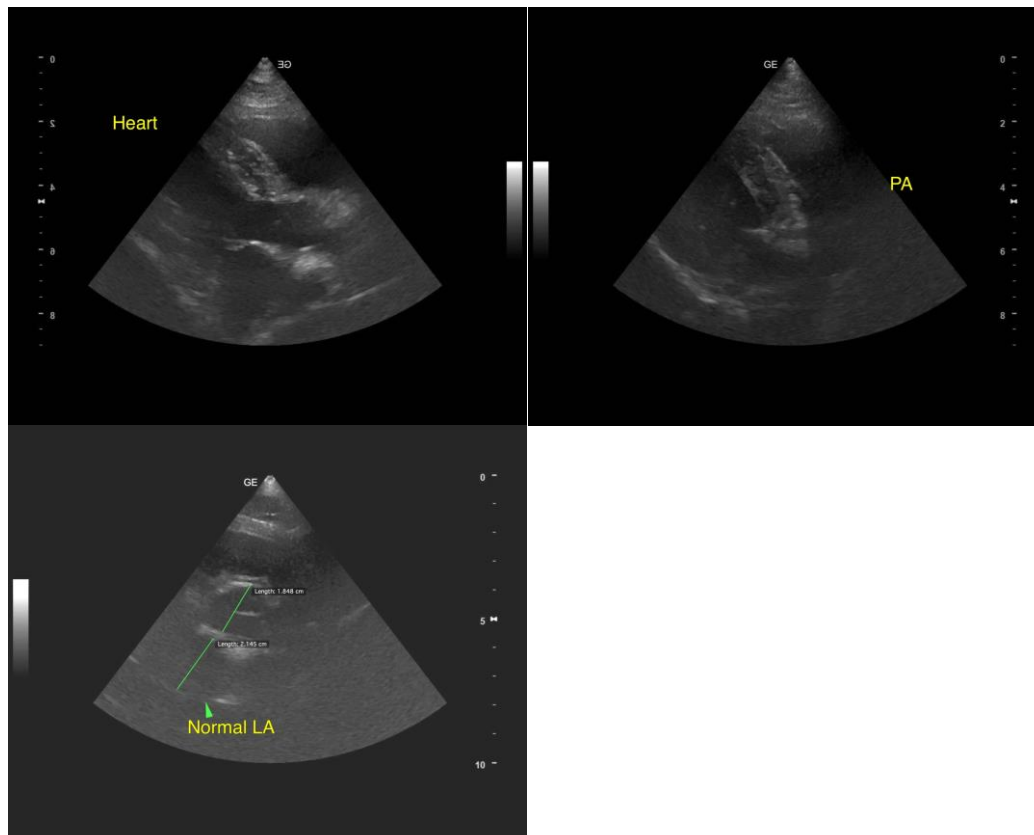
FS

**AGE**

16yr

**WEIGHT**

35



**INTERPRETED BY**

R. McKenzie Daniel,  
DVM, DABVP  
(Canine and Feline)

**IMAGING PERFORMED BY**

Hope Brossman

**HOSPITAL NAME**

Animal Mansion  
Veterinary Hospital

**REFERRING VET**

Dr. Bertoldo

**INVOICE**

12363ag

**DATE**

12/05/2022

The information and recommendations provided are based on the images presented by the referring veterinarian/sonographer. No evaluation can be communicated regarding pathology that was not visible in the image/video clips provided.

Thank you for this referral. If the clinical or image interpretation does not parallel your findings or if I can be of any further assistance, please contact me.

R. McKenzie Daniel, DVM, DABVP (Canine/Feline Practice)  
[mac.daniel@sonopath.com](mailto:mac.daniel@sonopath.com)