



PATIENT

Josie Ducker

SPECIES

Feline

BREED

Domestic Shorthair

SEX

Female (Spayed)

AGE

7 years

WEIGHT

9.5 lbs.

INTERPRETED BY

R. McKenzie Daniel,
 DVM, DABVP
 (Canine and Feline)

IMAGING PERFORMED BY

Meghan Morse, LVT,
 CVT

HOSPITAL NAME

Kingston AH

REFERRING VET

Dr. Turner

INVOICE

10417

DATE

12/4/25

PRESENTING CLINICAL SIGNS

Kidney values increased, PU/PD post dental, pet received DTK, antisedan and onsiore for dental
 Looking for insight as to cause- anesthesia reaction? acute vs CKD

Abnormal PE/Chem/CBC/UA Results: BUN 54, Creat 2.8, SDMA 16, free t4 pending, t4 2.5, USG 1.021

ULTRASONOGRAPHIC EXAMINATION OF THE ABDOMEN

Urinary System

The urinary bladder, trigone, cystourethral junction, and visible pelvic urethra to a depth of 2.0 cm exhibited normal thickness and tone. Anechoic urine was present in the lumen with no evidence of urine or lumen sediment, mineral, or calculi. The ureteral papillae were normal. The ureters were not visible which is normal. No evidence of inflammatory or neoplastic changes was noted.

No evidence of pathology in the area of the aortic trifurcation.

Normal size and margination were present in the kidneys. A normal 1:3 cortex / medulla ratio and normal corticomedullary definition were maintained. The echogenicity of the cortex was similar to or slightly less than normal liver parenchyma while the medulla echogenicity was hypoechoic to the cortex with no evidence of pelvic dilation. The left kidney measured 3.8 cm in length. The right kidney measured 3.6 cm in length.

Adrenal Glands

The left and right adrenal glands were uniform in size and contour with a uniformly hypoechoic parenchyma. The left adrenal gland measured 0.42 cm width and the right adrenal gland measured 0.32 cm width.

Spleen

The spleen exhibited a finely textured and homogenous parenchyma which was hyperechoic to the liver and renal cortical parenchyma. The capsule was smooth and regular without apparent expansion. The splenic vasculature at the hilus was normal in volume with no evidence of congestion or thrombosis. Acute to chronic inflammatory, neoplastic, or benign parenchyma changes were not noted.

Liver/ Gallbladder

The liver was subjectively normal in size, structure, and contour. The liver parenchyma was uniform and hypoechoic to the spleen with a mild coarse echotexture. The hepatic and portal vasculature were normal in appearance without signs of congestion. The gallbladder was non-distended in size with thin walls and primarily anechoic luminal content. The cystic and common bile ducts were normal.

Gastrointestinal

The stomach presented intact wall layering with a normal wall layer ratio. The lumen of the stomach was empty without evidence of retained ingesta, fluid, or foreign material.



PATIENT

Josie Ducker

SPECIES

Feline

BREED

Domestic Shorthair

SEX

Female (Spayed)

AGE

7 years

WEIGHT

9.5 lbs.

INTERPRETED BY

R. McKenzie Daniel,
DVM, DABVP
(Canine and Feline)

IMAGING PERFORMED BY

Meghan Morse, LVT,
CVT

HOSPITAL NAME

Kingston AH

REFERRING VET

Dr. Turner

INVOICE

10417

DATE

12/4/25

The small intestine presented intact wall layering with 1:3 muscularis/mucosa ratio. The lumen of the small intestine was empty with no signs of ileus, obstruction, or foreign material.

Normal visible colon wall layers were present with apparent formed feces in lumen.

Pancreas

The parenchyma of the left limb, body, and right limb of the pancreas presented isoechoic to the adjacent omental fat. A normal curvilinear capsule contour of the pancreas was present. The visible pancreatic duct was normal. No signs of active inflammation or neoplastic disease were evident.

Free Abdomen

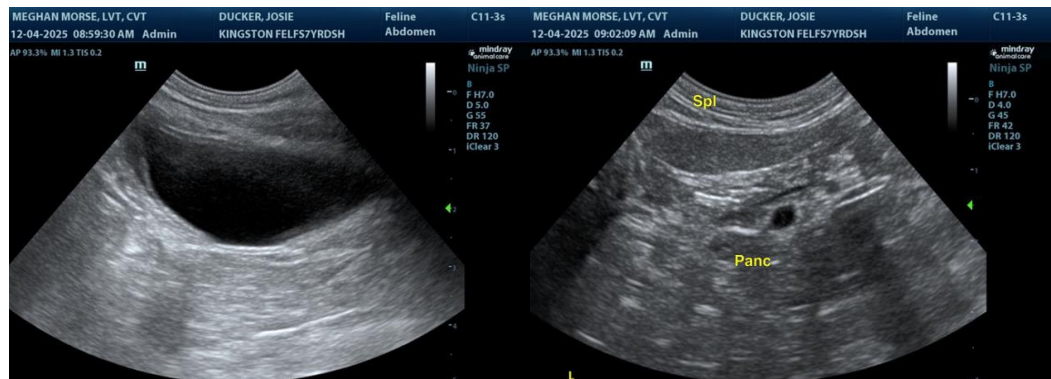
No overt lymphadenopathy or peritoneal effusion was present.

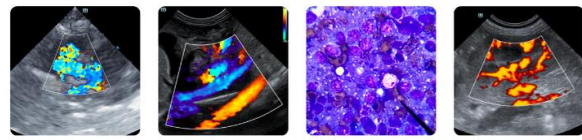
ULTRASONOGRAPHIC FINDINGS

- Sonographically unremarkable kidneys

INTERPRETATION OF THE FINDINGS & FURTHER RECOMMENDATIONS

The sonographically normal bilateral kidneys are consistent with acute renal insult or disease. Renal support with monitoring of urinalysis and consideration for baseline renal staging to include screening C/S and UPC level is recommended. Sonographic monitoring is recommended if evidence of persistent / progressive azotemia.





PATIENT

Josie Ducker

SPECIES

Feline

BREED

Domestic Shorthair

SEX

Female (Spayed)

AGE

7 years

WEIGHT

9.5 lbs.

INTERPRETED BY

R. McKenzie Daniel,
 DVM, DABVP
 (Canine and Feline)

IMAGING PERFORMED BY

Meghan Morse, LVT,
 CVT

HOSPITAL NAME

Kingston AH

REFERRING VET

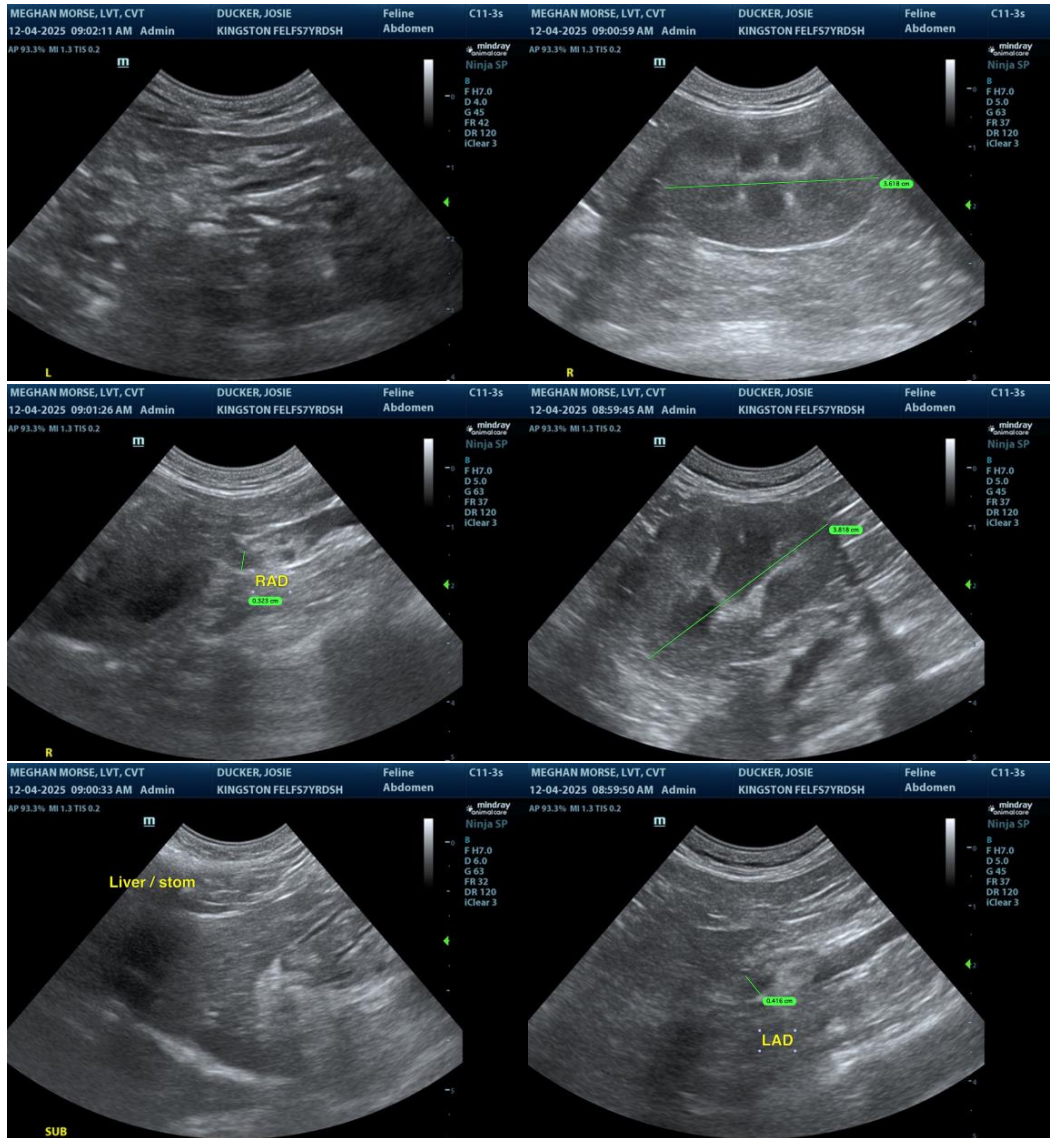
Dr. Turner

INVOICE

10417

DATE

12/4/25



The information and recommendations provided are based on the images presented by the referring veterinarian/sonographer. No evaluation can be communicated regarding pathology that was not visible in the image/video clips provided.

Thank you for this referral. If the clinical or image interpretation does not parallel your findings or if I can be of any further assistance, please contact me.

R. McKenzie Daniel, DVM, DABVP (Canine/Feline Practice)
info@sonopath.com