



PATIENT PRESENTING CLINICAL SIGNS

Bear Grippo History: High bnp

SPECIES Abnormal PE/Chem/CBC/UA Results: Elev. bnp.

Canine **ULTRASONOGRAPHIC EXAMINATION OF THE HEART**

BREED

Chihuahua

SEX

Male Neutered

AGE

9 yrs

WEIGHT

6.5 lbs

INTERPRETED BY

R. McKenzie Daniel,
 DVM, DABVP
 (Canine and Feline)

CANINE CARDIAC PARAMETERS	MR VMAX (m/s)	TR VMAX (m/s)	LA/AO (M-Mode)	LA/AO (Heart Base; Swe)	FS (%)	EF (%)	EPSS (cm)
NORMAL PARAMETER	4.5-5.5	<2.7	1.3	Up to 1.6	28-40	40-100	<0.6
PATIENT	--	--	--	1.3	43	77	0.1
CANINE CARDIAC PARAMETERS	HR (BPM)	AV VMAX (m/s)	PV MAX (m/s)	BODY WEIGHT (kg)	LAD LA MAX 4 Chamber	LVIDd Avg; 2D and m-mode short axis (cm)	LVIDs Avg; 2D and m-mode short axis (cm)
NORMAL PARAMETER	50-100	0.7-1.7	0.7-1.6				
PATIENT	143	1.0	1.0	--	1.6	1.64	--

Cardiac Presentation

The echocardiogram in this patient demonstrated normal **left atrial** size based on 2 separate methods of LA evaluation. The cranial and caudal **mitral** valve leaflets presented normal linear structure, extension in systole, and union in diastole with normal kinesis. The **left ventricle** presented thicknesses with linear contour and was not dilated nor restricted. The **myocardium** presented normal echogenicity without subjective evidence of significant fibrotic or ischemic disease. **Contractility** of the ventricular walls was adequate and in normal range for this patient evidenced by the fractional shortening measurement and subjective evaluation of the different regions of the myocardium. The **left ventricular outflow** tract demonstrated normal laminar flow and subjective structural integrity. The **right atrium** and auricle revealed normal size, structure and content. No evidence of masses was noted. **Tricuspid** valvular assessment demonstrated adequate linear morphology and kinesis. The **right ventricle** was of normal size (1/3 diameter of LV), chordae structure, myocardial echogenicity and thickness. **Pulmonary outflow** tract assessment revealed normal valve structure, laminar flow, and diameter (approx.1:1 pa/ao ratio). No visible **pericardial** or free pleura fluid was noted. The cranial **mediastinum and pericardial and extra-cardiac regions** were free of masses in the visible window.

DATE ULTRASONOGRAPHIC FINDINGS

- Normal echocardiogram

IMAGING PERFORMED BY

Kerri Becker

HOSPITAL NAME

Loving Care VH

REFERRING VET

Dr. Steele

INVOICE

12889

DATE

12/4/25



PATIENT

Bear Grippo

SPECIES

Canine

BREED

Chihuahua

SEX

Male Neutered

AGE

9 yrs

WEIGHT

6.5 lbs

INTERPRETED BY

R. McKenzie Daniel, DVM, DABVP
(Canine and Feline)

IMAGING PERFORMED BY

Kerri Becker

HOSPITAL NAME

Loving Care VH

REFERRING VET

Dr. Steele

INVOICE

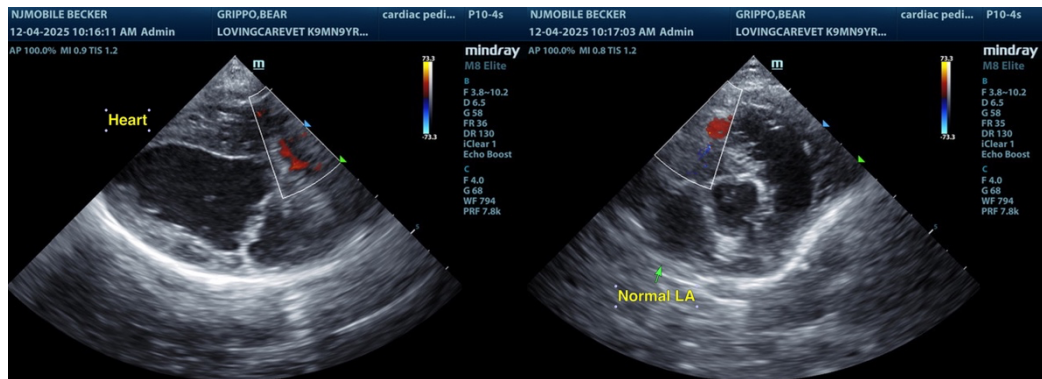
12889

DATE

12/4/25

INTERPRETATION OF THE FINDINGS & FURTHER RECOMMENDATIONS

No evidence of structural or functional cardiomyopathy present.



The information and recommendations provided are based on the images presented by the referring veterinarian/sonographer. No evaluation can be communicated regarding pathology that was not visible in the image/video clips provided.

Thank you for this referral. If the clinical or image interpretation does not parallel your findings or if I can be of any further assistance, please contact me.

R. McKenzie Daniel, DVM, DABVP (Canine / Feline Practice)

info@sonopath.com