



PATIENT

Cali Tampan

SPECIES

Feline

BREED

DSH

SEX

Spayed Female

AGE

11 Years

WEIGHT

11.1 pounds

INTERPRETED BY

R. McKenzie Daniel,
DVM, DABVP (Canine
/ Feline Practice)

IMAGING PERFORMED BY

Kerri Becker

HOSPITAL NAME

Animal Paradise
Hospital

REFERRING VET

Dr. Elshafie

INVOICE

12900

DATE

12/31/25

PRESENTING CLINICAL SIGNS

Assess heart prior to SX. Widened base of heart- a cardiomyopathy such as hypertrophic cardiomyopathy is possible.

ULTRASONOGRAPHIC EXAMINATION OF THE HEART

FELINE CARDIAC PARAMETERS	BODY WEIGHT (kg)	HR (BPM)	IVSd (cm)	LVIDd (cm)	LVWd (cm)	FS (%)	EF (%)
NORMAL PARAMETER	-----	150-240	0.3-0.6	1.0-2.1	0.25-0.6	35-67	80-100
PATIENT	--	NM	0.4	1.4	0.44	52	85
FELINE CARDIAC PARAMETERS	LA/AO (M-mode)	LA/AO HEART BASE (Sisson)	LAD LA MAX 4 Chamber	LVOT VEL. (m/s)	RVOT VEL. (m/s)	IVRT (m/)	
NORMAL PARAMETER	<1.5	1.6	0.7-1.7	<1.6	<1.3	40-60	
PATIENT	1.4	1.44	1.45	1.0	0.9	NM	
Adapted from June Boon, Veterinary Echocardiography, 1998 Sisson D et al. JVIM 1991; 5: 232, Jacobs et al. Am J Vet Res 1985; 46:1705							

Cardiac Presentation

The echocardiogram in this patient demonstrated normal **left atrial** size based on 3 separate LA measurements. The cranial and caudal **mitral** valve leaflets presented normal linear structure and kinetics. The **left ventricle** presented normal thicknesses with linear contour and was not dilated nor restricted. The **myocardium** presented normal echogenicity without subjective evidence of significant fibrotic or ischemic disease. **Contractility** of the ventricular walls was adequate and in normal range for this patient evidenced by the fractional shortening measurement and subjective evaluation of the different regions and angles of the myocardium. The **left ventricular outflow** tract demonstrated normal laminar flow and subjective structural integrity. The **right atrium** and auricle revealed normal size, structure and content. No evidence of masses was noted or chamber overload. **Tricuspid** valvular assessment demonstrated adequate linear morphology and kinetics. The **right ventricle** was of normal size (1/3 diameter of LV), chordae structure, myocardial echogenicity and thickness. **Pulmonic** tract assessment revealed normal valve structure, laminar flow, and diameter (approx. 1:1 pa/ao ratio). No visible **pericardial** or free pleura fluid was noted or extra cardiac pathology in the visible planes. The cranial **mediastinum** and **pericardial** regions were free of masses in the visible window.

ULTRASONOGRAPHIC FINDINGS

- Normal echocardiogram.

INTERPRETATION OF THE FINDINGS & FURTHER RECOMMENDATIONS

No evidence of clinical issues such as left or right heart chamber enlargement, HCM criteria or other



PATIENT

Cali Tampan

SPECIES

Feline

BREED

DSH

SEX

Spayed Female

AGE

11 Years

WEIGHT

11.1 pounds

INTERPRETED BY

R. McKenzie Daniel,
 DVM, DABVP (Canine
 / Feline Practice)

IMAGING PERFORMED BY

Kerri Becker

HOSPITAL NAME

Animal Paradise
 Hospital

REFERRING VET

Dr. Elshafie

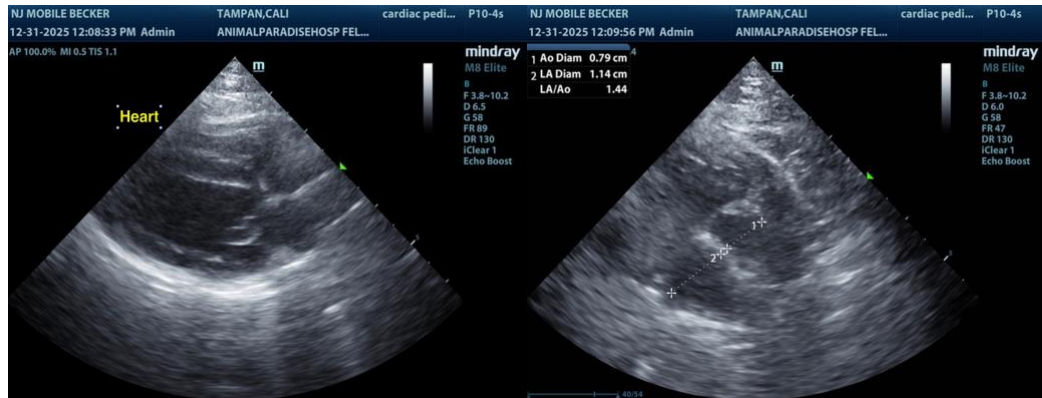
INVOICE

12900

DATE

12/31/25

cardiomyopathy. No anesthetic contraindications. Suggested anesthetic protocol may include opioid or Benzodiazepine pre-med, induction with Propofol or Alfaxalone, and appropriate gas anesthesia with avoidance of alpha 2 agonists.



The information and recommendations provided are based on the images presented by the referring veterinarian/sonographer. No evaluation can be communicated regarding pathology that was not visible in the image/video clips provided.

Thank you for this referral. If the clinical or image interpretation does not parallel your findings or if I can be of any further assistance, please contact me.

R. McKenzie Daniel, DVM, DABVP (Canine / Feline Practice)

info@SonoPath.com