

PATIENT

Cali Dosch

SPECIES

Feline

BREED

DSH

SEX

Female Spayed

AGE

7

WEIGHT

9

INTERPRETED BY

R. McKenzie Daniel,
DVM, DABVP
(Canine and Feline)

IMAGING PERFORMED BY

Jenn

HOSPITAL NAME

Rockaway AH

REFERRING VET

Dr. Maniar

INVOICE

13003

DATE

12/31/25

PRESENTING CLINICAL SIGNS

History: re check from yesterday

ULTRASONOGRAPHIC EXAMINATION OF THE ABDOMEN

Urinary System

The urinary bladder, trigone, cystourethral junction, and visible pelvic urethra to a depth of 2.0 cm exhibited normal thickness and tone. Primarily anechoic urine was present in the lumen. Non-dependent, echogenic to particulate sediment was present without evidence of calculus formation. The ureteral papillae were normal. The ureters were not visible which is normal. No evidence of inflammatory or neoplastic mural changes were noted.

The area of the aortic trifurcation was free of pathology.

Borderline subnormal size was present in the kidneys. A normal 1:3 cortex / medulla ratio and normal corticomedullary definition were maintained. The echogenicity of the cortex was similar to or slightly less than normal liver parenchyma while the medulla echogenicity was hypoechoic to the cortex with no evidence of pelvic dilation. The left kidney measured 3.2 cm in length. The right kidney measured 3.2 cm in length.

Adrenal Glands

No obvious pathology in the area of the left and right adrenal glands.

Spleen

The spleen exhibited a finely textured and homogenous parenchyma which was hyperechoic to the liver and renal cortical parenchyma. The capsule was smooth and regular without apparent expansion. The splenic vasculature at the hilus was normal in volume with no evidence of congestion or thrombosis. Acute to chronic inflammatory, neoplastic, or benign parenchyma changes were not noted.

Liver

The liver was subjectively normal in size, structure, and contour. The liver parenchyma was uniform and hypoechoic to the spleen with a mild coarse echotexture. The hepatic and portal vasculature were normal in appearance without signs of congestion. The gallbladder was non-distended in size with thin walls and primarily anechoic luminal content. The cystic and common bile ducts were normal.

Gastrointestinal

The stomach presented intact wall layering with a normal wall layer ratio. The lumen of the stomach was empty with no evidence of persistent retained ingesta or possible pyloric hairball type density.

The small intestine presented intact wall layering with 1:3 muscularis/mucosa ratio. The lumen of the small intestine was empty with no signs of ileus, obstruction or foreign material.

Normal visible colon wall layers were present with apparent formed feces in lumen.



PATIENT

Pancreas

Cali Dosch

The area of the pancreas was sonographically normal.

SPECIES

Free Abdomen

Feline

No overt lymphadenopathy or peritoneal effusion was present.

BREED

PRIMARY FINDINGS

DSH

- Normal empty gastrointestinal tract
- Normal area of pancreas

SEX

SECONDARY FINDINGS

Female Spayed

- Borderline subnormal bilateral renal size
- Static urine sediment

AGE

INTERPRETATION OF THE FINDINGS & FURTHER RECOMMENDATIONS

7

No evidence of gastrointestinal obstructive pattern or previously noted pyloric hairball density. Gastrointestinal support indicated. Urine C/S suggested if inflammatory sediment on urinalysis.

WEIGHT

9

INTERPRETED BY

R. McKenzie Daniel,
DVM, DABVP
(Canine and Feline)

IMAGING PERFORMED BY

Jenn

HOSPITAL NAME

Rockaway AH

REFERRING VET

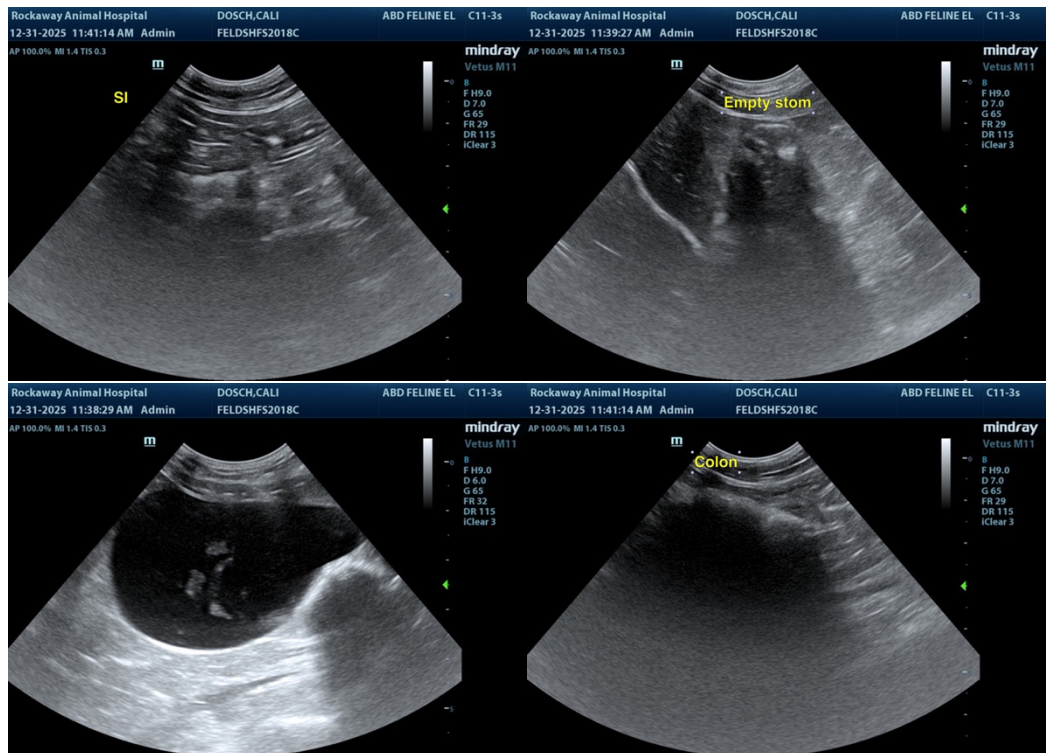
Dr. Maniar

INVOICE

13003

DATE

12/31/25





PATIENT

Cali Dosch

SPECIES

Feline

BREED

DSH

SEX

Female Spayed

AGE

7

WEIGHT

9

INTERPRETED BY

R. McKenzie Daniel,
DVM, DABVP
(Canine and Feline)

IMAGING PERFORMED BY

Jenn

HOSPITAL NAME

Rockaway AH

REFERRING VET

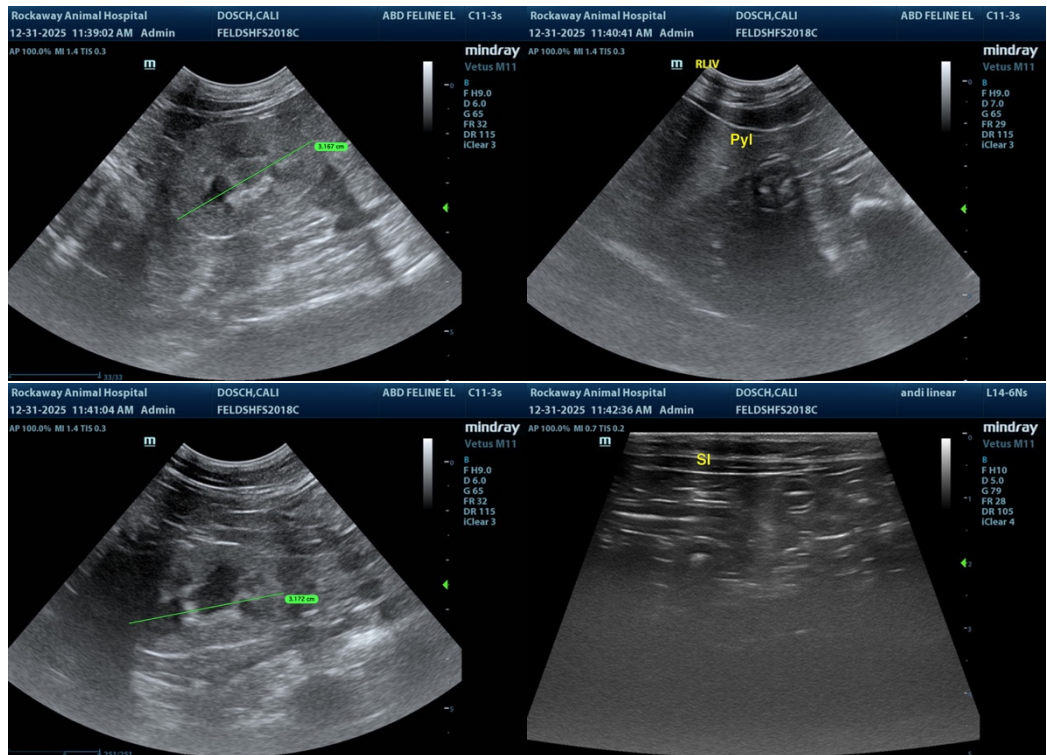
Dr. Maniar

INVOICE

13003

DATE

12/31/25



The information and recommendations provided are based on the images presented by the referring veterinarian/sonographer. No evaluation can be communicated regarding pathology that was not visible in the image/video clips provided.

Thank you for this referral. If the clinical or image interpretation does not parallel your findings or if I can be of any further assistance, please contact me.

R. McKenzie Daniel, DVM, DABVP (Canine / Feline Practice)

info@sonopath.com