



PATIENT

Tillie Barclay

SPECIES

Canine

BREED

Dachshund Mix

SEX

Spayed Female

AGE

13 Years

WEIGHT

Not Provided

INTERPRETED BY

R. McKenzie Daniel,
DVM, DABVP (Canine
/ Feline Practice)

IMAGING PERFORMED BY

Meghan Morse, LVT,
CVT

HOSPITAL NAME

New Bridge Veterinary
Hospital

REFERRING VET

Dr. Glennon

INVOICE

12888

DATE

12/30/25

PRESENTING CLINICAL SIGNS

Echo- chronic cough, cardiomegaly abd- concern for possible Cushing's dz, hepatomegaly?

Abnormal PE/Chem/CBC/UA Results: Increased ALKP U/A: 2+ protein, USG 1.034

ULTRASONOGRAPHIC EXAMINATION OF THE HEART & ABDOMEN

CANINE CARDIAC PARAMETERS	MR VMAX (m/s)	TR VMAX (m/s)	LA/AO (M-Mode)	LA/AO (Heart Base; Swe)	FS (%)	EF (%)	EPSS (cm)
NORMAL PARAMETER	4.5-5.5	<2.7	1.3	Up to 1.6	28-40	40-100	<0.6
PATIENT	--	--	NM	1.25	39	72	0.26
CANINE CARDIAC PARAMETERS	HR (BPM)	AV VMAX (m/s)	PV MAX (m/s)	BODY WEIGHT (kg)	LAD LA MAX 4 Chamber	LVIDd Avg; 2D and m-mode short axis (cm)	LVIDs Avg; 2D and m-mode short axis (cm)
NORMAL PARAMETER	50-100	0.7-1.7	0.7-1.6				
PATIENT	NM	1.5	1.0	--	3.3	3.2	--

Cardiac Presentation

The echocardiogram in this patient demonstrated normal **left atrial** size based on 2 different LA measurement methods. Chamber volumes and echogenicity were normal. The cranial and caudal **mitral** valve leaflets presented mild thickening consistent with mild endocardiosis. Doppler revealed subjective mild indistinct eccentric MR. The **left ventricle** presented thicknesses with linear contour and was not dilated nor restricted. The **myocardium** presented normal echogenicity without subjective evidence of significant fibrotic or ischemic disease. **Contractility** of the ventricular walls was adequate and in normal range for this patient evidenced by the fractional shortening measurement and subjective evaluation of the different regions of the myocardium. The **left ventricular outflow** tract demonstrated normal laminar flow and subjective structural integrity. The **right atrium** and auricle revealed normal size, structure and content. No evidence of masses was noted or chamber overload. **Tricuspid** valvular assessment demonstrated adequate linear morphology. The **right ventricle** was of normal size (1/3 diameter of LV), chordae structure, myocardial echogenicity and thickness. **Pulmonic** tract assessment revealed normal valve structure, laminar flow, and diameter (approx.1:1 pa/ao ratio). No visible **pericardial** or free pleura fluid was noted. No echographically detectable evidence of cardiac / pericardial tumors was visible.

Urinary System

The urinary bladder, trigone, cystourethral junction, and visible pelvic urethra to a depth of 4.0 cm exhibited normal thickness and tone. Anechoic urine was present in the lumen with no uroliths or



PATIENT

Tillie Barclay

SPECIES

Canine

BREED

Dachshund Mix

SEX

Spayed Female

AGE

13 Years

WEIGHT

Not Provided

INTERPRETED BY

R. McKenzie Daniel,
DVM, DABVP (Canine
/ Feline Practice)

IMAGING PERFORMED BY

Meghan Morse, LVT,
CVT

HOSPITAL NAME

New Bridge Veterinary
Hospital

REFERRING VET

Dr. Glennon

INVOICE

12888

DATE

12/30/25

sediment. The ureteral papillae were normal. The ureters were not visible which is normal. No evidence of inflammatory or neoplastic change were noted.

The area of the aortic trifurcation was free of pathology.

Normal size and margination was present in the kidneys. A normal 1:3 cortex / medulla ratio was maintained. The medulla and cortices were uniform in texture with some increased echogenicity and mild loss of corticomedullary symmetry and definition expected for the age of the patient. No evidence of pelvic dilation was present. The left kidney measured 5.2 cm in length. The right kidney measured 5.7 cm in length.

Adrenal Glands

The left adrenal gland was uniform in size and contour with a uniformly hypoechoic parenchyma. The left adrenal gland measured 0.58 cm width at the caudal pole. The right adrenal gland was uniform in size and contour with a uniformly hypoechoic parenchyma. The right adrenal gland measured 0.57 cm width at the caudal pole.

Spleen

The spleen exhibited a finely textured and homogenous parenchyma which was hyperechoic to the liver and renal cortical parenchyma. The capsule was smooth and regular without apparent expansion. The splenic vasculature at the hilus was normal in volume with no evidence of congestion or thrombosis. Acute to chronic inflammatory, neoplastic, or benign parenchyma changes were not noted.

Liver

The liver presented enlarged in size. The parenchyma of the liver was subjectively normal in echogenicity compared to the spleen and renal cortices. The liver parenchyma was uniform with a mildly coarse echotexture. The capsule of the liver was symmetrically rounded to mildly swollen in margination. The hepatic and portal vasculature were normal in appearance without signs of congestion.

The gallbladder was non distended in size with minor nonorganized biliary sludge. The cystic duct and common bile ducts were normal without evidence of dilation.

Gastrointestinal

The stomach presented intact wall layering with a normal wall layer ratio. The lumen of the stomach was empty with no signs of ileus, obstruction or foreign material.

The small intestine presented intact wall layering with 1:3 muscularis/mucosa ratio. The lumen of the small intestine was empty with no signs of ileus, obstruction or foreign material.

Normal visible colon wall layers were present with apparent formed feces in lumen.

Pancreas

The parenchyma of the left limb, body and right limb of the pancreas presented isoechoic to the adjacent omental fat. A normal curvilinear capsule contour of the pancreas was present. The visible pancreatic duct was normal. No signs of active inflammation or neoplastic disease was evident.



PATIENT

Free Abdomen

Tillie Barclay

No overt lymphadenopathy or peritoneal effusion was present.

SPECIES

Canine

ULTRASONOGRAPHIC FINDINGS

- Normal cardiac structure/function.
- Indistinct compensated MR (B1).
- Benign hepatopathy.
- Minor gallbladder debris (non-mucocele).
- Age-related renal changes.
- Normal bilateral adrenal glands.

BREED

Dachshund Mix

INTERPRETATION OF THE FINDINGS & FURTHER RECOMMENDATIONS

SEX

Spayed Female

No evidence of cardiac clinical issues such as left or right heart chamber enlargement, LV systolic dysfunction or clinical pulmonary hypertension as an obvious contributing factor to the cough. The coughing in this patient is noncardiogenic in origin. The lack of LA enlargement indicates the current and future risk on complications, secondary to indistinct MR, is low. No indication for cardiac medications.

AGE

13 Years

WEIGHT

Not Provided

The hepatopathy is suggestive of nonspecific or idiopathic vacuolar hepatopathy criteria or possible mild cholestasis. No overt adrenal pathology as a contributing factor in conjunction with urine specific gravity greater than 1020. If suspicion for Cushing's syndrome, adrenal screening may be considered. Hepatosupportive medications may prove beneficial. UPC level on sterile urine sample is suggested if persistent proteinuria.

INTERPRETED BY

R. McKenzie Daniel,
 DVM, DABVP (Canine
 / Feline Practice)

IMAGING PERFORMED BY

Meghan Morse, LVT,
 CVT

HOSPITAL NAME

New Bridge Veterinary
 Hospital

REFERRING VET

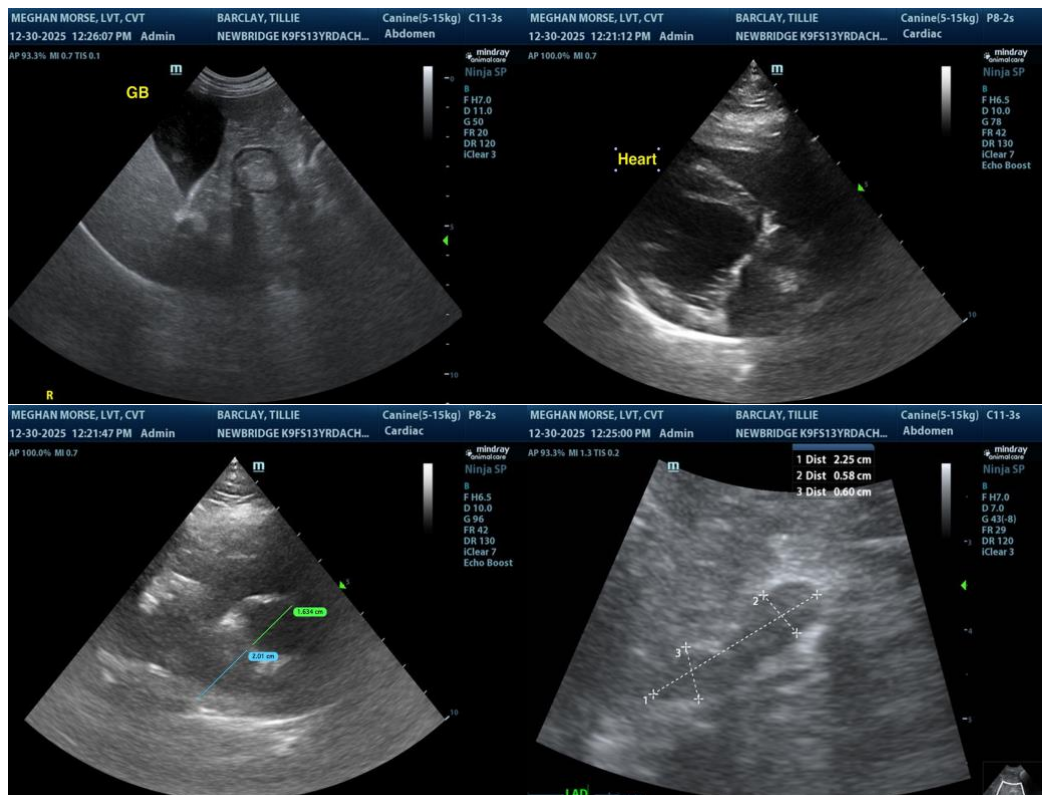
Dr. Glennon

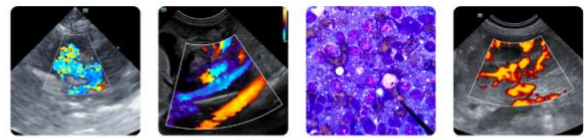
INVOICE

12888

DATE

12/30/25





PATIENT

Tillie Barclay

SPECIES

Canine

BREED

Dachshund Mix

SEX

Spayed Female

AGE

13 Years

WEIGHT

Not Provided

INTERPRETED BY

R. McKenzie Daniel, DVM, DABVP (Canine / Feline Practice)

IMAGING PERFORMED BY

Meghan Morse, LVT, CVT

HOSPITAL NAME

New Bridge Veterinary Hospital

REFERRING VET

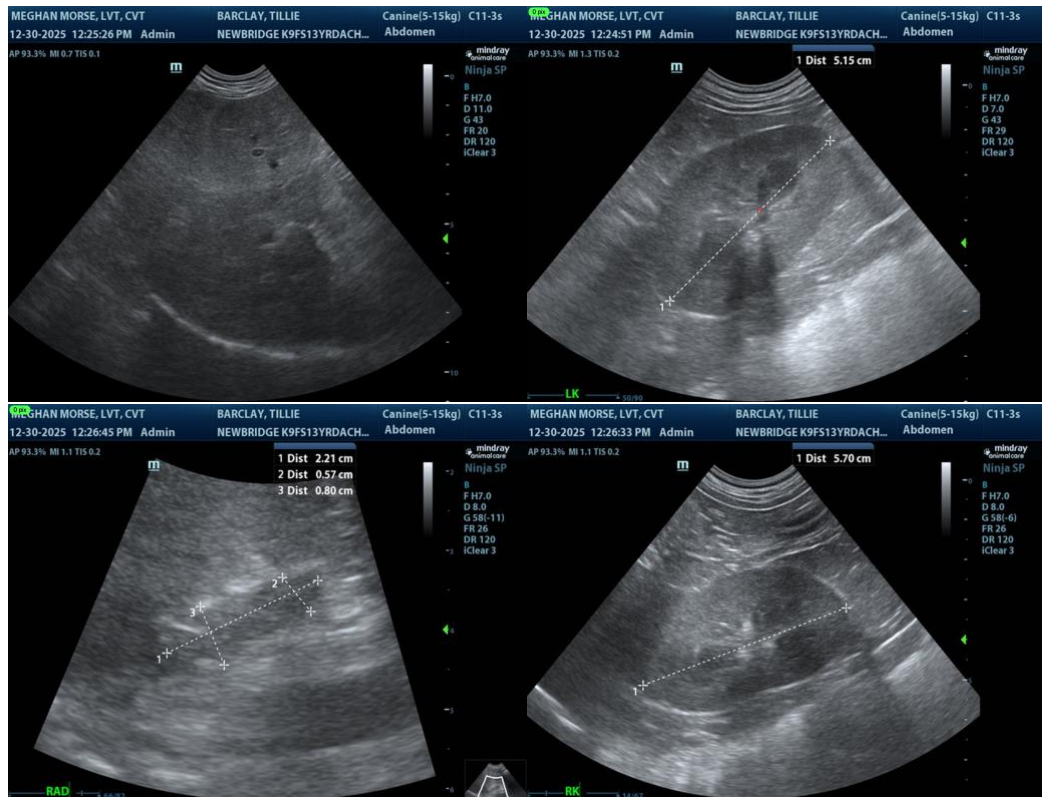
Dr. Glennon

INVOICE

12888

DATE

12/30/25



The information and recommendations provided are based on the images presented by the referring veterinarian/sonographer. No evaluation can be communicated regarding pathology that was not visible in the image/video clips provided.

Thank you for this referral. If the clinical or image interpretation does not parallel your findings or if I can be of any further assistance, please contact me.

R. McKenzie Daniel, DVM, DABVP (Canine / Feline Practice)

info@SonoPath.com