



PATIENT

Ozzie Mazzetti

SPECIES

Feline

BREED

DLH

SEX

Neutered Male

AGE

15 Years

WEIGHT

9.4 pounds

INTERPRETED BY

R. McKenzie Daniel,
DVM, DABVP

IMAGING PERFORMED BY

Dr. Sheldon

HOSPITAL NAME

Advanced PetCare of
Oakland

REFERRING VET

Dr. Sopoliga

INVOICE

12893

DATE

12/30/25

PRESENTING CLINICAL SIGNS

Chronic intermittent diarrhea and vomiting with recent progression in frequency. Ozzie has also lost weight and has an increased appetite. Chronic history of hematuria. On hydrolyzed/urinary diet. A heart murmur and arrhythmia were detected today on exam. Labwork revealed low K 2.8, hi glucose 210, glucosuria 300, hematuria >50 RBC/hpf. Radiographs revealed enlarged left kidney.

ULTRASONOGRAPHIC EXAMINATION OF THE ABDOMEN

Urinary System

The urinary bladder, trigone, cystourethral junction, and visible pelvic urethra to a depth of 2.0 cm exhibited normal thickness and tone. Anechoic urine was present in the lumen with no uroliths or sediment. The ureteral papillae were normal. The ureters were not visible which is normal. No evidence of inflammatory or neoplastic change were noted.

The area of the aortic trifurcation was free of pathology.

The left kidney was mildly enlarged with asymmetrical margination while the right kidney was normal in size. Mild indistinct corticomedullary ratio with variable echogenic corticomedullary echogenicity and loss of corticomedullary border demarcation. Mild pyelectasia was present bilaterally. The left kidney measured 4.9 cm in length. The right kidney measured 4.3 cm in length. An indistinct nonhomogenous anechoic to hypoechoic cranial left kidney noncapsule deforming nodule or cyst was present in the left kidney measuring 1.2 cm diameter.

Adrenal Glands

The left adrenal gland was uniform in size and contour with a uniformly hypoechoic parenchyma. The left adrenal gland measured 0.34 cm width. The right adrenal gland was uniform in size and contour with a uniformly hypoechoic parenchyma. The right adrenal gland measured 0.36 cm width.

Spleen

The spleen exhibited primarily finely textured parenchyma which was hyperechoic to the liver and renal cortical parenchyma. Mild generalized parenchyma heterogeneity was present without evidence of nodular changes. The capsule was smooth and regular without apparent expansion. The splenic vasculature at the hilus was normal in volume with no evidence of congestion or thrombosis. The parenchymal heterogeneity is likely consistent with benign changes such as extramedullary hematopoiesis or age-related remodeling with minor potential for inflammatory or neoplastic disease. The spleen measured 0.67 cm width level of the mid spleen.

Liver

The liver was subjectively normal in size, structure, and contour. The liver parenchyma was uniform and hypoechoic to the spleen with a mild coarse echotexture. The hepatic and portal vasculature were normal in appearance without signs of congestion. The gallbladder was non-distended in size with thin walls and primarily anechoic luminal content. The cystic and common bile ducts were normal.

Gastrointestinal

The stomach presented intact wall layering with a normal wall layer ratio. Possible nonobstructive hairball type density in the area of the mid gastric body or pylorus measuring approximately 1.7 cm in diameter.



PATIENT

Ozzie Mazzetti

The small intestine presented intact wall layering with 1:3 muscularis/mucosa ratio. The lumen of the small intestine was empty with no signs of ileus, obstruction or foreign material. Small intestine wall measured 0.23 cm wall width.

SPECIES

Feline

Normal visible colon wall layers were present with current semi formed fecal matter in lumen.

Pancreas

BREED

DLH

The area of the pancreas was sonographically normal.

Free Abdomen

SEX

Neutered Male

No peritoneal effusion was present.

Intermittent mildly prominent colic lymph nodes were present. The lymph nodes were essentially isoechoic to adjacent omentum without evidence of peripheral inflammation and maintaining a normal width: length ratio (<0.5). An example measured 1.1 cm in diameter.

AGE

15 Years

ULTRASONOGRAPHIC FINDINGS

WEIGHT

9.4 pounds

- Bilateral chronic renal changes, mild left renomegaly with indistinct left kidney cyst versus nodule.
- Possible nonobstructive gastropyloric hairball type density.
- Sonographically unremarkable small intestine and colon with current semi formed fecal matter.
- Normal area of the pancreas.
- Normal bilateral adrenal glands.
- Sonographically unremarkable urinary bladder.

INTERPRETED BY

R. McKenzie Daniel,
DVM, DABVP

INTERPRETATION OF THE FINDINGS & FURTHER RECOMMENDATIONS

Urine culture and sensitivity on sterile urine sample is recommended. Given glucosuria, concurrent fructosamine level if clinically indicated may be considered. No definitive evidence of renal neoplastic criteria although sonographic monitoring of the left kidney for evidence of progressive renomegaly or progressive cyst versus nodule is indicated. Underlying gastrointestinal disease or mild pancreatitis may present sonographically normal. A GI panel to include PLI, TLI, cobalamin and folate and if not recently done, three view chest radiographs to assess for nonstructural occult disease is recommended.

IMAGING PERFORMED BY

Dr. Sheldon

HOSPITAL NAME

Advanced PetCare of
Oakland

REFERRING VET

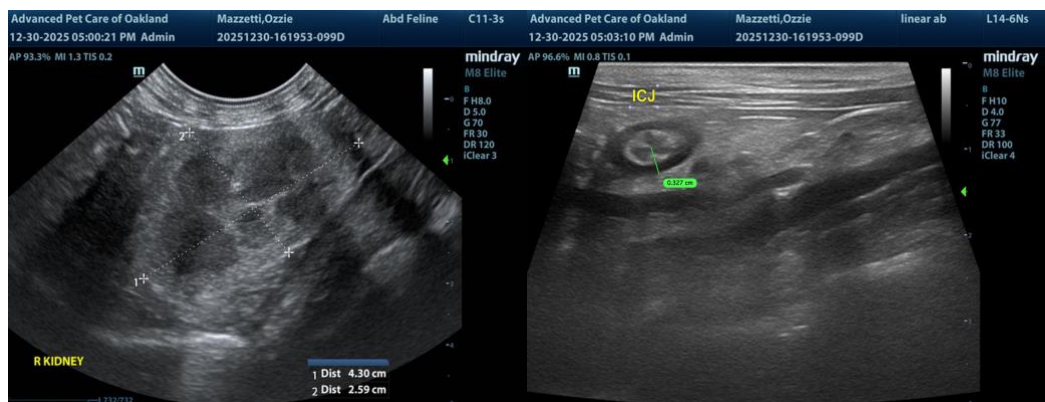
Dr. Sopoliga

INVOICE

12893

DATE

12/30/25





PATIENT

Ozzie Mazzetti

SPECIES

Feline

BREED

DLH

SEX

Neutered Male

AGE

15 Years

WEIGHT

9.4 pounds

INTERPRETED BY

R. McKenzie Daniel,
DVM, DABVP

IMAGING PERFORMED BY

Dr. Sheldon

HOSPITAL NAME

Advanced PetCare of
Oakland

REFERRING VET

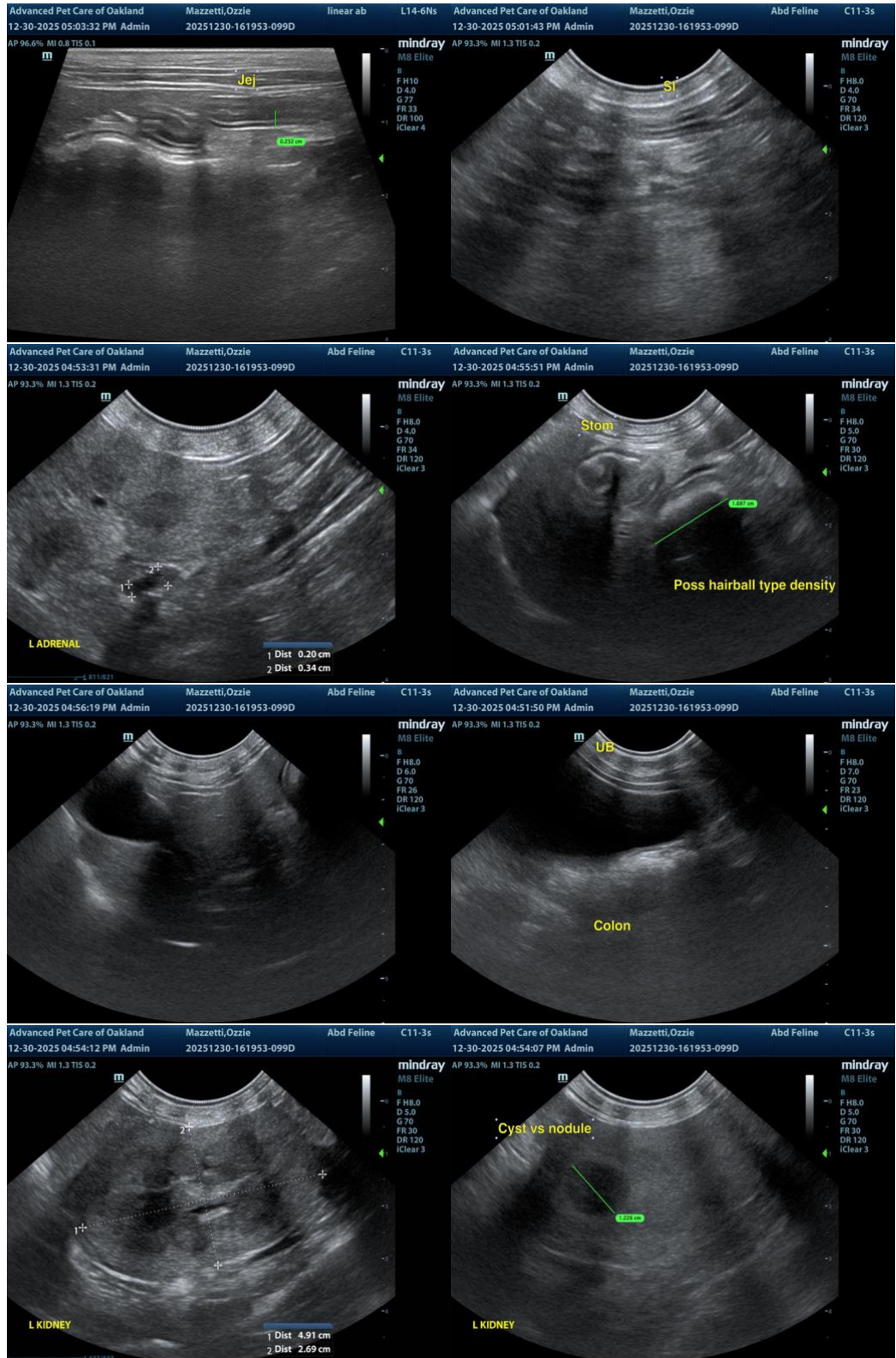
Dr. Sopoliga

INVOICE

12893

DATE

12/30/25





PATIENT

Ozzie Mazzetti

SPECIES

Feline

BREED

DLH

SEX

Neutered Male

AGE

15 Years

WEIGHT

9.4 pounds

INTERPRETED BY

R. McKenzie Daniel,
DVM, DABVP

IMAGING PERFORMED BY

Dr. Sheldon

HOSPITAL NAME

Advanced PetCare of
Oakland

REFERRING VET

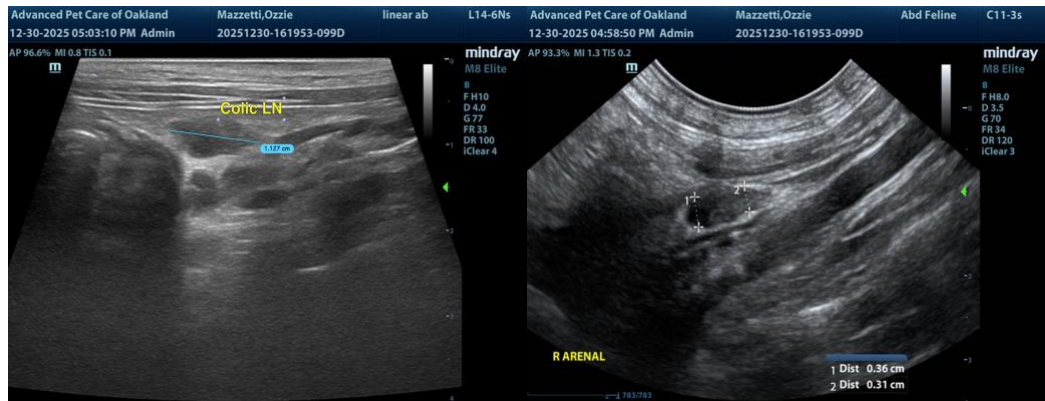
Dr. Sopoliga

INVOICE

12893

DATE

12/30/25



The information and recommendations provided are based on the images presented by the referring veterinarian/sonographer. No evaluation can be communicated regarding pathology that was not visible in the image/video clips provided.

Thank you for this referral. If the clinical or image interpretation does not parallel your findings or if I can be of any further assistance, please contact me.

R. McKenzie Daniel, DVM, DABVP (Canine / Feline Practice)

info@SonoPath.com