



PATIENT

Holly Adams

SPECIES

Canine

BREED

Golden Retriever

SEX

Spayed Female

AGE

12 Years 2 Months

WEIGHT

93 pounds

INTERPRETED BY

R. McKenzie Daniel,
DVM, DABVP (Canine
/ Feline Practice)

IMAGING PERFORMED BY

Kerri Becker

HOSPITAL NAME

Marsh Animal Hospital

REFERRING VET

Dr. Armani

INVOICE

12886

DATE

12/30/25

PRESENTING CLINICAL SIGNS

5-6 cm firm mass left causal ventral thorax new finding. Cytology pending.

ULTRASONOGRAPHIC EXAMINATION OF THE HEART & ABDOMEN

CANINE CARDIAC PARAMETERS	MR VMAX (m/s)	TR VMAX (m/s)	LA/AO (M-Mode)	LA/AO (Heart Base; Swe)	FS (%)	EF (%)	EPSS (cm)
NORMAL PARAMETER	4.5-5.5	<2.7	1.3	Up to 1.6	28-40	40-100	<0.6
PATIENT	--	--	NM	1.3	40	74	0.3
CANINE CARDIAC PARAMETERS	HR (BPM)	AV VMAX (m/s)	PV MAX (m/s)	BODY WEIGHT (kg)	LAD LA MAX 4 Chamber	LVIDd Avg; 2D and m-mode short axis (cm)	LVIDs Avg; 2D and m-mode short axis (cm)
NORMAL PARAMETER	50-100	0.7-1.7	0.7-1.6				
PATIENT	NM	1.5	1.0	--	3.7	3.9	--

Cardiac Presentation

The echocardiogram in this patient demonstrated normal **left atrial** dimension based on 2 separate methods of LA evaluation. The cranial and caudal **mitral** valve leaflets presented normal linear structure, extension in systole, and union in diastole with normal kinesis. The **left ventricle** presented thicknesses with linear contour and was not dilated nor restricted. The **myocardium** presented normal echogenicity without subjective evidence of significant fibrotic or ischemic disease. **Contractility** of the ventricular walls was adequate and in normal range for this patient evidenced by the fractional shortening measurement and subjective evaluation of the different regions of the myocardium. The **left ventricular outflow** tract demonstrated normal laminar flow and subjective structural integrity. The **right atrium** and auricle revealed normal size, structure and content. No evidence of masses was noted. **Tricuspid** valvular assessment demonstrated adequate linear morphology and kinesis. The **right ventricle** was of normal size (1/3 diameter of LV), chordae structure, myocardial echogenicity and thickness. **Pulmonary outflow** tract assessment revealed normal valve structure, laminar flow, and diameter (approx.1:1 pa/ao ratio). No visible **pericardial** or free pleura fluid was noted. The cranial **mediastinum and pericardial and extra-cardiac** regions were free of masses in the visible window.

Urinary System

The urinary bladder, trigone, cystourethral junction, and visible pelvic urethra to a depth of 3.0 cm exhibited normal thickness and tone. Anechoic urine was present in the lumen with no uroliths or sediment. The ureteral papillae were normal. The ureters were not visible which is normal. No evidence of inflammatory or neoplastic change were noted.

The area of the aortic trifurcation was free of pathology.



PATIENT

Holly Adams

SPECIES

Canine

BREED

Golden Retriever

SEX

Spayed Female

AGE

12 Years 2 Months

WEIGHT

93 pounds

INTERPRETED BY

R. McKenzie Daniel,
 DVM, DABVP (Canine
 / Feline Practice)

IMAGING PERFORMED BY

Kerri Becker

HOSPITAL NAME

Marsh Animal Hospital

REFERRING VET

Dr. Armani

INVOICE

12886

DATE

12/30/25

Normal size and margination was present in the kidneys. A normal 1:3 cortex / medulla ratio was maintained. The medulla and cortices were uniform in texture with some increased echogenicity and mild loss of corticomedullary symmetry and definition expected for the age of the patient. No evidence of pelvic dilation was present. The left kidney measured 6.7 cm in length. The right kidney measured 7.6 cm in length.

Adrenal Glands

The left adrenal gland was uniform in size and contour with a uniformly hypoechoic parenchyma. The left adrenal gland measured 0.59 cm width at the caudal pole.

The right adrenal gland was not definitively visualized.

Spleen

The spleen exhibited a finely textured and homogenous parenchyma which was hyperechoic to the liver and renal cortical parenchyma. The capsule was smooth and regular without apparent expansion. The splenic vasculature at the hilus was normal in volume with no evidence of congestion or thrombosis. Acute to chronic inflammatory, neoplastic, or benign parenchyma changes were not noted.

Liver

The liver was subjectively normal in size, structure, and contour. The liver parenchyma was uniform and hypoechoic to the spleen with a mild coarse echotexture. The hepatic and portal vasculature were normal in appearance without signs of congestion. The gallbladder was non-distended in size with thin walls and primarily anechoic luminal content. The cystic and common bile ducts were normal.

Gastrointestinal

The stomach presented intact wall layering with a normal wall layer ratio. The lumen of the stomach was empty with no signs of ileus, obstruction or foreign material.

The visualized segments of small intestine exhibited intact wall layering with normal wall layer ratio and an empty lumen.

Normal visible colon wall layers were present with apparent formed feces in lumen.

Pancreas

The parenchyma of the left limb, body and right limb of the pancreas presented isoechoic to the adjacent omental fat. A normal curvilinear capsule contour of the pancreas was present. The visible pancreatic duct was normal. No signs of active inflammation or neoplastic disease was evident.

Free Abdomen

No omental lymphadenopathy or peritoneal effusion was present.

An ovoid nonhomogenous to hypoechoic mass was visualized appearing to primarily occupy the left peri-cranial abdomen to perithoracic subcutaneous space measuring approximately 9.0 cm to 10.0 cm in diameter. The mass appeared to efface and potentially slightly distort the associated left body wall. The mass did not involve the left liver or spleen.



PATIENT

Holly Adams

SPECIES

Canine

BREED

Golden Retriever

SEX

Spayed Female

AGE

12 Years 2 Months

WEIGHT

93 pounds

INTERPRETED BY

R. McKenzie Daniel,
 DVM, DABVP (Canine
 / Feline Practice)

IMAGING PERFORMED BY

Kerri Becker

HOSPITAL NAME

Marsh Animal Hospital

REFERRING VET

Dr. Armani

INVOICE

12886

DATE

12/30/25

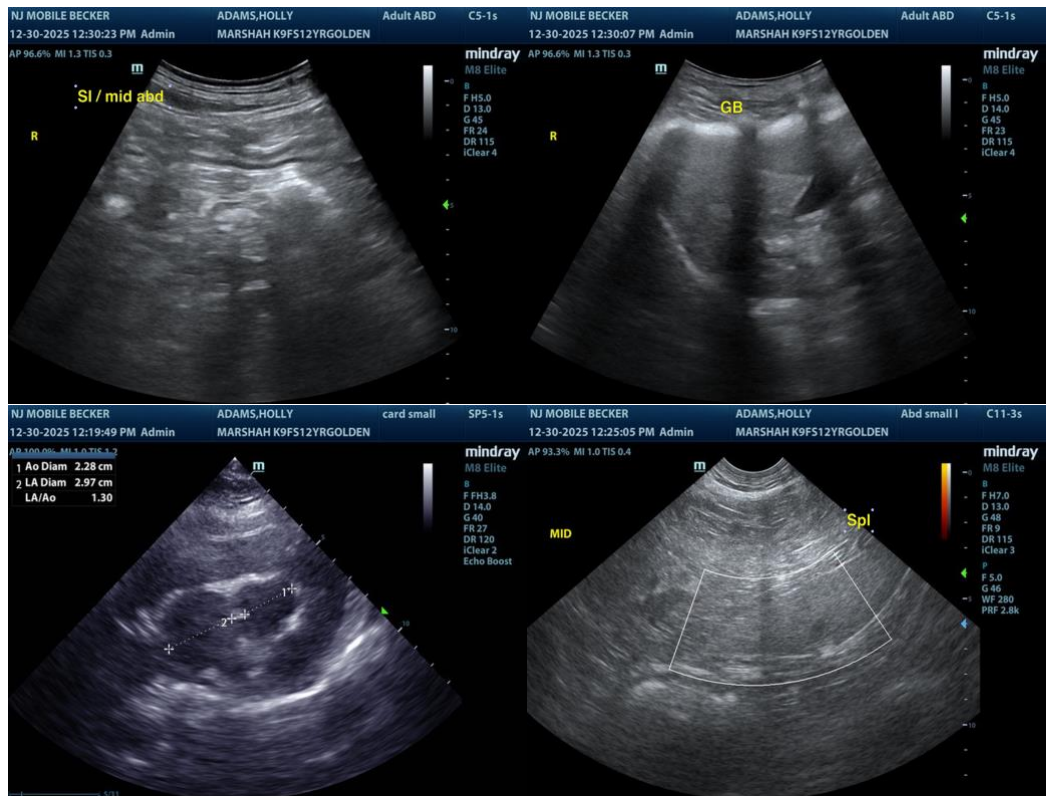
ULTRASONOGRAPHIC FINDINGS

- Normal echocardiogram.
- Overall sonographically unremarkable abdomen with age-related renal changes.
- Unspecified left primarily subcutaneous peri-abdominal/perithoracic mass.

INTERPRETATION OF THE FINDINGS & FURTHER RECOMMENDATIONS

Definitive evidence of primarily subcutaneous left mass intrusion into the abdominal cavity was not obvious. Potential distortion or adhesion to associated deep body wall or musculature is possible. The mass did not exhibit typical lipoma criteria. Correlation with pending cytology is recommended with biopsy possibly indicated for a definitive diagnosis. Assuming no pathology on three view chest radiographs and if surgery is a potential, CT assessment of the mass for further clarification and surgical planning may be considered.

SonoPath CT Services are offered at the SonoPath Imaging and Veterinary Education Center, 141 Main St (rt 206), Andover, New Jersey, a 20-minute drive west on route 80/206 North from the route 80/287 interchange/Parsippany, New Jersey. More information can be found at <https://sonopath.com/services/sonopath-ct-services>





PATIENT

Holly Adams

SPECIES

Canine

BREED

Golden Retriever

SEX

Spayed Female

AGE

12 Years 2 Months

WEIGHT

93 pounds

INTERPRETED BY

R. McKenzie Daniel,
 DVM, DABVP (Canine
 / Feline Practice)

**IMAGING
 PERFORMED BY**

Kerri Becker

HOSPITAL NAME

Marsh Animal Hospital

REFERRING VET

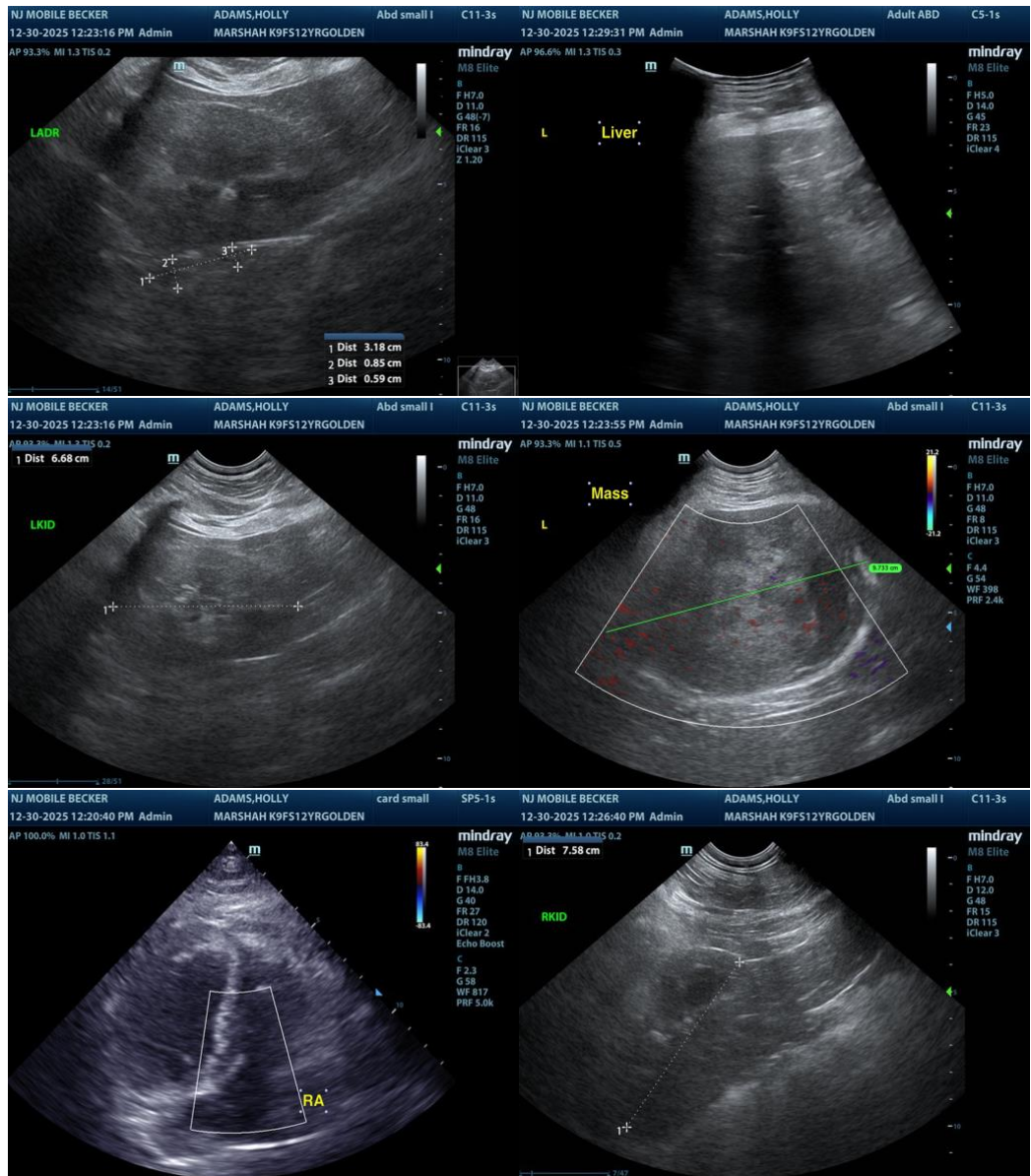
Dr. Armani

INVOICE

12886

DATE

12/30/25



The information and recommendations provided are based on the images presented by the referring veterinarian/sonographer. No evaluation can be communicated regarding pathology that was not visible in the image/video clips provided.

Thank you for this referral. If the clinical or image interpretation does not parallel your findings or if I can be of any further assistance, please contact me.

R. McKenzie Daniel, DVM, DABVP (Canine / Feline Practice)

info@SonoPath.com