


PATIENT PRESENTING CLINICAL SIGNS

Hunter Gibson –gr 2-3 murmur heard

SPECIES ULTRASONOGRAPHIC EXAMINATION OF THE HEART

Canine

BREED

Welsh Spaniel

SEX

MN

AGE

11 years

WEIGHT

36 lbs.

CANINE	MR	TR	LA/AO	LA/AO	FS	EF	EPSS
CARDIAC PARAMETERS	VMAX (m/s)	VMAX (m/s)	(Boon method)	(Heart Base; Swe)	(%)	(%)	(cm)
NORMAL PARAMETER	4.5-5.5	<2.7	1.3	<1.6	28-40	40-100	<0.6
PATIENT	5.0	2.0	1.0	1.0	45.5	80.2	0.35
CANINE CARDIAC PARAMETERS	HR (BPM)	AV VMAX (m/s)	PV MAX (m/s)	BODY WEIGHT (kg)	LA 2D short axis Base view (cm)	LVIDd Avg; 2D and m-mode short axis (cm)	LVIDs Avg; 2D and m-mode short axis (cm)
NORMAL PARAMETER	50-100	0.7-1.7	0.7-1.6	BELOW	BELOW	BELOW	BELOW
PATIENT	151	1.2	1.4		2.9	3.0	

INTERPRETED BY

 R. McKenzie Daniel,
 DVM, DABVP

IMAGING PERFORMED BY

Kelly Reshny, RVT

HOSPITAL NAME

Maples AH

REFERRING VET

Dr. Kazienko

INVOICE

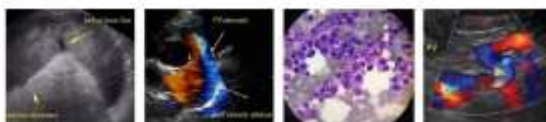
12711

DATE

12/3/21

Cardiac Presentation

The echocardiogram in this patient demonstrated normal **left atrial** size based on 3 different LA measurement methods. Chamber volumes and echogenicity were normal. The cranial and caudal **mitral** valve leaflets presented vegetative thickening consistent with endocardiosis. Doppler indicated measurable eccentric mitral valve insufficiency. The **left ventricle** presented thicknesses with linear contour and was not dilated nor restricted. The **myocardium** presented normal echogenicity without subjective evidence of significant fibrotic or ischemic disease. **Contractility** of the ventricular walls was adequate and in normal range for this patient evidenced by the fractional shortening measurement and subjective evaluation of the different regions of the myocardium. The **left ventricular outflow** tract demonstrated normal laminar flow and subjective structural integrity. The **right atrium** and auricle revealed normal size, structure and content. No evidence of masses was noted or chamber overload. **Tricuspid** valvular assessment demonstrated adequate linear morphology. Color doppler assessment revealed concurrent mild tricuspid valve Insufficiency. The **right ventricle** was of normal size (1/3 diameter of LV), chordae structure, myocardial echogenicity and thickness. **Pulmonic** tract assessment revealed normal valve structure, laminar flow, and diameter (approx. 1:1 pa/ao ratio). No visible **pericardial** or free pleura fluid was noted. No echographically detectable evidence of infiltrative disease was visible. The cranial **mediastinum and pericardial regions** were free of masses in the visible window.



PATIENT

Hunter Gibson

SPECIES

Canine

BREED

Welsh Spaniel

SEX

MN

AGE

11 years

WEIGHT

36 lbs.

INTERPRETED BY

R. McKenzie Daniel,
DVM, DABVP

**IMAGING
PERFORMED BY**

Kelly Reshny, RVT

HOSPITAL NAME

Maples AH

REFERRING VET

Dr. Kazienko

INVOICE

12711

DATE

12/3/21

ULTRASONOGRAPHIC FINDINGS

Primary Findings

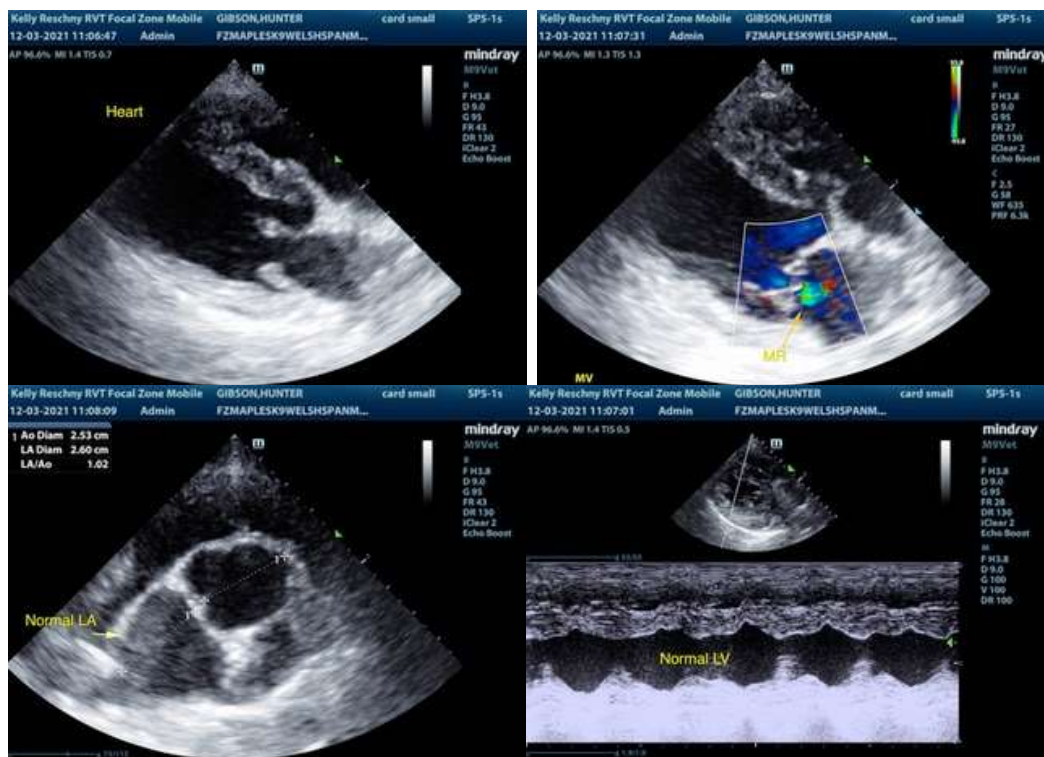
- Chronic mitral valve disease (ACVIM B1)

INTERPRETATION OF THE FINDINGS & FURTHER RECOMMENDATIONS

The cause of the murmur is chronic degenerative valvular changes with secondary eccentric mitral valve insufficiency. The lack of left atrial enlargement implies that the risk of complication secondary to mitral valve insufficiency is low at this time and, without current clinical signs, indicates that medical therapy is not required. Conservative monitoring is recommended with a recheck echocardiogram in 6-12 months, sooner if clinical signs suggestive of heart disease develop. No anesthetic contraindications. If anesthesia is required, the following anesthetic protocol is suggested.

Suggested anesthetic protocol may include opioid or Benzodiazepine pre-med, induction with Propofol or Alfaxalone, and appropriate gas anesthesia with avoidance of alpha 2 agonists.

<https://www.antechdiagnostics.com/cadet-braf>





PATIENT

Hunter Gibson

The information and recommendations provided are based on the images presented by the referring veterinarian. No evaluation can be communicated regarding pathology that was not visible in the image/video clips provided.

SPECIES

Canine

Thank you for this referral. If the clinical or image interpretation does not parallel your findings or if I can be of any further assistance please contact me.

BREED

Welsh Spaniel

R. McKenzie Daniel, DVM, DABVP (Canine / Feline Practice)
info@SonoPath.com

SEX

MN

AGE

11 years

WEIGHT

36 lbs.

INTERPRETED BY

R. McKenzie Daniel,
DVM, DABVP

IMAGING PERFORMED BY

Kelly Reshny, RVT

HOSPITAL NAME

Maples AH

REFERRING VET

Dr. Kazienko

INVOICE

12711

DATE

12/3/21