



PATIENT

Abel Aviles

SPECIES

Canine

BREED

Yorkshire Terrier Mix

SEX

MN

AGE

13 years

WEIGHT

16.5 lbs.

INTERPRETED BY

R. McKenzie Daniel,
DVM, DABVP
(Canine and Feline)

IMAGING PERFORMED BY

Shari Reffi, CVT

HOSPITAL NAME

Newton Vet

REFERRING VET

Dr. Barron

INVOICE

12697

DATE

12/3/21

PRESENTING CLINICAL SIGNS

Anorexia x 1week. Current meds: Cerenia, Doxycycline

Abnormal PE/Chem/CBC/UA Results: Lyme +, ALB 2.0, TBili 1.6, CPL abn.

ULTRASONOGRAPHIC EXAMINATION OF THE HEART & ABDOMEN

CANINE CARDIAC PARAMETERS	MR VMAX (m/s)	TR VMAX (m/s)	LA/AO (Boon method)	LA/AO (Heart Base; Swe)	FS (%)	EF (%)	EPSS (cm)
NORMAL PARAMETER	4.5-5.5	<2.7	1.3	<1.6	28-40	40-100	<0.6
PATIENT			1.2	1.2	40.8	74.5	0.15
CANINE CARDIAC PARAMETERS	HR (BPM)	AV VMAX (m/s)	PV MAX (m/s)	BODY WEIGHT (kg)	LA 2D short axis Base view (cm)	LVIDd Avg; 2D and m-mode short axis (cm)	LVIDs Avg; 2D and m-mode short axis (cm)
NORMAL PARAMETER	50-100	0.7-1.7	0.7-1.6	BELOW	BELOW	BELOW	BELOW
PATIENT	117	1.0	0.8		2.1	2.0	

Cardiac Presentation

The echocardiogram in this patient demonstrated normal **left atrial** size based on 3 different LA measurement methods. Chamber volumes and echogenicity were normal. The cranial and caudal **mitral** valve leaflets presented vegetative thickening consistent with endocardiosis. Doppler indicated measurable eccentric insufficiency. The **left ventricle** presented thicknesses with linear contour and was not dilated nor restricted. The **myocardium** presented normal echogenicity without subjective evidence of significant fibrotic or ischemic disease. **Contractility** of the ventricular walls was adequate and in normal range for this patient evidenced by the fractional shortening measurement and subjective evaluation of the different regions of the myocardium. The **left ventricular outflow** tract demonstrated normal laminar flow and subjective structural integrity. The **right atrium** and auricle revealed normal size, structure and content. No evidence of masses was noted or chamber overload. **Tricuspid** valvular assessment demonstrated adequate linear morphology. Mild tricuspid valve insufficiency was noted on color doppler assessment. The **right ventricle** was of normal size (1/3 diameter of LV), chordae structure, myocardial echogenicity and thickness. **Pulmonic** tract assessment revealed normal valve structure, laminar flow, and diameter (approx. 1:1 pa/ao ratio). No visible **pericardial** or free pleura fluid was noted. Moderate pleural free fluid was present. Potential for III-defined mass or lymphadenopathy in the cranial thorax or parasternal region is possible. Potential mass or sternal lymphadenopathy measured 2.7 cm in diameter.

Urinary System

The urinary bladder, trigone, cystourethral junction, and visible pelvic urethra to a depth of 2.0 cm exhibited normal thickness and tone. Anechoic urine was present in the lumen with no uroliths or



PATIENT	sediment. The ureteral papillae were normal. The ureters were not visible which is normal. No evidence of inflammatory or neoplastic changes was noted.
Abel Aviles	
SPECIES	Several medial iliac lymph nodes were present. These lymph nodes were homogenous, mildly hypoechoic and smoothly margined. A normal width: length ratio was maintained (<0.5). Evidence of perilymphatic inflammation was evident.
Canine	
BREED	Normal size and margination were present in the kidneys. A normal 1:3 cortex / medulla ratio and normal corticomedullary definition were maintained. The echogenicity of the cortex was similar to or slightly less than normal liver parenchyma while the medulla echogenicity was hypoechoic to the cortex with no evidence of pelvic dilation. The left kidney measured 4.8 cm in length. The right kidney measured 4.4 cm in length.
Yorkshire Terrier Mix	
SEX	
MN	Adrenal Glands
AGE	The left adrenal gland was uniform in size and contour with a uniformly hypoechoic parenchyma. The left adrenal gland measured 1.9 cm length x 0.71 cm width at the caudal pole. The right adrenal gland was uniform in size and contour with a uniformly hypoechoic parenchyma. The right adrenal gland measured 2.0 cm length x 0.60 cm width at the caudal pole.
13 years	
WEIGHT	Spleen
16.5 lbs.	The spleen exhibited increased size with maintained symmetrical contour and generalized nonuniform decreased splenic parenchyma echogenicity. No distinct splenic masses or nodules were noted.
INTERPRETED BY	Liver/ Gallbladder
R. McKenzie Daniel, DVM, DABVP (Canine and Feline)	The liver presented enlarged in size. The parenchyma of the liver was subjectively normal in echogenicity compared to the spleen and renal cortices. The liver parenchyma was uniform with a mildly coarse echotexture. The capsule of the liver was symmetrically rounded to mildly swollen in margination. The hepatic and portal vasculature were normal in appearance without signs of congestion. The cranial abdominal caudal vena cava was sonographically normal without evidence of dilation or thrombus formation. The gallbladder was non-distended in size with primarily anechoic luminal content. The cystic and common bile ducts were normal.
IMAGING PERFORMED BY	Gastrointestinal
Shari Reffi, CVT	The stomach presented wall thickening secondary to echogenic mucosa hypertrophy. Intact wall layering was maintained and distinct. The stomach was primarily empty with mild luminal gas.
HOSPITAL NAME	The area of the pylorus or upper duodenum revealed a mural mass exhibiting hypoechoic mural hypertrophy and loss of distinct wall layering. Wall width in the pyloric to upper duodenal mural mass measured 1.0 cm width. The remainder of the small intestine demonstrated intact wall layering and maintained 1:3 muscularis / mucosa ratio. The mucosa exhibited mild decreased echogenicity with occasional mucosal speckling. A segmental to diffuse ileus pattern consisting of mild fluid accumulation in the intestinal lumen was present without obstruction or foreign material.
Newton Vet	
REFERRING VET	Normal visible colon wall layers were present with apparent formed feces in lumen.
Dr. Barron	
INVOICE	
12697	
DATE	
12/3/21	



PATIENT

Pancreas

Abel Aviles

Diffuse enlargement of the pancreas with ill-defined, hypoechoic to heterogeneous parenchyma and asymmetrical contour was present. The surrounding omental fat around the enlarged to hypoechoic pancreas was echogenic indicative of reactive change, adhesions, focal peritonitis, or saponification. Mild localized free fluid was present around the abnormal pancreas.

SPECIES

Canine

BREED

Free Abdomen

Yorkshire Terrier Mix

Intermittent, mid to cranial abdominal mesenteric root lymph nodes were present. The lymph nodes exhibited symmetrical to rounded margination with abnormal width: length ratio (>0.5). The enlarged lymph nodes were bordered by echogenic to reactive mesentery. The mesenteric root lymph nodes measured 1.4 cm length and 1.2 cm width. Generalized nonuniformly echogenic mesentery most notable in the mid to cranial abdomen around the pyloric to upper duodenal mural mass and around the pancreas was present.

SEX

MN

AGE

13 years

ULTRASONOGRAPHIC FINDINGS

WEIGHT

16.5 lbs.

Primary Findings

- Compensated mild MR/TR - no evidence of left atrium enlargement or clinical pulmonary hypertension
- Possible cranial thoracic / parasternal mass lesion or lymphadenopathy
- Splenomegaly with nonuniform hypoechoic parenchyma
- Non-congestive hepatomegaly
- Hypoechoic to swollen pancreas
- Pyloric to upper duodenal mural mass
- Generalized peritonitis with concurrent hypoechoic to swollen mesenteric lymphadenopathy
- Noncardiogenic bicavitary effusion

INTERPRETED BY

R. McKenzie Daniel,
DVM, DABVP
(Canine and Feline)

IMAGING PERFORMED BY

Shari Reffi, CVT

HOSPITAL NAME

Newton Vet

REFERRING VET

Dr. Barron

INVOICE

12697

DATE

12/3/21

INTERPRETATION OF THE FINDINGS & FURTHER RECOMMENDATIONS

The sonographic abnormalities in this case are most compatible with multicentric neoplasia involving the upper gastrointestinal tract, spleen, potential liver, as well as likely thoracic cavity, given the bicavitary noncardiogenic effusion. Primary concern is for multicentric round cell neoplasia specifically lymphoma with potential for lymphomatosis and regional upper gastrointestinal and peripancreatic omental seeding.

Assuming normal clotting status, hepatosplenic and lymphatic FNA along with effusion analysis could be considered with potential for oncology consultation. However, an unfavorable prognosis is unfortunately indicated.



PATIENT

Abel Aviles

SPECIES

Canine

BREED

Yorkshire Terrier Mix

SEX

MN

AGE

13 years

WEIGHT

16.5 lbs.

INTERPRETED BY

R. McKenzie Daniel,
DVM, DABVP
(Canine and Feline)

IMAGING PERFORMED BY

Shari Reffi, CVT

HOSPITAL NAME

Newton Vet

REFERRING VET

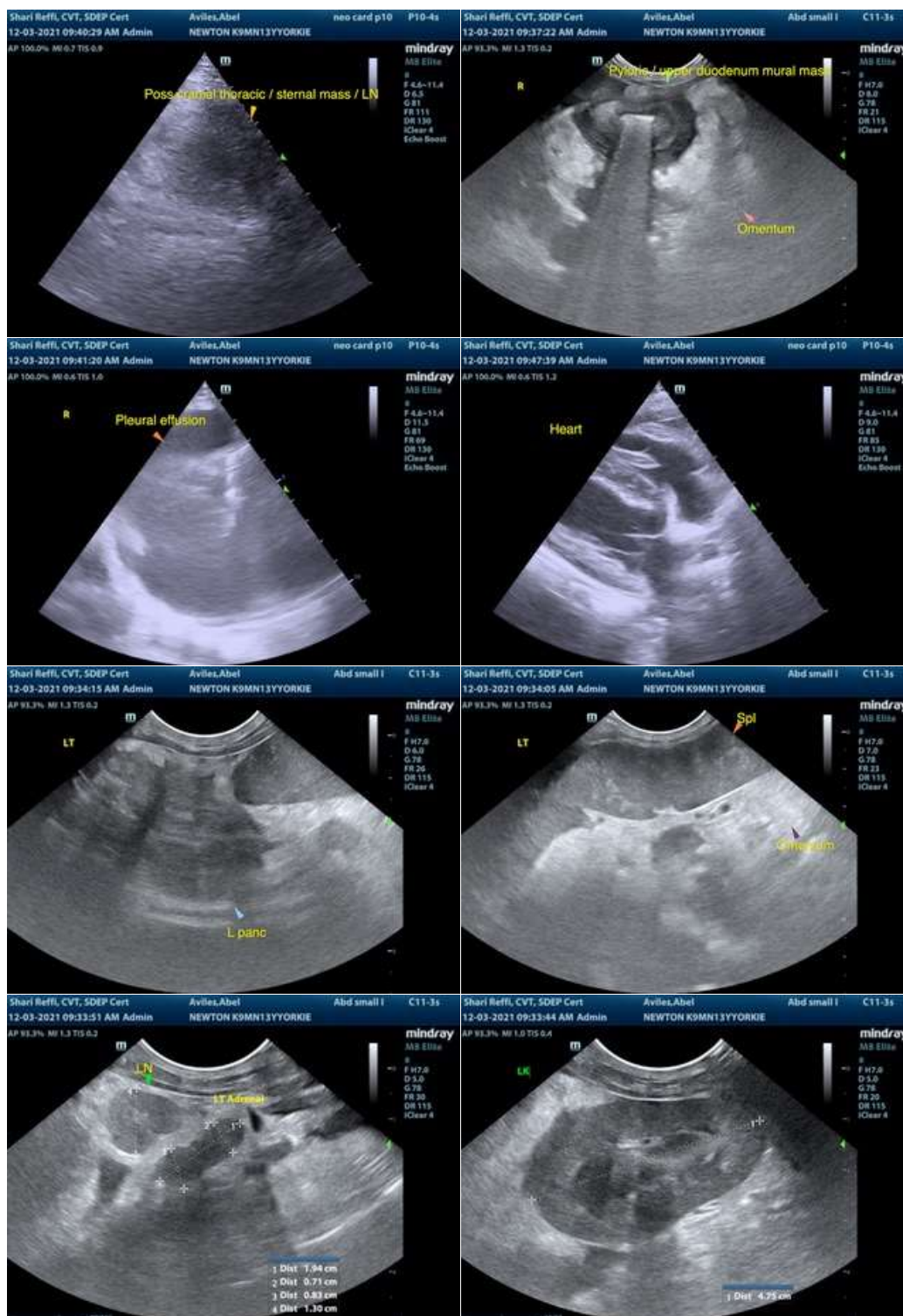
Dr. Barron

INVOICE

12697

DATE

12/3/21





PATIENT

Abel Aviles

SPECIES

Canine

BREED

Yorkshire Terrier Mix

SEX

MN

AGE

13 years

WEIGHT

16.5 lbs.

INTERPRETED BY

R. McKenzie Daniel,
DVM, DABVP
(Canine and Feline)

IMAGING PERFORMED BY

Shari Reffi, CVT

HOSPITAL NAME

Newton Vet

REFERRING VET

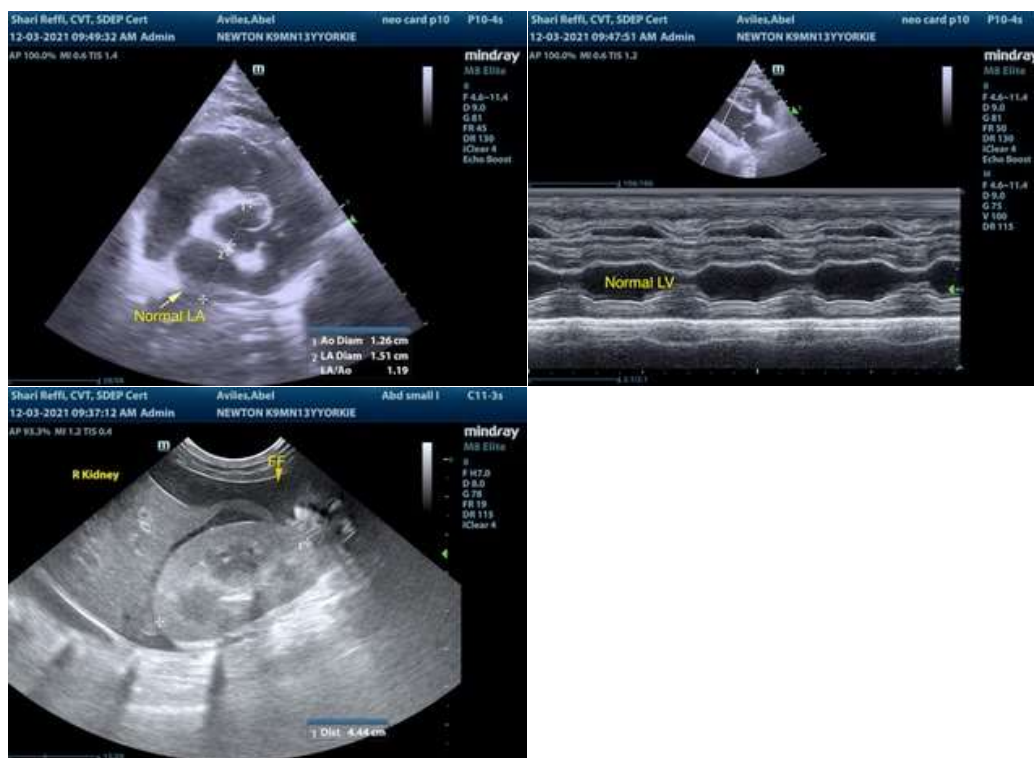
Dr. Barron

INVOICE

12697

DATE

12/3/21



The information and recommendations provided are based on the images presented by the referring veterinarian. No evaluation can be communicated regarding pathology that was not visible in the image/video clips provided.

Thank you for this referral. If the clinical or image interpretation does not parallel your findings or if I can be of any further assistance please contact me.

R. McKenzie Daniel, DVM, DABVP (Canine / Feline Practice)
info@SonoPath.com