

**PATIENT**

Scout Morrison

SPECIES

Canine

BREED

Terrier mix

SEX

SF

AGE

9 years

WEIGHT

23 lbs.

INTERPRETED BYR. McKenzie Daniel,
DVM, DABVP
(Canine and Feline)**IMAGING
PERFORMED BY**

Sarah Pender, CVT

HOSPITAL NAME

SVS Imaging QC

REFERRING VET

Dr. Stacy Kula

INVOICE

15758

DATE

12/29/22

PRESENTING CLINICAL SIGNS

Presented initially for eating and drinking more than normal and having both urinary and fecal accidents in the home.

Abnormal PE/Chem/CBC/UA Results: Undifferentiated Cushing's seen on the LDDST done on 11/15/22

ULTRASONOGRAPHIC EXAMINATION OF THE ABDOMEN**Urinary System**

The urinary bladder, trigone, cystourethral junction, and visible pelvic urethra to a depth of 3.0 cm exhibited normal thickness and tone. Anechoic urine was present in the lumen with no uroliths or sediment. The ureteral papillae were normal. The ureters were not visible which is normal. No evidence of inflammatory or neoplastic changes was noted.

The area of the aortic trifurcation was free of pathology.

Normal size and margination were present in the kidneys. A normal 1:3 cortex / medulla ratio was maintained. The medulla and cortices were uniform in texture with some increased echogenicity and mild loss of corticomedullary symmetry and definition expected for the age of the patient. No evidence of pelvic dilation was present. The left kidney measured 4.3 cm in length. The right kidney measured 4.3 cm in length.

Adrenal Glands

Bilateral symmetrical adrenal gland enlargement with uniformly hypoechoic parenchyma was present. The left adrenal gland measured 2.4 cm length x 0.65 cm width at the caudal pole. The right adrenal gland measured 2.1 cm length x 0.69 cm width at the caudal pole. No evidence of adrenal neoplastic criteria was noted.

Spleen

The spleen exhibited a finely textured and homogenous parenchyma which was hyperechoic to the liver and renal cortical parenchyma. The capsule was smooth and regular without apparent expansion. The splenic vasculature at the hilus was normal in volume with no evidence of congestion or thrombosis. Acute to chronic inflammatory, neoplastic, or benign parenchyma changes were not noted.

Liver/ Gallbladder

The liver presented enlarged in size. The parenchyma of the liver was subjectively normal in echogenicity compared to the spleen and renal cortices. The liver parenchyma was uniform with a mildly coarse echotexture. The capsule of the liver was symmetrically rounded to mildly swollen in margination. The hepatic and portal vasculature were normal in appearance without signs of congestion. The gallbladder was non-distended in size with primarily anechoic luminal content. The cystic and common bile ducts were normal.

**PATIENT**

Scout Morrison

SPECIES

Canine

BREED

Terrier mix

SEX

SF

AGE

9 years

WEIGHT

23 lbs.

INTERPRETED BY

R. McKenzie Daniel,
DVM, DABVP
(Canine and Feline)

IMAGING PERFORMED BY

Sarah Pender, CVT

HOSPITAL NAME

SVS Imaging QC

REFERRING VET

Dr. Stacy Kula

INVOICE

15758

DATE

12/29/22

Gastrointestinal

The stomach presented intact wall layering with a normal wall layer ratio. Mild non-shadowing ingesta / chyme was present.

The small intestine presented intact wall layering with 1:3 muscularis/mucosa ratio. The lumen of the small intestine was empty with no signs of ileus, obstruction, or foreign material.

Normal visible colon wall layers were present with apparent formed feces in lumen.

Pancreas

The parenchyma of the left limb, body, and right limb of the pancreas presented isoechoic to the adjacent omental fat. A normal curvilinear capsule contour of the pancreas was present. The visible pancreatic duct was normal. No signs of active inflammation or neoplastic disease were evident.

Free Abdomen

No overt lymphadenopathy or peritoneal effusion was present.

ULTRASONOGRAPHIC FINDINGS

- Bilateral mild adrenomegaly - consistent with PDH
- Mild chronic renal changes
- Vacuolar hepatopathy pattern - benign

INTERPRETATION OF THE FINDINGS & FURTHER RECOMMENDATIONS

Given the reported positive LDDST, the adrenal presentation is consistent with pituitary-dependent hyperadrenocorticism without evidence of adrenal neoplastic criteria. Further renal staging to include urine C/S and protein: creatinine ratio on sterile urine sample may be considered.

For an additional charge, internal medicine consult can be utilized through SonoPath.com. You can select the internal medicine drop down at <http://spa.sonopath.com/>.

One of the world's top internists & SonoPath associate Dr. Remo Lobetti BVSc, MMedVet, PhD, DECVIM can evaluate your case through SonoPath. <https://sonopath.com/resources/sonopath-services/internal-medicine-teleconsultation-services>

IMAGING PERFORMED BY

svsmobileimaging.com 309-737-3070



PATIENT

Scout Morrison

SPECIES

Canine

BREED

Terrier mix

SEX

SF

AGE

9 years

WEIGHT

23 lbs.

INTERPRETED BY

R. McKenzie Daniel, DVM, DABVP (Canine and Feline)

IMAGING PERFORMED BY

Sarah Pender, CVT

HOSPITAL NAME

SVS Imaging QC

REFERRING VET

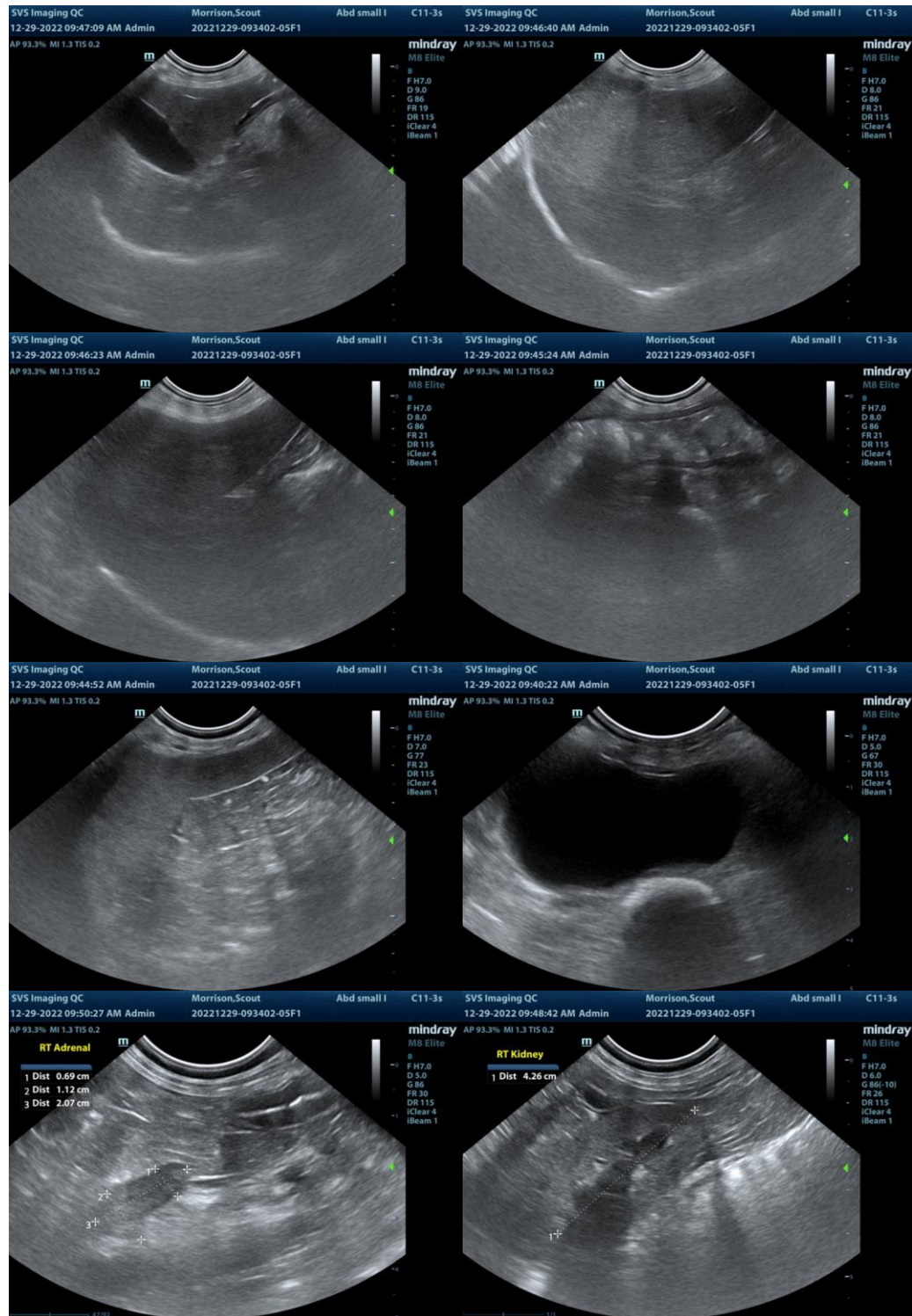
Dr. Stacy Kula

INVOICE

15758

DATE

12/29/22



IMAGING PERFORMED BY

svsmobileimaging.com 309-737-3070



PATIENT

Scout Morrison

SPECIES

Canine

BREED

Terrier mix

SEX

SF

AGE

9 years

WEIGHT

23 lbs.

INTERPRETED BY

R. McKenzie Daniel,
DVM, DABVP
(Canine and Feline)

**IMAGING
PERFORMED BY**

Sarah Pender, CVT

HOSPITAL NAME

SVS Imaging QC

REFERRING VET

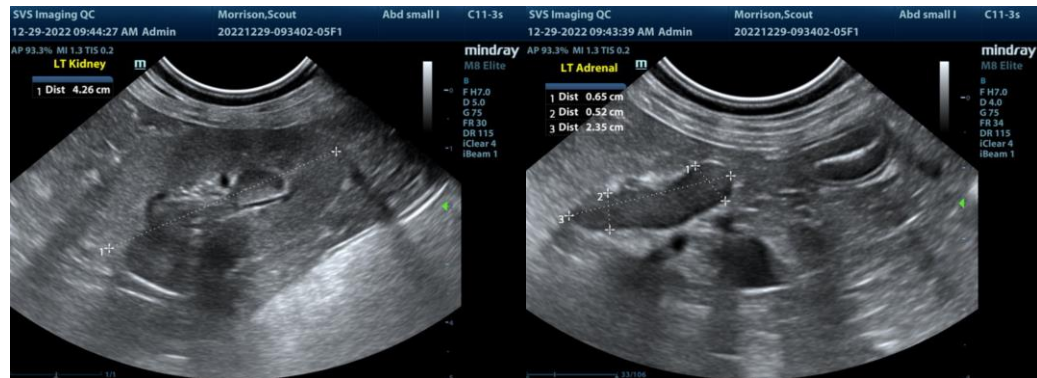
Dr. Stacy Kula

INVOICE

15758

DATE

12/29/22



The information and recommendations provided are based on the images presented by the referring veterinarian/sonographer. No evaluation can be communicated regarding pathology that was not visible in the image/video clips provided.

Thank you for this referral. If the clinical or image interpretation does not parallel your findings or if I can be of any further assistance please contact me.

R. McKenzie Daniel, DVM, DABVP (Canine / Feline Practice)
info@SonoPath.com