


PATIENT PRESENTING CLINICAL SIGNS

PATIENT Odin Taylor
SPECIES Canine
BREED Shih Tzu X
SEX MN
AGE 16 years
WEIGHT 5.7 kg

PRESENTING CLINICAL SIGNS
 QAR, mm pink, crt <2s Mildly prolonged skin tent, suspect more age related than dehydration
 Ongoing hematuria - dribbling small amount of urine. BW and UA done Nov 2021 fairly unremarkable
 other than hematuria. Waxse and wanes R4ecently has noticed p just trickles, not a good stream E/D
 well, no vomiting/diarrhea Mouth/Teeth/Gums: Significant underbite. MOb dental calculus on all, esp
 premolars with associated gingivitis and halitosis. Multiple missing teeth Heart/Cardiovascular: Grade
 5/6 left systolic heart murmur, audible across all lungfield. Palpable thrill - stable Persistent hematuria
 Pollakiuria, grade 5/6 left systolic murmur.
 Abnormal PE/Chem/CBC/UA Results: November 18, 2021 - GLOB: 48 HIGH 25-45 g/L MPV: 13.9
 HIGH 8.7-13.2 fL

ULTRASONOGRAPHIC EXAMINATION OF THE HEART & ABDOMEN

	CANINE	MR	TR	LA/AO	LA/AO	FS	EF	EPSS
CARDIAC PARAMETERS		VMAX (m/s)	VMAX (m/s)	(Boon method)	(Heart Base; Swe)	(%)	(%)	(cm)
NORMAL PARAMETER		4.5-5.5	<2.7	1.3	<1.6	28-40	40-100	<0.6
PATIENT		5.9	2.2	NM	1.74	51.5	86.5	0.16
CANINE CARDIAC PARAMETERS		HR (BPM)	AV VMAX (m/s)	PV MAX (m/s)	BODY WEIGHT (kg)	LA 2D short axis Base view (cm)	LVIDd Avg; 2D and m- mode short axis (cm)	LVIDs Avg; 2D and m- mode short axis (cm)
NORMAL PARAMETER		50-100	0.7-1.7	0.7-1.6	BELOW	BELOW	BELOW	BELOW
PATIENT		NM	1.24	1.1		3.8	3.3	

INTERPRETED BY

 R. McKenzie Daniel,
 DVM, DABVP

IMAGING PERFORMED BY

Crystal Hill

HOSPITAL NAME

Beatties Burlington PH

REFERRING VET

Dr. Murota

INVOICE

12909

DATE

12/29/21

Cardiac Presentation

The echocardiogram in this patient demonstrated moderately enlarged **left atrial** size based on 3 different LA measurement methods. Deviation of the interatrial septum towards the right atrium suggestive of increased left atrial pressure was present. The cranial and caudal **mitral** valve leaflets presented significant vegetative thickening consistent with endocardiosis with mild prolapse of both the anterior and posterior leaflet. Doppler indicated measurable eccentric insufficiency. The **left ventricle** presented thicknesses with linear contour with increased left ventricle volume. The **myocardium** presented normal echogenicity without subjective evidence of significant fibrotic or ischemic disease. **Contractility** of the ventricular walls was mildly increased as evidenced by the fractional shortening measurement and subjective evaluation of the different regions of the myocardium. The **left ventricular outflow** tract demonstrated normal laminar flow and subjective structural integrity. The **right atrium** and auricle revealed normal size, structure and content. No evidence of masses was noted or chamber overload. **Tricuspid** valvular assessment demonstrated



PATIENT

Odin Taylor

SPECIES

Canine

BREED

Shih Tzu X

SEX

MN

AGE

16 years

WEIGHT

5.7 kg

INTERPRETED BY

R. McKenzie Daniel,
DVM, DABVP

**IMAGING
PERFORMED BY**

Crystal Hill

HOSPITAL NAME

Beatties Burlington PH

REFERRING VET

Dr. Murota

INVOICE

12909

DATE

12/29/21

concurrent mild vegetative thickening with mild concurrent insufficiency on color doppler assessment. The **right ventricle** was of normal size (1/3 diameter of LV), chordae structure, myocardial echogenicity and thickness. **Pulmonic** tract assessment revealed normal valve structure, laminar flow, and diameter (approx. 1:1 pa/ao ratio). No visible **pericardial** or free pleura fluid was noted. No echographically detectable evidence of infiltrative disease was visible. The cranial **mediastinum and pericardial regions** were free of masses in the visible window.

Urinary System

A sessile based mass with asymmetrical margination was present primarily involving the majority of the dorsal urinary bladder wall extending into the lumen and measured 2.3 cm x 1.5 cm. Evidence of mild polyploid component along the periphery of the mass within the urinary bladder lumen was present. The mass presented nonhomogeneous parenchyma exhibiting pinpoint hyperechoic foci, suggestive of pinpoint mineralization. Doppler evaluation of the mass confirmed blood flow within the mass. Anechoic urine was present in the lumen with no uroliths or sediment. No evidence of calculi was noted. Overall normal urinary bladder tone was noted. The urethra was normal to a depth of 3.0 cm. The ureteral papillae were normal. The ureters were not visible which is normal.

The residual prostate was mildly prominent in size with normal symmetrical capsule contour and nonhomogeneous parenchyma. No overt evidence of residual prostatic parenchymal mineralization was noted. The residual prostate measured 1.4 cm width. Subtle intraparenchymal cyst and potential for nonspecific nodule in the ventral parenchyma was present, measuring 0.36 cm diameter.

The area of the aortic trifurcation was free of pathology. No overt evidence of regional medial iliac or sublumbar lymphatic metastasis was noted.

Normal size and margination were present in the kidneys. A normal 1:3 cortex / medulla ratio was maintained. The medulla and cortices were uniform in texture with some increased echogenicity and mild loss of corticomedullary symmetry and definition expected for the age of the patient. A small cyst was noted in the right kidney. No evidence of pyelectasia was present. The left kidney measured 3.5 cm in length. The right kidney measured 5.1 cm in length.

Adrenal Glands

The left adrenal gland was uniform in size and contour with a uniformly hypoechoic parenchyma. The left adrenal gland measured 2.1 cm length x 0.41 cm width at the caudal pole. The right adrenal gland was uniform in size and contour with a uniformly hypoechoic parenchyma. The right adrenal gland measured 1.4 cm length x 0.55 cm width at the caudal pole.

Spleen

The spleen exhibited a finely textured and homogenous parenchyma which was hyperechoic to the liver and renal cortical parenchyma. The capsule was smooth and regular without apparent expansion. The splenic vasculature at the hilus was normal in volume with no evidence of congestion or thrombosis. Acute to chronic inflammatory, neoplastic, or benign parenchyma changes were not noted.



PATIENT

Liver/ Gallbladder

Odin Taylor

The liver was subjectively normal in size, structure, and contour. The liver parenchyma was uniform and hypoechoic to the spleen with a mild coarse echotexture. The hepatic and portal vasculature were normal in appearance without signs of congestion. The gallbladder was non-distended in size with thin walls and primarily anechoic luminal content. The cystic and common bile ducts were normal.

SPECIES

Canine

Gastrointestinal

BREED

Shih Tzu X

The stomach presented intact wall layering with a normal wall layer ratio. The lumen of the stomach contained mild, nonshadowing ingesta / chyme most consistent with post prandial presentation without signs of ileus, obstruction or foreign material.

SEX

The small intestine presented intact wall layering with 1:3 muscularis/mucosa ratio. The lumen of the small intestine was empty with no signs of ileus, obstruction, or foreign material.

MN

Normal visible colon wall layers were present with apparent formed feces in lumen.

AGE

Pancreas

16 years

The pancreas was normal in size and contour with isoechoic to heterogeneous parenchyma compared to adjacent omentum. No signs of active inflammation or neoplasia.

WEIGHT

Free Abdomen

5.7 kg

No overt lymphadenopathy or peritoneal effusion was present.

INTERPRETED BY

ULTRASONOGRAPHIC FINDINGS

R. McKenzie Daniel,
DVM, DABVP

Primary Findings

**IMAGING
PERFORMED BY**

Crystal Hill

HOSPITAL NAME

Beatties Burlington PH

- Chronic mitral valve disease (ACVIM B2)
- Mild TR - estimated pulmonary pressure gradient not overtly consistent with clinical pulmonary hypertension
- Urinary bladder mass
- Mildly prominent to nonhomogeneous residual prostate
- Age-related kidneys with small right kidney cortical cyst

REFERRING VET

INTERPRETATION OF THE FINDINGS & FURTHER RECOMMENDATIONS

Dr. Murota

The cause of the murmur is consistent with chronic degenerative valvular changes with secondary eccentric mitral valve insufficiency. No other clinical issues such as systolic dysfunction or overt clinical pulmonary hypertension were noted. The increased left atrium enlargement, as well as increased left ventricle volume, indicate that the risk for future complication is elevated.

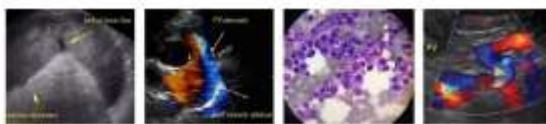
INVOICE

12909

Given these findings, Pimobendan 0.3 mg/kg PO BID is recommended. Monitoring of resting respiration rate is suggested. Recheck echocardiogram is suggested in 6 months, sooner if clinical signs consistent with left-sided heart disease i.e., radiographic pulmonary edema, increased resting respiration rate, exercise intolerance, coughing, etc., are noted.

DATE

12/29/21



PATIENT

Odin Taylor

SPECIES

Canine

BREED

Shih Tzu X

SEX

MN

AGE

16 years

WEIGHT

5.7 kg

INTERPRETED BY

R. McKenzie Daniel,
DVM, DABVP

IMAGING PERFORMED BY

Crystal Hill

HOSPITAL NAME

Beatties Burlington PH

REFERRING VET

Dr. Murota

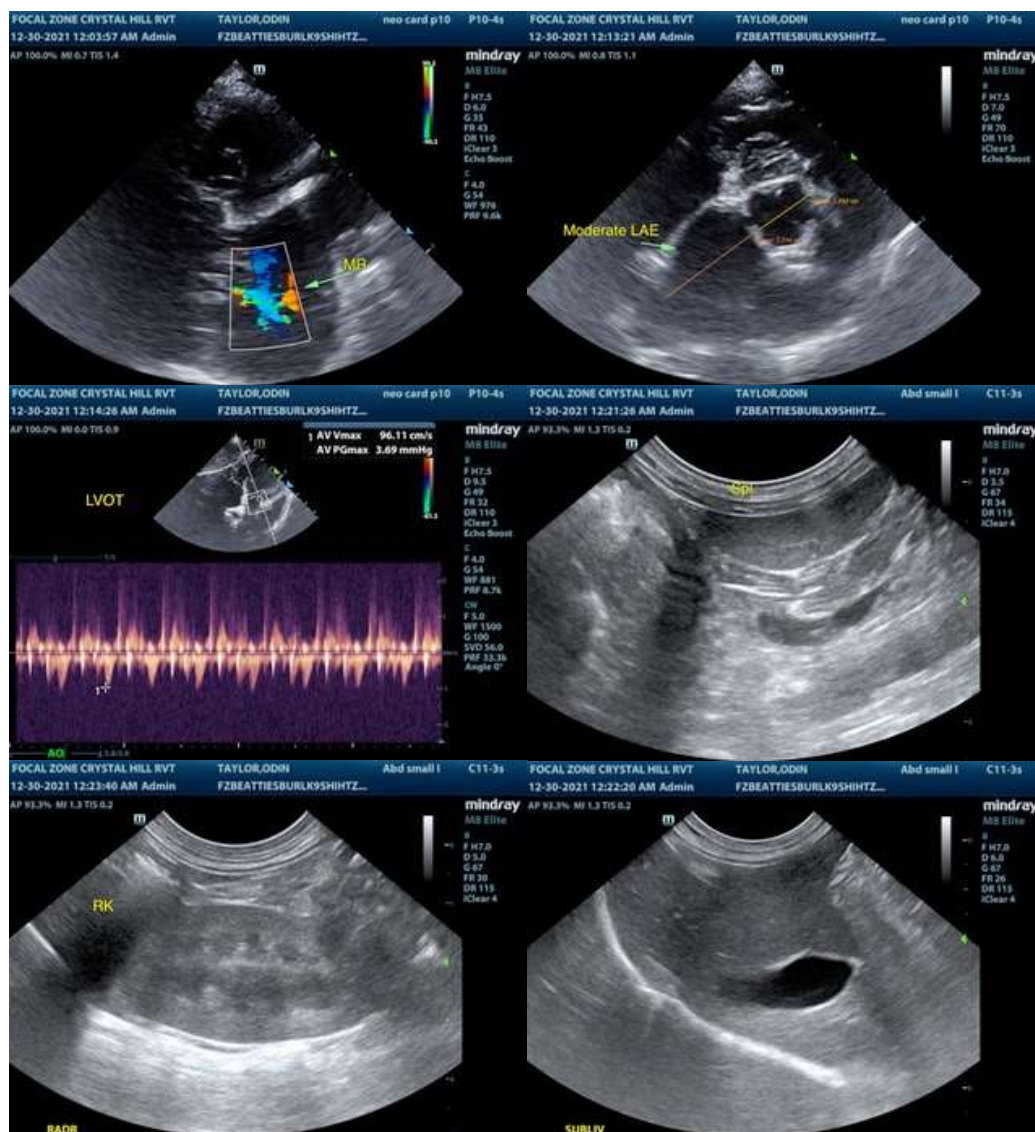
INVOICE

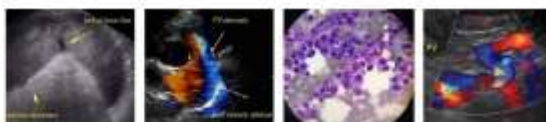
12909

DATE

12/29/21

Although sampling is required for a definitive diagnosis, the urinary bladder mass is most consistent with neoplastic criteria, specifically transitional cell carcinoma. The potential for early residual prostatic involvement cannot be definitively excluded, although not definitive. Screening BRAF Assay may be considered. Empirically, Piroxicam trial with monitoring of renal parameters and assessment of clinical response may prove beneficial. Unfortunately, the urinary bladder mass does not appear to be surgical.





PATIENT

Odin Taylor

SPECIES

Canine

BREED

Shih Tzu X

SEX

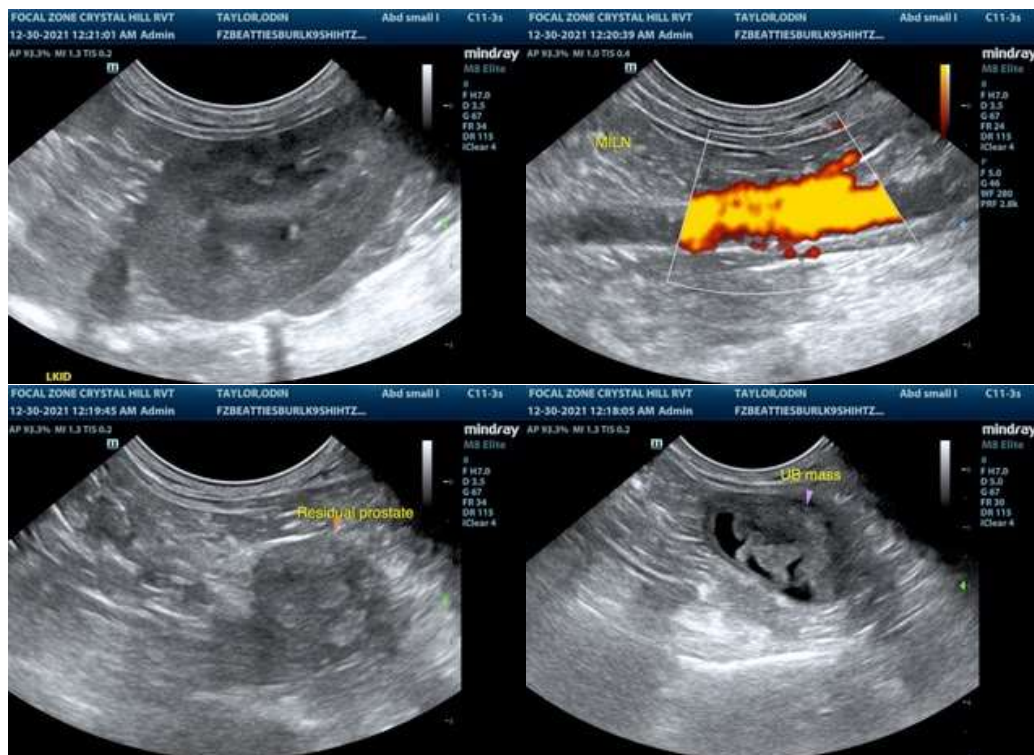
MN

AGE

16 years

WEIGHT

5.7 kg



INTERPRETED BY

R. McKenzie Daniel,
DVM, DABVP

IMAGING PERFORMED BY

Crystal Hill

HOSPITAL NAME

Beatties Burlington PH

REFERRING VET

Dr. Murota

INVOICE

12909

DATE

12/29/21

The information and recommendations provided are based on the images presented by the referring veterinarian. No evaluation can be communicated regarding pathology that was not visible in the image/video clips provided.

Thank you for this referral. If the clinical or image interpretation does not parallel your findings or if I can be of any further assistance please contact me.

R. McKenzie Daniel, DVM, DABVP (Canine / Feline Practice)
info@SonoPath.com