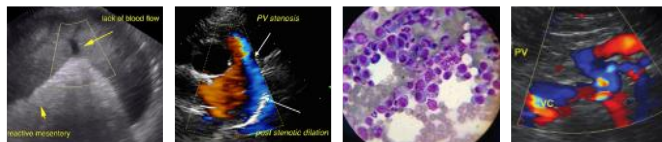
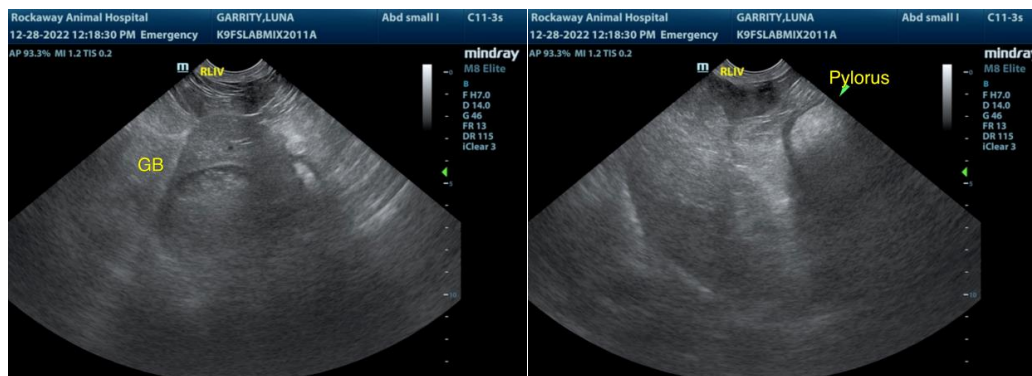
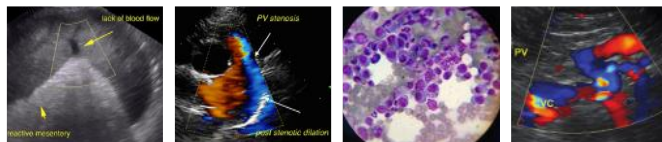


PATIENT	PRESENTING CLINICAL SIGNS
Luna Garrity	shaking, intermittent lethargy, rads-lesion/dilation at pyloric region
SPECIES	ULTRASONOGRAPHIC EXAMINATION OF THE ABDOMEN
Canine	Urinary System
BREED	The urinary bladder, trigone, cystourethral junction, and visible pelvic urethra to a depth of 3.0 cm exhibited normal thickness and tone. Anechoic urine was present in the lumen with no uroliths or sediment. The ureteral papillae were normal. The ureters were not visible which is normal. No evidence of inflammatory or neoplastic changes was noted.
Lab Mix	
SEX	
FS	The area of the aortic trifurcation was free of pathology.
AGE	Normal size and margination were present in the kidneys. A normal 1:3 cortex / medulla ratio was maintained. The medulla and cortices were uniform in texture with some increased echogenicity and mild loss of corticomedullary symmetry and definition expected for the age of the patient. No evidence of pelvic dilation was present. The left kidney measured 6.0 cm in length. The right kidney measured 6.5 cm in length.
11	
WEIGHT	Adrenal Glands
44	The bilateral adrenal glands were normal in size. Mild parenchyma heterogeneity and mild capsule asymmetry was present without suspicion for overt neoplasia. No adrenal tumors were noted. The left adrenal gland measured 1.8 cm length x 0.40 cm width at the caudal pole. The right adrenal gland measured 2.7 cm length x 0.88 cm width at the caudal pole.
INTERPRETED BY	Spleen
R. McKenzie Daniel, DVM, DABVP (Canine and Feline)	The spleen exhibited primarily finely textured parenchyma which was hyperechoic to the liver and renal cortical parenchyma. Mild generalized parenchyma heterogeneity was present. Potential areas of medial capsule fibrosis or medial parenchymal benign myelolipomas possible. The splenic vasculature at the hilus was normal in volume with no evidence of congestion or thrombosis. The parenchymal heterogeneity is likely consistent with benign changes such as extramedullary hematopoiesis or age-related remodeling with minor potential for inflammatory or neoplastic disease.
IMAGING PERFORMED BY	Liver/ Gallbladder
Jenn	The liver was subjectively normal in size, structure, and contour. The liver parenchyma was uniform and hypoechoic to the spleen with a mild coarse echotexture. The hepatic and portal vasculature were normal in appearance without signs of congestion. The gallbladder was non-distended to mildly subnormal in size potentially secondary to the presence of gastric ingesta. A mild amount of variably echogenic nondependent yet nonorganized gallbladder debris without evidence of gallbladder or peripheral gallbladder inflammation was noted. The cystic and common bile ducts were normal.
HOSPITAL NAME	
Rockaway AH	
REFERRING VET	
Dr. Maniar	
INVOICE	Gastrointestinal
15714	The stomach presented intact and sonographically unremarkable visualized wall layering. The stomach contained a moderate amount of echogenic ingesta exhibiting mild progressive distal acoustic
DATE	
12/28/22	



PATIENT	shadowing. No evidence of overt mechanical pyloric outflow obstruction or obstructive pyloric mural pathology. The ventral pylorus body wall width measured 0.40 cm.
Luna Garrity	
SPECIES	The small intestine presented intact wall layering with 1:3 muscularis/mucosa ratio. The lumen of the small intestine was empty with no signs of mechanical / metabolic small intestinal ileus, obstruction, or foreign material. The duodenum wall measured 0.37 cm width.
Canine	
BREED	Normal visible colon wall layers were present with apparent formed feces in lumen.
Lab Mix	
SEX	Pancreas The pancreas was normal in size and contour with isoechoic to heterogeneous parenchyma compared to adjacent omentum. No signs of active inflammation or neoplasia.
FS	Free Abdomen
AGE	No overt lymphadenopathy or peritoneal effusion was present.
11	ULTRASONOGRAPHIC FINDINGS
WEIGHT	<ul style="list-style-type: none"> Intact sonographically unremarkable visualized stomach walls with moderate gastric ingesta exhibiting mild progressive distal acoustic shadowing Sonographically unremarkable small bowel Heterogeneous pancreas - patient / age-related variant, minor benign remodeling, potential for low-grade or chronic pancreatitis possible Age-related kidneys / spleen Nondistended gallbladder with mild luminal debris (non-mucocele)
44	
INTERPRETED BY	INTERPRETATION OF THE FINDINGS & FURTHER RECOMMENDATIONS
R. McKenzie Daniel, DVM, DABVP (Canine and Feline)	The gastric ingesta is nonspecific and may indicate recent meal ingestion. Correlation with the most recent meal is suggested. If documented NPO, the gastric ingesta may suggest some degree of nonobstructive gastric hypomotility.
IMAGING PERFORMED BY	
Jenn	
HOSPITAL NAME	No evidence of intraabdominal or gastrointestinal neoplastic criteria. If documented NPO, hospitalization with as-needed supportive care and sonographic reassessment of the stomach following 12-hour fast to assess gastric emptying could be considered.
Rockaway AH	
REFERRING VET	
Dr. Maniar	
INVOICE	
15714	
DATE	
12/28/22	





PATIENT

Luna Garrity

SPECIES

Canine

BREED

Lab Mix

SEX

FS

AGE

11

WEIGHT

44

INTERPRETED BY

R. McKenzie Daniel,
DVM, DABVP
(Canine and Feline)

IMAGING PERFORMED BY

Jenn

HOSPITAL NAME

Rockaway AH

REFERRING VET

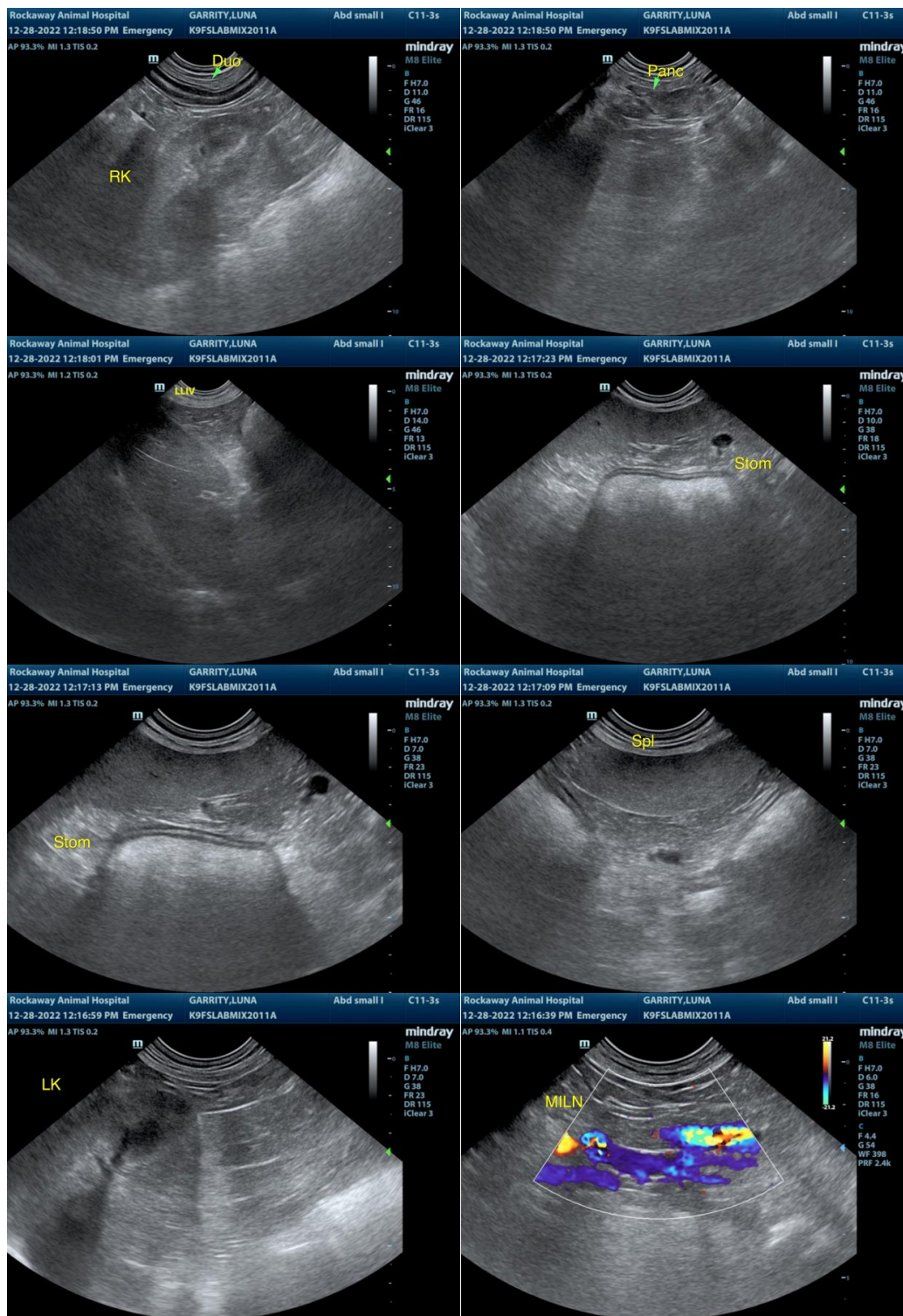
Dr. Maniar

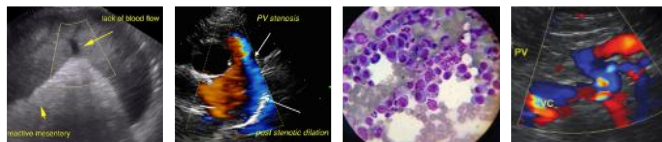
INVOICE

15714

DATE

12/28/22





PATIENT

Luna Garrity

SPECIES

Canine

BREED

Lab Mix

SEX

FS

AGE

11

WEIGHT

44

INTERPRETED BY

R. McKenzie Daniel,
DVM, DABVP
(Canine and Feline)

IMAGING PERFORMED BY

Jenn

HOSPITAL NAME

Rockaway AH

REFERRING VET

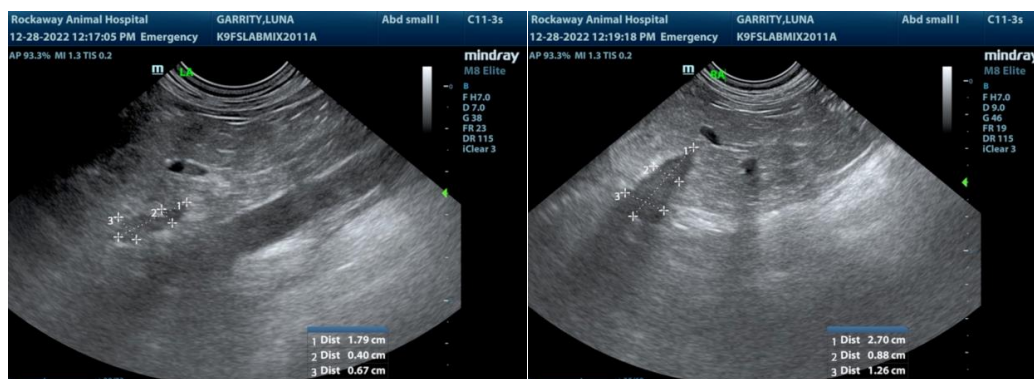
Dr. Maniar

INVOICE

15714

DATE

12/28/22



The information and recommendations provided are based on the images presented by the referring veterinarian/sonographer. No evaluation can be communicated regarding pathology that was not visible in the image/video clips provided.

Thank you for this referral. If the clinical or image interpretation does not parallel your findings or if I can be of any further assistance please contact me.

R. McKenzie Daniel, DVM, DABVP (Canine / Feline Practice)
info@SonoPath.com