

**PATIENT**

Boomer Hammond

SPECIES

Canine

BREED

Yorkie

SEX

NM

AGE

13 years

WEIGHT

9.8 lbs.

INTERPRETED BYR. McKenzie Daniel,
DVM, DABVP
(Canine and Feline)**IMAGING PERFORMED BY**

Sarah Pender, CVT

HOSPITAL NAME

SVS Imaging QC

REFERRING VET

Dr. Hartmann

INVOICE

12903

DATE

12/28/21

PRESENTING CLINICAL SIGNS

Has been increasing PU/PD over last several months. History of bladder stones several years ago and has been on urinary diet every since with no problems. History of chronic cough (suspected tracheal collapse). Treated at ER and another vet clinic for URI in October and cough had improved but is still occasionally coughing.

Abnormal PE/Chem/CBC/UA Results: UA was unremarkable BW - K 3.8 and Na:K ratio 40, everything else in normal range Rads taken at ER in October - hepatomegaly noted.

ULTRASONOGRAPHIC EXAMINATION OF THE ABDOMEN**Urinary System**

The urinary bladder, trigone, cystourethral junction, and visible pelvic urethra to a depth of 2.0 cm exhibited normal thickness and tone. Primarily anechoic urine with mild dependent mineral / sand was present. The ureteral papillae were normal. The ureters were not visible which is normal. No evidence of inflammatory or neoplastic changes was noted.

No overt pathology associated the residual prostate or in the area of the aortic trifurcation.

Normal size and margination were present in the kidneys. A normal 1:3 cortex / medulla ratio was maintained. The medulla and cortices were uniform in texture with some increased echogenicity and mild loss of corticomedullary symmetry and definition expected for the age of the patient. Nonobstructive medullary mineralization primarily in the lateral diverticuli was present in both kidneys but more prominent in the left kidney. No evidence of pyelectasia was present. The left kidney measured 4.2 cm in length. The right kidney measured 4.6 cm in length.

Adrenal Glands

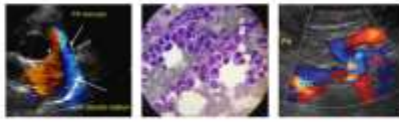Bilateral symmetrical adrenal gland enlargement with uniformly hypoechoic parenchyma was present. The left adrenal gland measured 0.77 cm width at the caudal pole and 0.79 cm width at the cranial pole. The right adrenal gland measured 0.58 cm width at the caudal pole and 0.89 cm width at the cranial pole.

Spleen

The spleen exhibited a finely textured and homogenous parenchyma which was hyperechoic to the liver and renal cortical parenchyma. The capsule was smooth and regular without apparent expansion. The splenic vasculature at the hilus was normal in volume with no evidence of congestion or thrombosis. Acute to chronic inflammatory, neoplastic, or benign parenchyma changes were not noted.

Liver/ Gallbladder

The liver was mild to moderately enlarged with symmetrical contour. The parenchyma of the liver was mildly increased in echogenicity compared to the falciform fat and spleen. The echotexture of the liver parenchyma was uniform with a mild to moderate coarse echotexture. The hepatic and portal vasculature were normal in appearance without signs of congestion. Mild to moderate, nondependent to mildly congealed gallbladder debris was present. No evidence of gallbladder or peripheral inflammation was noted. The cystic and common bile ducts were normal.

**PATIENT*****Gastrointestinal***

Boomer Hammond

The stomach presented intact wall layering with a normal wall layer ratio. Minor retained chyme was present in the pylorus lumen.

SPECIES

Canine

The small intestine presented intact wall layering with 1:3 muscularis/mucosa ratio. The lumen of the small intestine was empty with no signs of ileus, obstruction, or foreign material.

Normal visible colon wall layers were present with apparent formed feces in lumen.

BREED

Yorkie

Pancreas

The parenchyma of the left limb, body, and right limb of the pancreas presented isoechoic to the adjacent omental fat. A normal curvilinear capsule contour of the pancreas was present. The visible pancreatic duct was normal. No signs of active inflammation or neoplastic disease were evident.

SEX

NM

Free Abdomen

No overt lymphadenopathy or peritoneal effusion was present.

AGE

13 years

ULTRASONOGRAPHIC FINDINGS***Primary Findings*****WEIGHT**

9.8 lbs.

- Mild dependent urinary bladder mineral / sand
- Bilateral mild chronic renal changes with nonobstructive medullary mineral - more prominent in the left kidney
- Prominent adrenal glands
- Mild to moderate hepatomegaly - subjectively benign
- Mild to moderate gallbladder debris (non-mucocele)

INTERPRETED BY

R. McKenzie Daniel,
DVM, DABVP
(Canine and Feline)

INTERPRETATION OF THE FINDINGS & FURTHER RECOMMENDATIONS

Even though no reported hepatic enzyme elevations, adrenal work-up is warranted In this patient, given the presentation of the bilateral adrenal glands, liver, and increasing PU/PD. Baseline renal staging including culture / sensitivity and baseline UPC +/- Leptospirosis titers/ PCR if increasing hepatic enzyme elevations going forward, could be considered. Likewise, Denamarin / Ursodiol may be considered if evidence of elevated liver enzymes or cholestasis.

IMAGING PERFORMED BY

Sarah Pender, CVT

HOSPITAL NAME

SVS Imaging QC

REFERRING VET

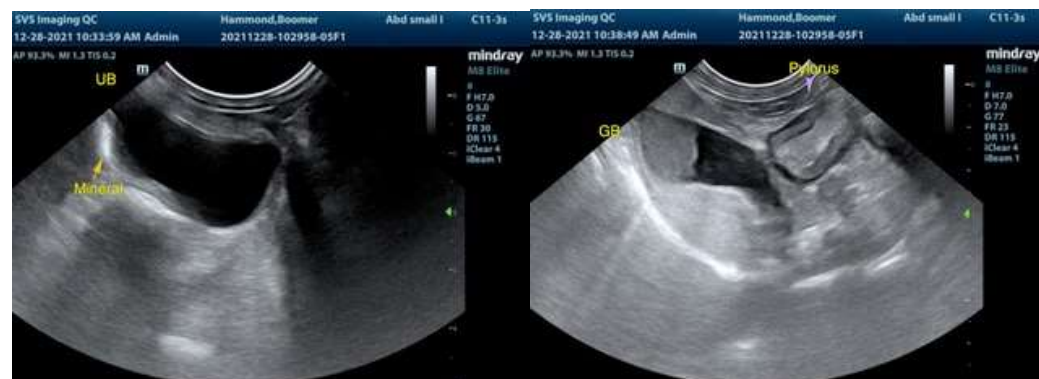Dr. Hartmann

INVOICE

12903

DATE

12/28/21





PATIENT

Boomer Hammond

SPECIES

Canine

BREED

Yorkie

SEX

NM

AGE

13 years

WEIGHT

9.8 lbs.

INTERPRETED BY

R. McKenzie Daniel,
DVM, DABVP
(Canine and Feline)

IMAGING PERFORMED BY

Sarah Pender, CVT

HOSPITAL NAME

SVS Imaging QC

REFERRING VET

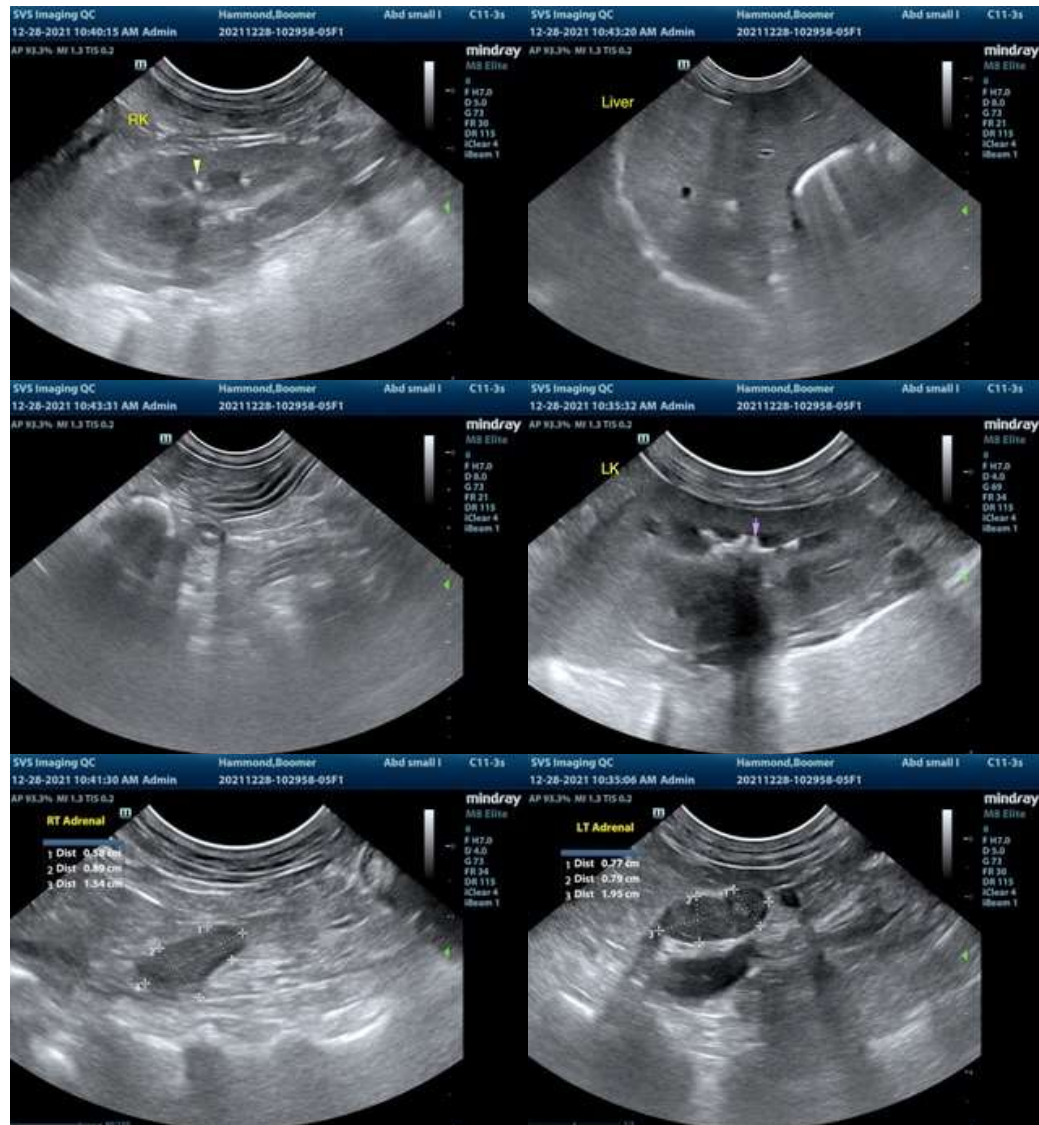
Dr. Hartmann

INVOICE

12903

DATE

12/28/21

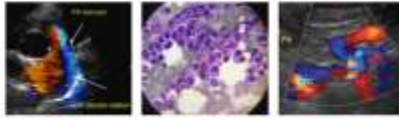

The information and recommendations provided are based on the images presented by the referring veterinarian. No evaluation can be communicated regarding pathology that was not visible in the image/video clips provided.

Thank you for this referral. If the clinical or image interpretation does not parallel your findings or if I can be of any further assistance please contact me.

R. McKenzie Daniel, DVM, DABVP (Canine / Feline Practice)
info@SonoPath.com

Efficient & Accurate Cushing's Work up
Notes regarding Cushing's Clinical Presentations:

**PATIENT**

Boomer Hammond

Nearly all Cushing's dogs have SAP elevations and true PU/PD ($USG < 1.025$) and most are polyphagic. Cushing's dogs are > 6 years and usually > 9 years old, usually have poor skin coats, body scores > 3/5, and are usually sedentary animals.

SPECIES

Canine

Its important to remember that Cushing's dogs usually look and play the part and other diseases cause false + stress related cortisol spikes. On rare occasion a Cushing's dog will not follow the rules but this is truly an exception.

BREED

Yorkie

Potential Cushing's patient workups can be costly and frustrating if not definitive and, in my experience, the non-definitive patient usually has something else going on that may be contributing to some of the clinical signs a Cushing's dog will have, especially SAP elevations or PU/PD. Based on this prelude of information I came up with the following algorithm in the spirit of diagnostic efficiency.

The following suggested protocol is based on current available literature on Cushing's disease and extensive clinical-sonographic experience evaluation + Cushing's and False + LDDST & ACTH stim. cases in order to maximize the efficiency of a Cushing's workup in practice.

SEX

NM

Screen first, workup second

1) **UA:** Repeatable (2-3 urine samples) Urine specific gravity & urine cortisol/creatinine ratio (UCCR): If **repeatable USG < 10.20 and + UCCR** move to next step 2.

AGE

13 years

Note: UA is inexpensive and easy to obtain and if UA criteria is not met for Cushing's then resources can be spent into other more pertinent diagnostics or left on hold until the UA criteria is met in emerging Cushing's cases.

WEIGHT

9.8 lbs.

2) **Sonogram:** Does the patient **have concurrent disease** clinically or sonographically as non-Cushing's illness will influence the potential false + LDDST or even ACTH stim. The sonogram gives a global perspective of the internal health of the patient to be considered in the Cushing's workup as an assessment of concurrent disease. Is there a concurrent neoplastic process, UTI pancreatitis, mucocele....? Are the adrenals enlarged (Cushing's-PDH, stress, age related or breed variant), or atrophied (iatrogenic Cushing's or adrenal burnout), have asymmetric enlargement (Adrenal tumor, hyperplasia, adenoma, age related variant), or is there vascular invasion (Invasive pheo with false + UA criteria or adenocarcinoma or phrenic thrombosis)? The sonogram answers these questions proactively.

Address & treat concurrent disease first before performing Cushing's testing or testing will be artificially altered increasing false negatives and positives.

INTERPRETED BY

R. McKenzie Daniel,
DVM, DABVP
(Canine and Feline)

3) **LDDST** (0.01 D-Sodium phosphate mg/kg IV **with precise dosing******) (Better screening test but plagued with false + but considered more specific than ACTH stim) Use if there is potential early Cushing's or if adrenal asymmetry present on sonogram suspecting tumor. Use LDDST in cats at a higher dose (0.1 mg/kg IV). **Interpretation LDDST:** Look at 8-hour post first: If > 1.4 = Cushing's. Then look at 4-hour: if > 1.4 or > 50% baseline = Cushing's. 4-hour do then 8-hour spike most consistent with PDH. Flat line high constant curve without dip more consistent with tumor but can be PDH. See attached graph.

IMAGING PERFORMED BY

Sarah Pender, CVT

HOSPITAL NAME

SVS Imaging QC

REFERRING VET

Dr. Hartmann

INVOICE

12903

DATE

12/28/21



PATIENT

Boomer Hammond

SPECIES

Canine

BREED

Yorkie

SEX

NM

AGE

13 years

WEIGHT

9.8 lbs.

INTERPRETED BY

R. McKenzie Daniel,
DVM, DABVP
(Canine and Feline)

IMAGING PERFORMED BY

Sarah Pender, CVT

HOSPITAL NAME

SVS Imaging QC

REFERRING VET

Dr. Hartmann

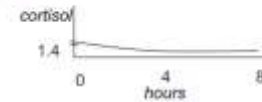
INVOICE

12903

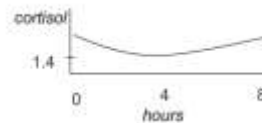
DATE

12/28/21


LDDS



Normal dogs



PDH



Adrenal Tumor
35% PDH

Courtesy: Rebecca Berg DACVIM, DECVIM

4) **ACTH stim.** (Better confirming test but can have false +) Use if the patient "looks" Cushingoid or if bilateral adrenal enlargement is present, or high normal width on sonogram, or if iatrogenic Cushing's suspected (Cortisone Tx in past). ACTH stim is better for diagnosis of Addison's, iatrogenic Cushing's, and Cushing's therapy monitoring but problematic with initial Cushing's diagnosis. First dx LDDST is suggested.

5) If **diabetic** then run both LDDST & ACTH stim but stabilize as much as possible first.

5) Run a **serial blood pressure** in a BP friendly non "white coat effect" atmosphere. Run at least 3 at different times over a few hours or when eating as the patient tends to be calm when eating or give Torbutrol when entering the facility. Cushing's hypertension is usually 150-180 systolic range while pheochromocytoma range is more often > 180 systolic.

6) **Perform CT** of the pituitary to identify macro adenoma expansion if any lethargy or dullness or other central clinical CNS signs are minimally present. CT for adrenal may be more thorough for adrenalectomy surgical planning if ultrasound views of the CVC were problematic.

7) **Adrenalectomy** for adrenal mass is prescribed then it is essential to stabilize the patient first regarding secondary disease such as organ dysfunction, hypertension, diabetes mellitus, hypernatremia, thromboembolic risk urinary and other infection in order to minimize potential for operative and postoperative complications as they are common in adrenalectomy. Trilostane stabilization therapy for Cushing's would be the first approach then address surgery and hypertension should be managed ideally < 160 systolic with ace inhibitors, phenoxybenzamine, or amlodipine.

Suggested reading:

Behrend EN, Kooistra HS, Nelson R, et al. Diagnosis of Spontaneous Canine Hyperadrenocorticism: 2012 ACVIM Consensus Statement (Small Animal). J Vet Intern Med 2013;27:1292-1304.