



PATIENT

Laddie Boy Johnson

SPECIES

Canine

BREED

Collie X

SEX

Neutered Male

AGE

7 Years

WEIGHT

75.5 pounds

INTERPRETED BY

R. McKenzie Daniel,
DVM, DABVP (Canine
/ Feline Practice)

IMAGING PERFORMED BY

Sara Hansen

HOSPITAL NAME

Willakenzie Animal
Clinic

REFERRING VET

Dr. Brandt

INVOICE

12837

DATE

12/26/25

PRESENTING CLINICAL SIGNS

Clinical Exam Findings: Not e/d for the last two days. noticeable weight loss. per doctor evidence of copious diarrhea on back end ABNORMAL Labwork Values WBC 22.9 Neutrophils 19.236 ALT 668 AST 169 ALP 2.391 GGT 33 Bilirubin 9.7

Current Medications proviable forte and clindamycin

ULTRASONOGRAPHIC EXAMINATION OF THE ABDOMEN

Urinary System

The urinary bladder, trigone, cystourethral junction, and visible pelvic urethra to a depth of 5.0 cm exhibited normal thickness and tone. Primarily anechoic urine was present in the lumen. Nondependent particulate mild sediment was present without evidence of calculus formation. The ureteral papillae were normal. The ureters were not visible which is normal. No evidence of inflammatory or neoplastic mural changes were noted.

The area of the residual prostate appeared normal and free of pathology.

Normal size and margination was present in the kidneys. A normal 1:3 cortex / medulla ratio and normal corticomedullary definition were maintained. The echogenicity of the cortex was similar to or slightly less than normal liver parenchyma while the medulla echogenicity was hypoechoic to the cortex with no evidence of pelvic dilation. The left kidney measured 7.3 cm in length. The right kidney measured 6.8 cm in length.

Adrenal Glands

The left adrenal gland was uniform in size and contour with a uniformly hypoechoic parenchyma. The left adrenal gland measured 0.73 cm width at the caudal pole.

The right adrenal gland was indistinctly visualized owing to periadrenal lymphadenopathy with no obvious pathology. The right adrenal gland subjectively measured 0.71 cm width at the caudal pole.

Spleen

The spleen presented with normal in size to possible borderline enlargement with areas of asymmetrical medial capsule contour. Homogenous mildly hypoechoic parenchyma with normal vascularity. No mass or nodules were evident.

Liver

The liver presented with generalized hepatomegaly. The hepatic parenchyma revealed diffuse reduced echogenicity compared to the spleen and renal cortical parenchyma with a mild coarse echotexture. Increased portal vein prominence was evident. The capsule of the liver was normal in margination. Distinct masses or nodules were not evident. The hepatic and portal vasculature were normal in appearance.

The gallbladder was non-distended in size with thin walls and primarily anechoic luminal content. The cystic and common bile ducts were normal.

Gastrointestinal



PATIENT

Laddie Boy Johnson

The stomach presented intact wall layering with a normal wall layer ratio. The lumen of the stomach contained echogenic, mild nonshadowing to regional strongly shadowing ingesta or content without signs of obstruction or foreign material.

SPECIES

Canine

The intestinal walls demonstrated intact wall layering and maintained 1:3 muscularis / mucosa ratio. The mucosa exhibited mild decreased echogenicity with occasional mucosal speckling. Mild segmental ileus present without evidence of obstructive pattern.

BREED

Collie X

Normal visible colon wall layers were present with semi formed fecal matter in lumen.

SEX

Neutered Male

Pancreas

The left limb, right limb, and base of the pancreas presented mildly prominent in size with mild capsule asymmetry and mild nonhomogenous hypoechoic parenchyma. No overt evidence of neoplasia.

AGE

7 Years

Free Abdomen

Intermittent mild to variably enlarged nonhomogenous hypoechoic mesenteric and medial iliac lymph nodes were present. Mild perilymphatic to peripancreatic hyperechoic omentum. Example of mesenteric lymph nodes measured 2.7 cm x 1.1 cm. Example of medial iliac lymph nodes measured 4.8 cm x 1.3 cm. No evidence of peritoneal effusion was visualized.

WEIGHT

75.5 pounds

ULTRASONOGRAPHIC FINDINGS

INTERPRETED BY

R. McKenzie Daniel,
DVM, DABVP (Canine
/ Feline Practice)

- Borderline splenomegaly exhibiting hypoechoic parenchyma.
- Large hypoechoic liver.
- Nonspecific gastroenteropathy with strongly shadowing gastric ingesta/content.
- Semi formed fecal matter in colon.
- Suspect possible mild pancreatitis.
- Mild to variable nonhomogenous hypoechoic mesenteric and medial iliac lymphadenopathy.

IMAGING PERFORMED BY

Sara Hansen

INTERPRETATION OF THE FINDINGS & FURTHER RECOMMENDATIONS

Given ultrasound findings, nonspecific to multicentric inflammatory, infectious or neoplastic etiologies are possible with primary concern for multicentric to emerging round cell neoplasia i.e. lymphoma or other. Retained dense gastric ingesta or nonobstructive gastric foreign material is possible.

HOSPITAL NAME

Willakenzie Animal
Clinic

Sonographic monitoring for evidence of persistent retained gastric ingesta or gastric emptying is indicated. Further assessment may include (assuming normal clotting status and using a 25-gauge needle) hepatosplenic and accessible lymph node FNA cytology +/- culture and sensitivity or leptospirosis titers/PCR. Guarded prognosis pending recommended sampling considered essential for further clarification.

REFERRING VET

Dr. Brandt

INVOICE

12837

DATE

12/26/25



PATIENT

Laddie Boy Johnson

SPECIES

Canine

BREED

Collie X

SEX

Neutered Male

AGE

7 Years

WEIGHT

75.5 pounds

INTERPRETED BY

R. McKenzie Daniel,
 DVM, DABVP (Canine
 / Feline Practice)

**IMAGING
 PERFORMED BY**

Sara Hansen

HOSPITAL NAME

Willakenzie Animal
 Clinic

REFERRING VET

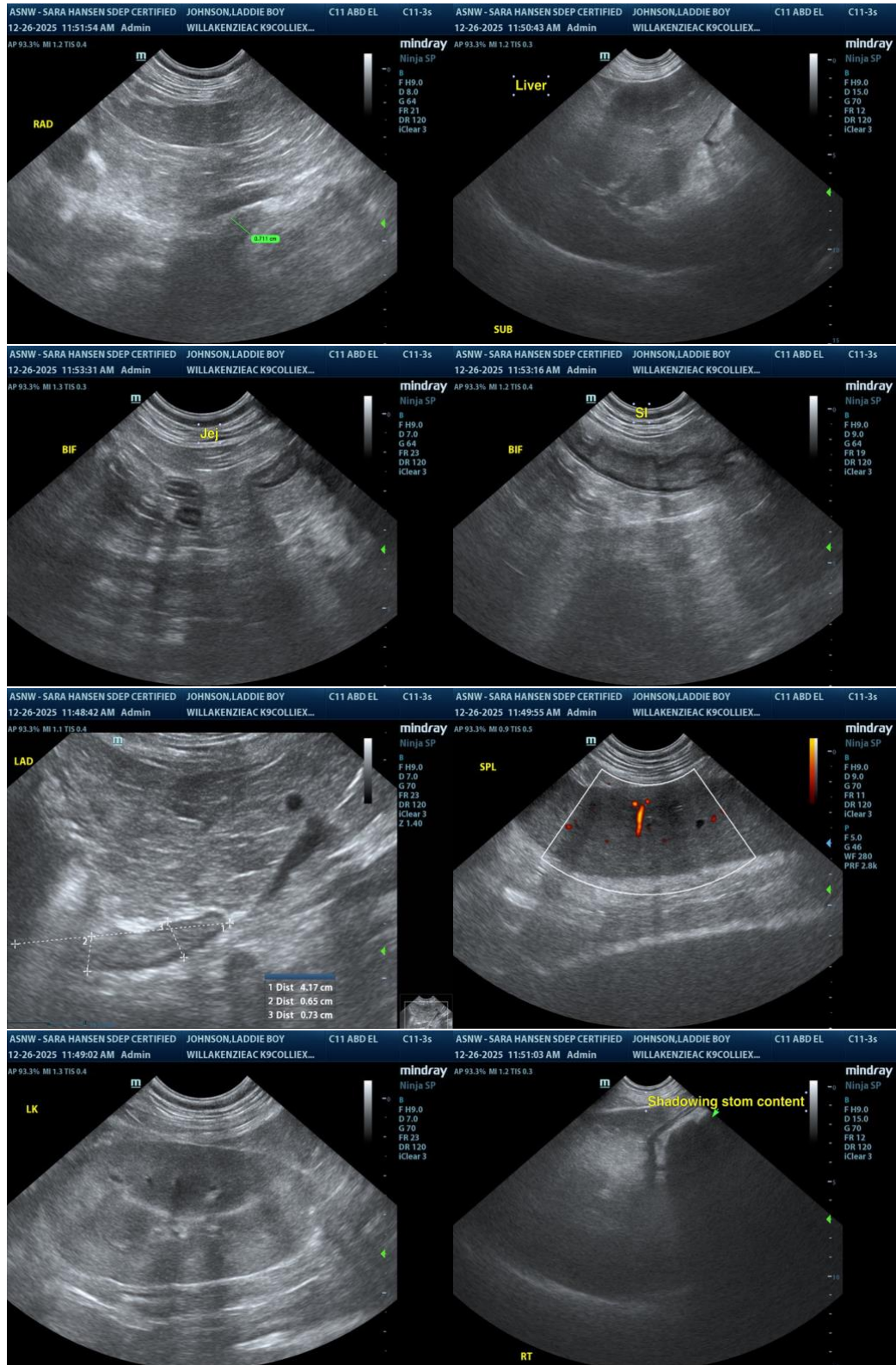
Dr. Brandt

INVOICE

12837

DATE

12/26/25





PATIENT

Laddie Boy Johnson

SPECIES

Canine

BREED

Collie X

SEX

Neutered Male

AGE

7 Years

WEIGHT

75.5 pounds

INTERPRETED BY

R. McKenzie Daniel,
 DVM, DABVP (Canine
 / Feline Practice)

IMAGING PERFORMED BY

Sara Hansen

HOSPITAL NAME

Willakenzie Animal
 Clinic

REFERRING VET

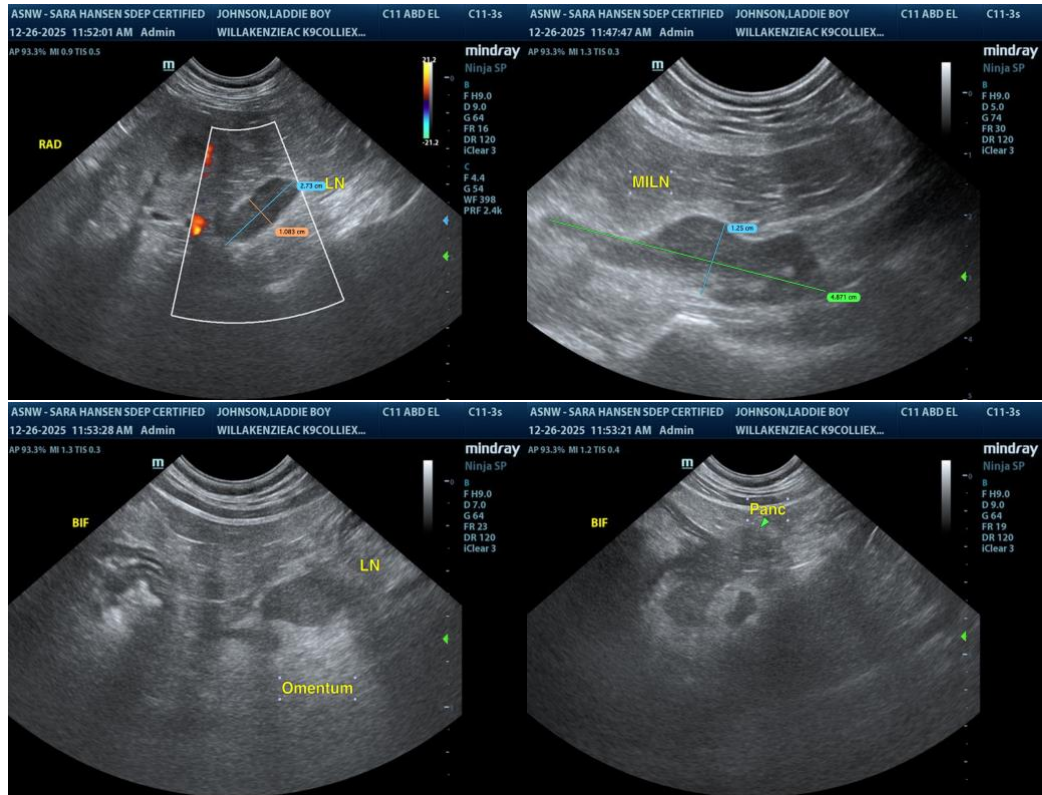
Dr. Brandt

INVOICE

12837

DATE

12/26/25



The information and recommendations provided are based on the images presented by the referring veterinarian/sonographer. No evaluation can be communicated regarding pathology that was not visible in the image/video clips provided.

Thank you for this referral. If the clinical or image interpretation does not parallel your findings or if I can be of any further assistance, please contact me.

R. McKenzie Daniel, DVM, DABVP (Canine / Feline Practice)

info@SonoPath.com