



PATIENT

Nomial Tsang

SPECIES

Canine

BREED

Retriever Mix

SEX

Neutered Male

AGE

9 Years

WEIGHT

30 pounds

INTERPRETED BY

R. McKenzie Daniel,
DVM, DABVP (Canine
/ Feline Practice)

IMAGING PERFORMED BY

Meghan Morse LVT,
CVT

HOSPITAL NAME

Northvale Veterinary
Clinic

REFERRING VET

Dr. Simon

INVOICE

12822

DATE

12/23/25

PRESENTING CLINICAL SIGNS

Abnormal loudness heard on exam, no murmur, no symptoms, needs dental

ULTRASONOGRAPHIC EXAMINATION OF THE HEART

CANINE CARDIAC PARAMETERS	MR VMAX (m/s)	TR VMAX (m/s)	LA/AO (M-Mode)	LA/AO (Heart Base; Swe)	FS (%)	EF (%)	EPSS (cm)
NORMAL PARAMETER	4.5-5.5	<2.7	1.3	Up to 1.6	28-40	40-100	<0.6
PATIENT	--	--	NM	1.4	49	82	0.2
CANINE CARDIAC PARAMETERS	HR (BPM)	AV VMAX (m/s)	PV MAX (m/s)	BODY WEIGHT (kg)	LAD LA MAX 4 Chamber	LVIDd Avg; 2D and m-mode short axis (cm)	LVIDs Avg; 2D and m-mode short axis (cm)
NORMAL PARAMETER	50-100	0.7-1.7	0.7-1.6				
PATIENT	NM	1.5	1.4	--	2.3	2.4	--

Cardiac Presentation

The echocardiogram in this patient demonstrated normal **left atrial** dimension based on 2 separate methods of LA evaluation. The cranial and caudal **mitral** valve leaflets presented normal linear structure, extension in systole, and union in diastole with normal kinesis. No obvious significant MR on doppler. The **left ventricle** presented thicknesses with linear contour and was not dilated nor restricted. The **myocardium** presented normal echogenicity without subjective evidence of significant fibrotic or ischemic disease. **Contractility** of the ventricular walls was adequate and in normal range for this patient evidenced by the fractional shortening measurement and subjective evaluation of the different regions of the myocardium. The **left ventricular outflow** tract demonstrated normal laminar flow and subjective structural integrity. Normal measured LVOT velocity. The **right atrium** and auricle revealed normal size, structure and content. No evidence of masses was noted. **Tricuspid** valvular assessment demonstrated adequate linear morphology and kinesis. No overt TR on doppler. The **right ventricle** was of normal size (1/3 diameter of LV), chordae structure, myocardial echogenicity and thickness. **Pulmonary outflow** tract assessment revealed normal valve structure, laminar flow, and diameter (approx.1:1 pa/ao ratio). Normal measured RVOT velocity. No visible **pericardial** or free pleura fluid was noted. The cranial **mediastinum and pericardial and extra-cardiac regions** were free of masses in the visible window. Possible tachycardia without overt arrhythmia.

ULTRASONOGRAPHIC FINDINGS

- Normal cardiac structure/function.

INTERPRETATION OF THE FINDINGS & FURTHER RECOMMENDATIONS



PATIENT

Nomial Tsang

SPECIES

Canine

BREED

Retriever Mix

SEX

Neutered Male

AGE

9 Years

WEIGHT

30 pounds

INTERPRETED BY

R. McKenzie Daniel, DVM, DABVP (Canine / Feline Practice)

IMAGING PERFORMED BY

Meghan Morse LVT, CVT

HOSPITAL NAME

Northvale Veterinary Clinic

REFERRING VET

Dr. Simon

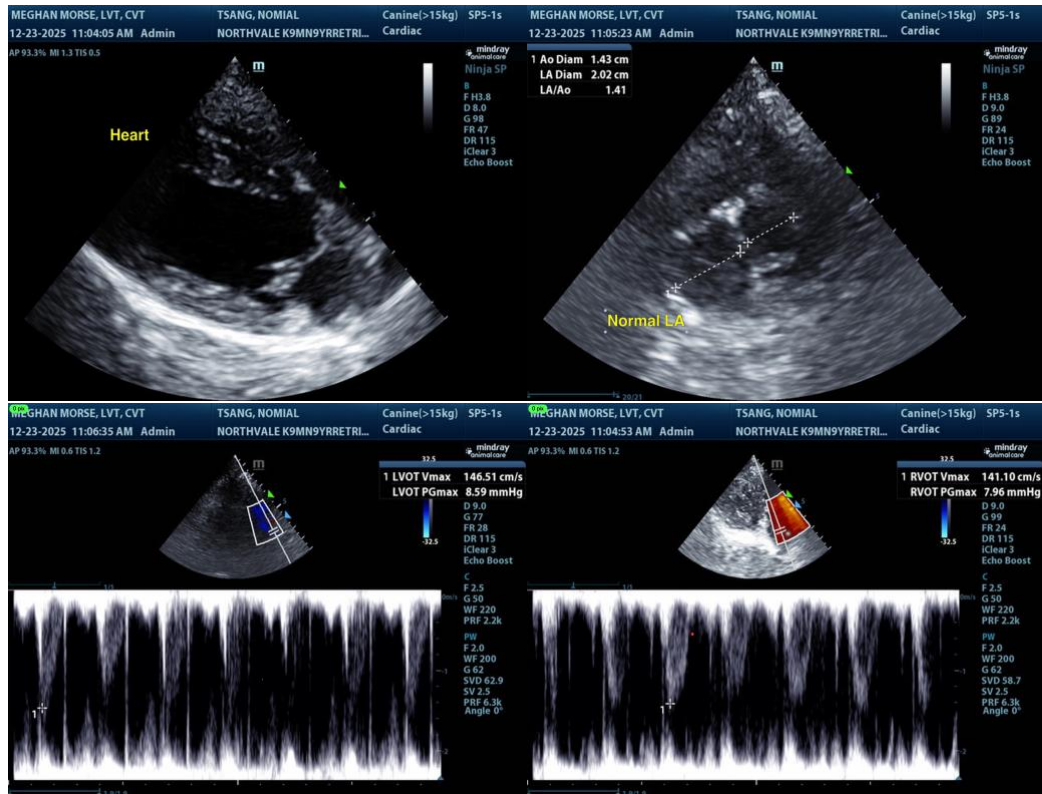
INVOICE

12822

DATE

12/23/25

No evidence of clinical issues such as left or right heart chamber enlargement, LV systolic dysfunction, overt significant valvular insufficiencies or pulmonary hypertension. A definitive cause of possible sound abnormality was not obvious. ECG is indicated if evidence of confirmed or persistent tachycardia. No indication for cardiac medications or overt anesthetic contraindications. Suggested anesthetic protocol may include opioid or Benzodiazepine pre-med, induction with Propofol or Alfaxalone, and appropriate gas anesthesia with avoidance of alpha 2 agonists.



The information and recommendations provided are based on the images presented by the referring veterinarian/sonographer. No evaluation can be communicated regarding pathology that was not visible in the image/video clips provided.

Thank you for this referral. If the clinical or image interpretation does not parallel your findings or if I can be of any further assistance, please contact me.

R. McKenzie Daniel, DVM, DABVP (Canine / Feline Practice)

info@SonoPath.com