



**PATIENT**

Josephine Hauser

**SPECIES**

Feline

**BREED**

Persian

**SEX**

Spayed Female

**AGE**

10 Years

**WEIGHT**

7.54 pounds

**INTERPRETED BY**

R. McKenzie Daniel,  
DVM, DABVP (Canine  
/ Feline Practice)

**IMAGING  
PERFORMED BY**

Pamela Harrigan,  
RDCE

**HOSPITAL NAME**

Falmouth Animal  
Hospital

**REFERRING VET**

Dr. Lilan Hauser DVM

**INVOICE**

12826

**DATE**

12/23/25

**PRESENTING CLINICAL SIGNS**

Addendum to previous report read 12/10/25 by Beth Johnson, DVM, DACVIM.

Additional images to complete the study done on December 10, 2025. Study limited to the intestines.

**LIMITED ULTRASONOGRAPHIC EXAMINATION**

**Gastrointestinal**

The stomach presented intact wall layering with a normal wall layer ratio. The lumen of the stomach contained echogenic, mild focal progressively shadowing ingesta without evidence of mechanical pyloric outflow obstruction.

The intestinal walls demonstrated intact wall layers with diffusely thickened walls and altered to borderline inverted 1:3 muscularis / mucosa ratio owing to primarily thickened muscularis layer. Mildly prominent submucosa layer. The small intestine contains segmental mild nonshadowing ingesta without mechanical obstructive pattern to the level of the colon. The jejunum wall measured 0.30 cm width. The ileocolic wall measured 0.38 cm width.

Normal visible colon wall layers were present with formed to semi formed fecal matter in lumen.

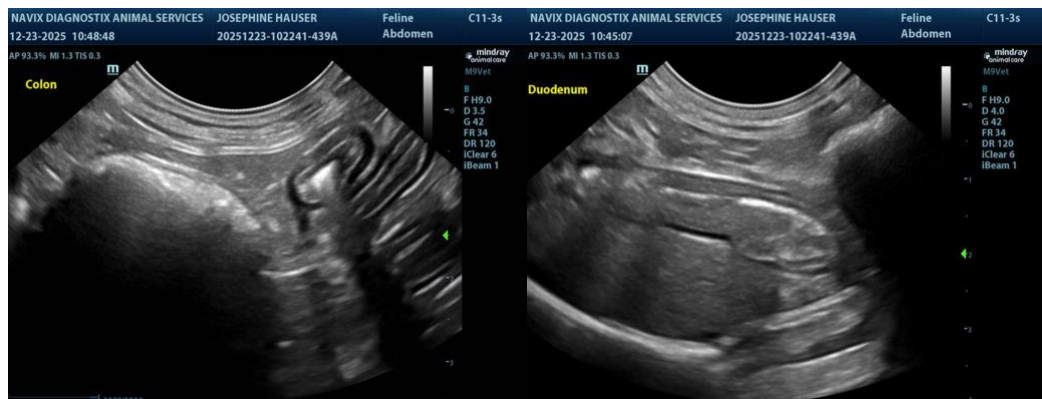No obvious visualized significantly swollen mesenteric lymphadenopathy.

**ULTRASONOGRAPHIC FINDINGS**

- Intact thickened small intestine wall with mild gastrointestinal ingesta.

**INTERPRETATION OF THE FINDINGS & FURTHER RECOMMENDATIONS**

Considerations for the thickened small intestine may include IBD, eosinophilic enteritis or other inflammatory enteropathy, round cell neoplasia such as lymphoma, mast cell neoplasia or considered less likely, granulomatous enteropathy. A definitive diagnosis would require intestinal biopsies for histopathology. A GI panel to include PLI, TLI, cobalamin and folate and if not done, three view chest radiographs for further clarification of small intestine and to rule out thoracic pathology given ongoing weight loss.





**PATIENT**

Josephine Hauser

**SPECIES**

Feline

**BREED**

Persian

**SEX**

Spayed Female

**AGE**

10 Years

**WEIGHT**

7.54 pounds

**INTERPRETED BY**

R. McKenzie Daniel,  
DVM, DABVP (Canine  
/ Feline Practice)

**IMAGING  
PERFORMED BY**

Pamela Harrigan,  
RDMS

**HOSPITAL NAME**

Falmouth Animal  
Hospital

**REFERRING VET**

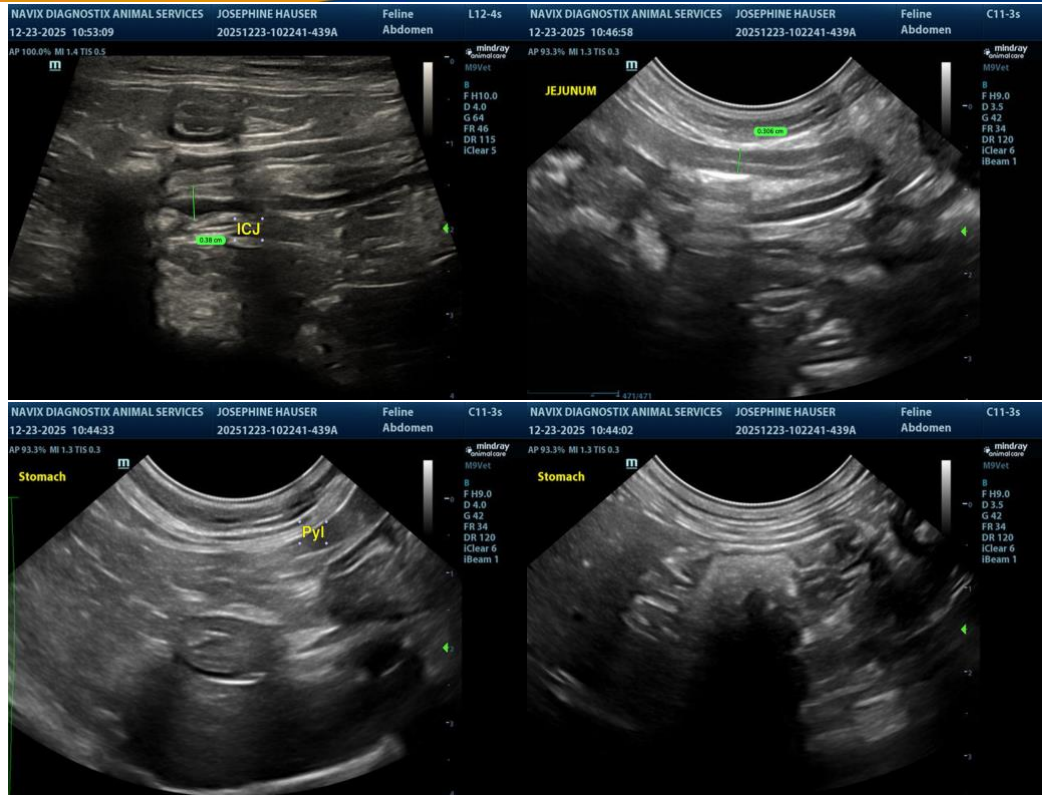
Dr. Lilan Hauser DVM

**INVOICE**

12826

**DATE**

12/23/25



The information and recommendations provided are based on the images presented by the referring veterinarian/sonographer. No evaluation can be communicated regarding pathology that was not visible in the image/video clips provided.

Thank you for this referral. If the clinical or image interpretation does not parallel your findings or if I can be of any further assistance, please contact me.

R. McKenzie Daniel, DVM, DABVP (Canine / Feline Practice)

[info@SonoPath.com](mailto:info@SonoPath.com)