# SonoPath
*Clinical Sonography & Telecytology*

EDUCATIONAL TELECONSULTATION SERVICES™

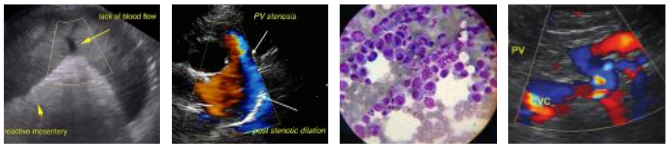


SonoPath.com™
1-800-838-4268 info@sonopath.com

**PATIENT**
Kato Fabisch

**SPECIES**
Canine

**BREED**
Shih Tzu

**SEX**
MN

**AGE**
10 years

**WEIGHT**
11.5 lbs.

**INTERPRETED BY**
R. McKenzie Daniel, DVM, DABVP (Canine and Feline)

**IMAGING PERFORMED BY**
Kelly Vazquez

**HOSPITAL NAME**
Marsh Hospital for Animals

**REFERRING VET**
Dr. Milwicki

**INVOICE**
15664

**DATE**
12/20/22

## PRESENTING CLINICAL SIGNS

Patient with history of tracheal collapse and seizures, presents for cardiac murmur - coughing more recently.

Current meds: hydrocodone and phenobarbital.
Abnormal PE/Chem/CBC/UA Results: CBC/Chem/T4/Phenobarb level all WNL.

## ULTRASONOGRAPHIC EXAMINATION OF THE HEART & ABDOMEN

| CANINE CARDIAC PARAMETERS | MR VMAX (m/s) | TR VMAX (m/s) | LA/AO (Boon method) | LA/AO (Heart Base; Swe) | FS (%) | EF (%) | EPSS (cm) |
|---|---|---|---|---|---|---|---|
| NORMAL PARAMETER | 4.5-5.5 | <2.7 | 1.3 | <1.3 | 28-40 | 40-100 | <0.6 |
| PATIENT | 5.2 | 1.0 | | 1.7 | 43 | 78 | 0.27 |
| **CANINE CARDIAC PARAMETERS** | **HR** (BPM) | **AV VMAX** (m/s) | **PV MAX** (m/s) | **BODY WEIGHT** (kg) | **LA** 2D short axis Base view (cm) | **LVIDd** Avg; 2D and m-mode short axis (cm) | **LVIDs** Avg; 2D and m-mode short axis (cm) |
| NORMAL PARAMETER | 50-100 | 0.7-1.7 | 0.7-1.6 | | | | |
| PATIENT | 101 | 1.1 | 0.7 | | 3.2 | 2.8 | |

### *Cardiac Presentation*

The echocardiogram in this patient demonstrated mildly enlarged **left atrial** size based on 3 different LA measurement methods. The cranial and caudal **mitral** valve leaflets presented mild to moderate thickening consistent with endocardiosis. No evidence of valvular prolapse. Doppler indicated measurable mild to moderate eccentric insufficiency. The **left ventricle** presented thicknesses with linear contour with mild increased LV volume. The **myocardium** presented normal echogenicity without subjective evidence of significant fibrotic or ischemic disease. **Contractility** of the ventricular walls was adequate and in normal range for this patient evidenced by the fractional shortening measurement and subjective evaluation of the different regions of the myocardium. The **left ventricular outflow** tract demonstrated normal laminar flow and subjective structural integrity. The **right atrium** and auricle revealed normal size, structure and content. No evidence of masses was noted or chamber overload. **Tricuspid** valvular assessment demonstrated adequate linear morphology with subjective mild thickening. Mild TR was present on Doppler. The **right ventricle** was of normal size (1/3 diameter of LV), chordae structure, myocardial echogenicity and thickness. **Pulmonic** tract assessment revealed normal valve structure, laminar flow, and diameter (approx.1:1 pa/ao ratio). No visible **pericardial** or free pleura fluid was noted. No echographically detectable evidence of infiltrative disease was visible. The cranial **mediastinum and pericardial regions** were free of masses in the visible window. No arrhythmia was noted.

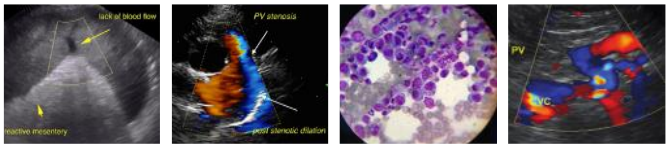


SonoPath.com™
1-800-838-4268 info@sonopath.com

**PATIENT**
Kato Fabisch

**SPECIES**
Canine

**BREED**
Shih Tzu

**SEX**
MN

**AGE**
10 years

**WEIGHT**
11.5 lbs.

**INTERPRETED BY**
R. McKenzie Daniel, DVM, DABVP (Canine and Feline)

**IMAGING PERFORMED BY**
Kelly Vazquez

**HOSPITAL NAME**
Marsh Hospital for Animals

**REFERRING VET**
Dr. Milwicki

**INVOICE**
15664

**DATE**
12/20/22

## *Urinary System*

The urinary bladder, trigone, cystourethral junction, and visible pelvic urethra to a depth of 2.0 cm exhibited normal thickness and tone. Anechoic urine was present in the lumen with no uroliths or sediment. The ureteral papillae were normal. The ureters were not visible which is normal. No evidence of inflammatory or neoplastic changes was noted.

The residual prostate was free of pathology.

The area of the aortic trifurcation was free of pathology.

Normal size and margination were present in the kidneys. A normal 1:3 cortex / medulla ratio was maintained. The medulla and cortices were uniform in texture with some increased echogenicity and mild loss of corticomedullary symmetry and definition expected for the age of the patient. No evidence of pelvic dilation was present. The left kidney measured 3.3 cm in length. The right kidney measured 3.3 cm in length.

## *Adrenal Glands*

The left adrenal gland was uniform in size and contour with a uniformly hypoechoic parenchyma. The left adrenal gland measured 0.34 cm width at the caudal pole and 0.34 cm width at the cranial pole. The right adrenal gland was uniform in size and contour with a uniformly hypoechoic parenchyma. The right adrenal gland measured 0.33 cm width at the caudal pole and 0.30 cm width at the cranial pole.

## *Spleen*

The spleen exhibited a finely textured and homogenous parenchyma which was hyperechoic to the liver and renal cortical parenchyma. The capsule was smooth and regular without apparent expansion. The splenic vasculature at the hilus was normal in volume with no evidence of congestion or thrombosis. Acute to chronic inflammatory, neoplastic, or benign parenchyma changes were not noted.

## *Liver/ Gallbladder*

The liver was subjectively normal in size, structure, and contour. The liver parenchyma was uniform and hypoechoic to the spleen with a mild coarse echotexture. The hepatic and portal vasculature were normal in appearance without signs of hepatic congestion. Normal appearance to the cranial abdominal caudal vena cave without evidence of congestion. The gallbladder was non-distended in size with thin walls and primarily anechoic luminal content. The cystic and common bile ducts were normal.

## *Gastrointestinal*

The stomach presented intact wall layering with a normal wall layer ratio. The lumen of the stomach was empty with no signs of ileus, obstruction, or foreign material.

The small intestine presented intact wall layering with 1:3 muscularis/mucosa ratio. The lumen of the small intestine was empty with no signs of ileus, obstruction, or foreign material.

Normal visible colon wall layers were present with apparent formed feces in lumen.

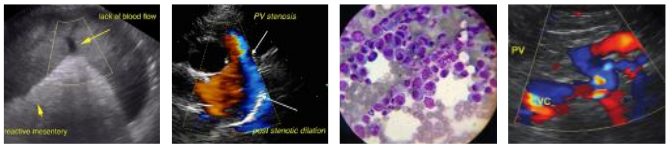


SonoPath.com™
1-800-838-4268 info@sonopath.com

**PATIENT**

Kato Fabisch

**SPECIES**

Canine

**BREED**

Shih Tzu

**SEX**

MN

**AGE**

10 years

**WEIGHT**

11.5 lbs.

**INTERPRETED BY**

R. McKenzie Daniel, DVM, DABVP (Canine and Feline)

**IMAGING PERFORMED BY**

Kelly Vazquez

**HOSPITAL NAME**

Marsh Hospital for Animals

**REFERRING VET**

Dr. Milwicki

**INVOICE**

15664

**DATE**

12/20/22

### *Pancreas*

The parenchyma of the left limb, body, and right limb of the pancreas presented isoechoic to the adjacent omental fat. A normal curvilinear capsule contour of the pancreas was present. The visible pancreatic duct was normal. No signs of active inflammation or neoplastic disease were evident.

### *Free Abdomen*

No overt lymphadenopathy or peritoneal effusion was present.

### ULTRASONOGRAPHIC FINDINGS

- Chronic mitral valve disease (ACVIM mild to early B2)
- Mild TR - estimated pulmonary pressure gradient not consistent with clinical pulmonary hypertension
- Sonographically normal abdomen

### INTERPRETATION OF THE FINDINGS & FURTHER RECOMMENDATIONS

The mild increased LA/LV size suggests that the risk for current and future complications secondary to MR is mildly elevated yet overall, the heart appears to be compensated. No additional clinical issues such as LV systolic dysfunction or evidence of clinical pulmonary hypertension. The cardiac presentation is not consistent with overt cardiogenic component to the patient's coughing. Primary upper or lower airway disease, given the patient history, is likely.

In light of mild LA/LV enlargement, without evidence of significant increased changes or sizes, no overt indication for cardiac medications. However, Pimobendan 0.3 mg/kg PO BID at this stage is warranted, as this medication may help prolong cardiac changes associated with MR. Cardiac prognosis is highly variable and serial sonographic monitoring is recommended. Recheck echocardiogram is suggested in 6 months, sooner if clinical signs suggestive of cardiac disease i.e., increased resting respiration rate, exercise intolerance, syncope, etc., arise.

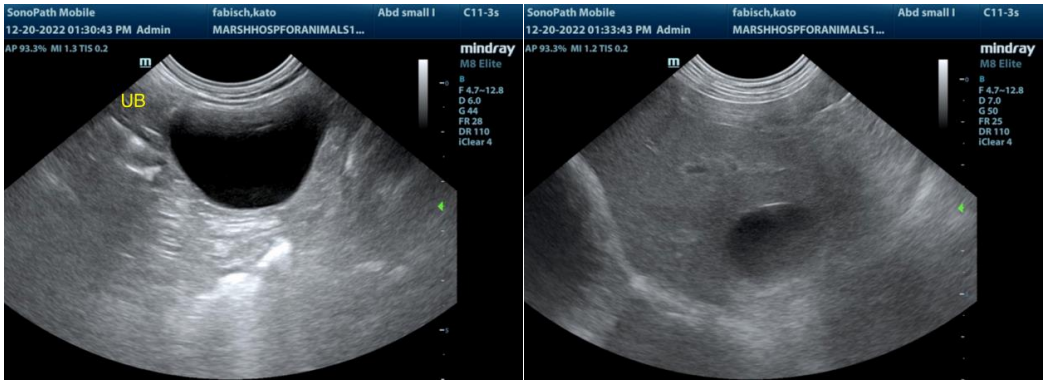

# SonoPath

*Clinical Sonography & Telecytology*

EDUCATIONAL TELECONSULTATION SERVICES™

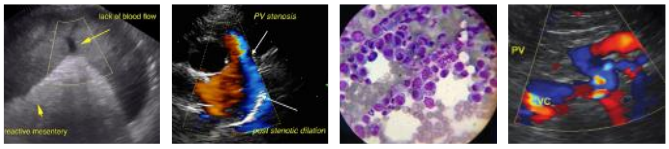


SonoPath.com™
1-800-838-4268 info@sonopath.com

**PATIENT**

Kato Fabisch

**SPECIES**

Canine

**BREED**

Shih Tzu

**SEX**

MN

**AGE**

10 years

**WEIGHT**

11.5 lbs.

**INTERPRETED BY**

R. McKenzie Daniel, DVM, DABVP (Canine and Feline)

**IMAGING PERFORMED BY**

Kelly Vazquez

**HOSPITAL NAME**

Marsh Hospital for Animals

**REFERRING VET**

Dr. Milwicki

**INVOICE**

15664

**DATE**

12/20/22

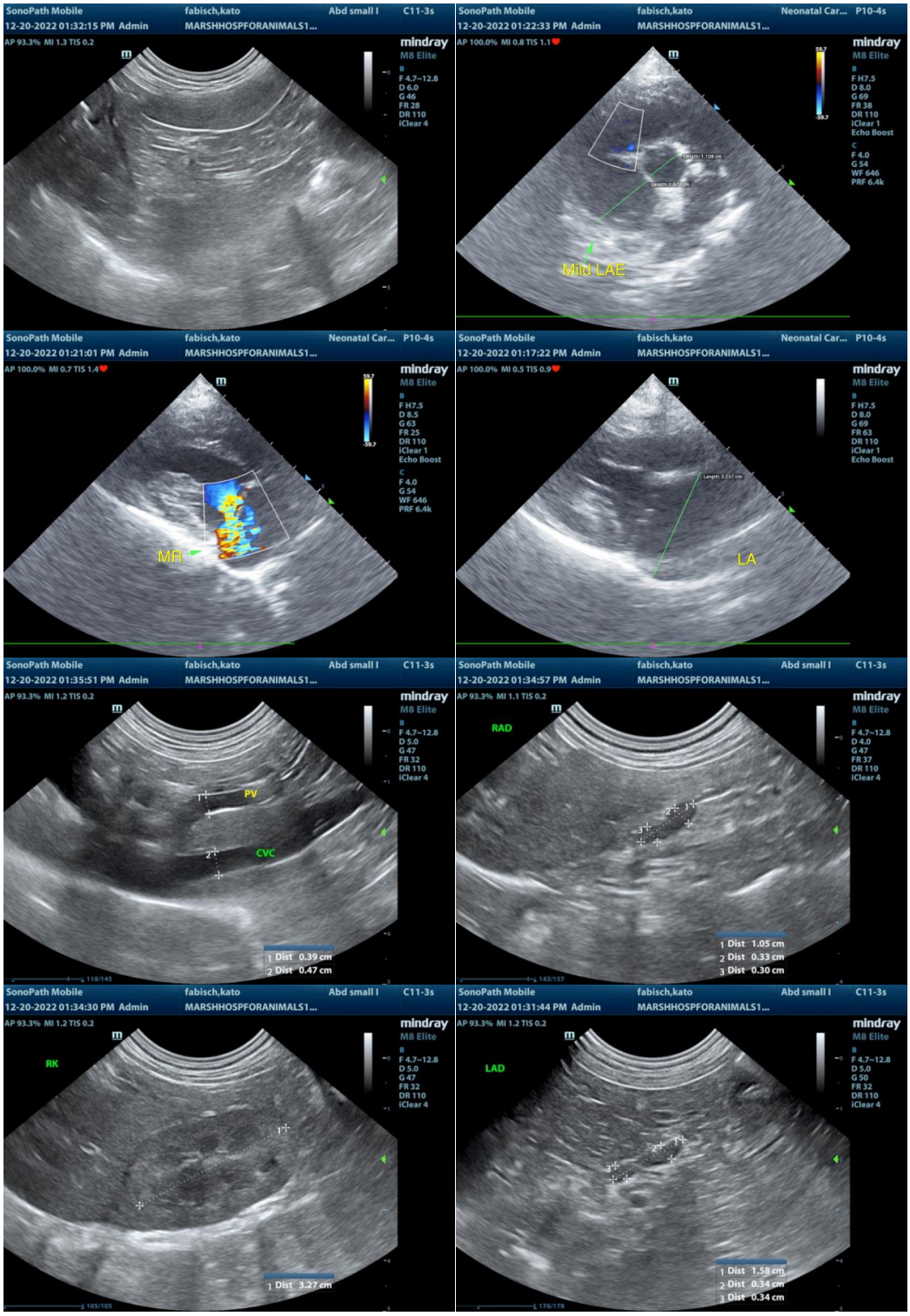

# SonoPath
*Clinical Sonography & Telecytology*

EDUCATIONAL TELECONSULTATION SERVICES™

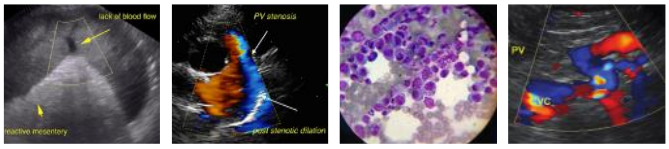


SonoPath.com™
1-800-838-4268 info@sonopath.com

**PATIENT**

Kato Fabisch

**SPECIES**

Canine

**BREED**

Shih Tzu

**SEX**

MN

**AGE**

10 years

**WEIGHT**

11.5 lbs.

**INTERPRETED BY**

R. McKenzie Daniel, DVM, DABVP (Canine and Feline)

**IMAGING PERFORMED BY**

Kelly Vazquez

**HOSPITAL NAME**

Marsh Hospital for Animals

**REFERRING VET**

Dr. Milwicki

**INVOICE**

15664

**DATE**

12/20/22

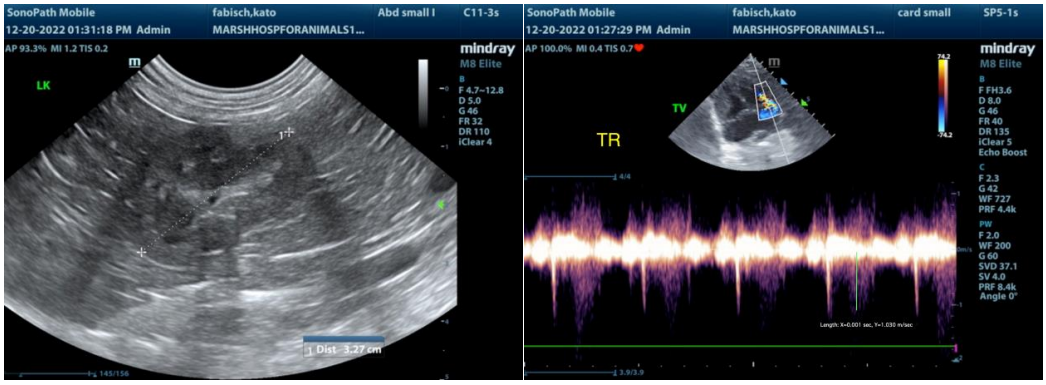


**The information and recommendations provided are based on the images presented by the referring veterinarian/sonographer. No evaluation can be communicated regarding pathology that was not visible in the image/video clips provided.**

Thank you for this referral. If the clinical or image interpretation does not parallel your findings or if I can be of any further assistance please contact me.

**R. McKenzie Daniel, DVM, DABVP (Canine / Feline Practice)**
**info@SonoPath.com**