SonoPath
Clinical Sonography & Telecytology

EDUCATIONAL TELECONSULTATION SERVICES™

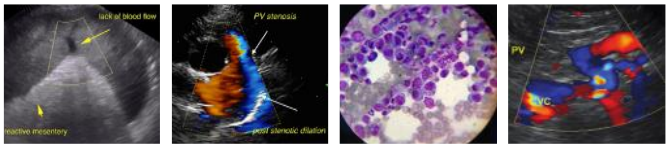

SonoPath.com™
1-800-838-4268 info@sonopath.com

PATIENT

Herman Dunn

SPECIES

Czanine

BREED

Bull Terrier

SEX

MN

AGE

8 yr

WEIGHT

60 lbs.

INTERPRETED BY

R. McKenzie Daniel, DVM, DABVP (Canine and Feline)

IMAGING PERFORMED BY

A. Rodriguez

HOSPITAL NAME

Foxfield VS

REFERRING VET

A. Rodriguez

INVOICE

15665

DATE

12/20/22

PRESENTING CLINICAL SIGNS

Seen 2 days ago at referral hospital for vomiting. Improved since then.
Abnormal PE/Chem/CBC/UA Results: N/A

ULTRASONOGRAPHIC EXAMINATION OF THE ABDOMEN

Urinary System

The urinary bladder, trigone, cystourethral junction, and visible pelvic urethra to a depth of 3.0 cm exhibited normal thickness and tone. Anechoic urine was present in the lumen with no uroliths or sediment. The ureteral papillae were normal. The ureters were not visible which is normal. No evidence of inflammatory or neoplastic changes was noted.

The residual prostate was free of pathology.

The area of the aortic trifurcation was free of pathology.

Normal size and margination were present in the kidneys. A normal 1:3 cortex / medulla ratio and normal corticomedullary definition were maintained. The echogenicity of the cortex was similar to or slightly less than normal liver parenchyma while the medulla echogenicity was hypoechoic to the cortex with no evidence of pelvic dilation. The left kidney measured 6.9 cm in length. The right kidney measured 6.4 cm in length.

Adrenal Glands

The bilateral adrenal glands were overtly normal in size, position, and shape. The left adrenal gland measured 2.4 cm length x 0.58 cm width at the caudal pole. The right adrenal gland measured 2.9 cm length x 0.62 cm width at the caudal pole.

Spleen

The spleen exhibited a finely textured and homogenous parenchyma which was hyperechoic to the liver and renal cortical parenchyma. The capsule was smooth and regular without apparent expansion. The splenic vasculature at the hilus was normal in volume with no evidence of congestion or thrombosis. Acute to chronic inflammatory, neoplastic, or benign parenchyma changes were not noted.

Liver/ Gallbladder

The liver was subjectively normal in size, structure, and contour. The liver parenchyma was uniform and hypoechoic to the spleen with a mild coarse echotexture. The hepatic and portal vasculature were normal in appearance without signs of congestion. The gallbladder was non-distended in size containing primarily anechoic content with mild, dependent to non-dependent, nonorganized, echogenic gallbladder debris. No evidence of gallbladder or peripheral gallbladder inflammation was noted. The cystic and common bile ducts were normal.

Gastrointestinal

The stomach presented intact wall layering with a normal wall layer ratio. The stomach contained a minor amount of ingesta / chyme and luminal gas. No evidence of mechanical pyloric outflow obstruction or gastric foreign material was noted.

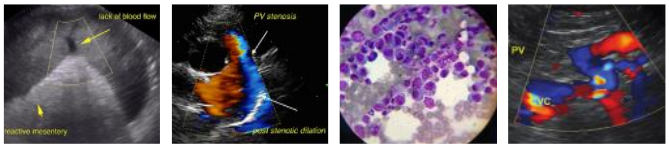

SonoPath.com™
1-800-838-4268 info@sonopath.com

PATIENT

Herman Dunn

SPECIES

Czanine

BREED

Bull Terrier

SEX

MN

AGE

8 yr

WEIGHT

60 lbs.

INTERPRETED BY

R. McKenzie Daniel, DVM, DABVP (Canine and Feline)

IMAGING PERFORMED BY

A. Rodriguez

HOSPITAL NAME

Foxfield VS

REFERRING VET

A. Rodriguez

INVOICE

15665

DATE

12/20/22

The small intestine presented intact wall layering with 1:3 muscularis/mucosa ratio. The small intestine exhibited possible minor duodenal ileus exhibited by mild duodenal luminal fluid. No evidence of mechanical small intestinal obstructive pattern or intestinal foreign material.

The colon exhibited intact, sonographically unremarkable wall layering. The proximal colon contained non-formed fecal matter and luminal gas.

Pancreas

The parenchyma of the left limb, body, and right limb of the pancreas presented isoechoic to the adjacent omental fat. A normal curvilinear capsule contour of the pancreas was present. The visible pancreatic duct was normal. No signs of active inflammation or neoplastic disease were evident.

Free Abdomen

No overt lymphadenopathy or peritoneal effusion was present.

ULTRASONOGRAPHIC FINDINGS

- Mild gastroenteritis pattern - suspect resolving
- Non-formed fecal matter proximal colon

INTERPRETATION OF THE FINDINGS & FURTHER RECOMMENDATIONS

No evidence of significant visceral pathology including no evidence of gastroenterocolic mural changes, obstructive pattern, or gastrointestinal foreign material.

Continued supportive care for gastroenteritis should prove beneficial with potential monitoring for developing soft stool or diarrhea. A GI panel to include PLI/TLI/Cobalamin/Folate and resting cortisol level may be considered if persistent or recurring gastrointestinal signs.

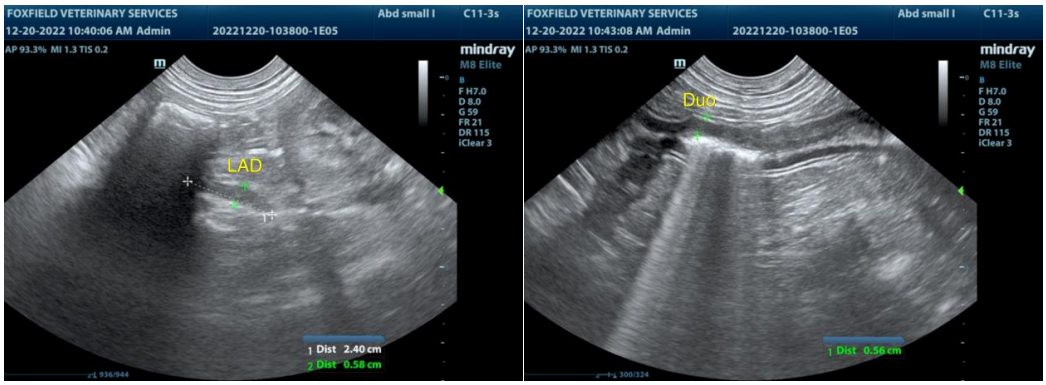

SonoPath

Clinical Sonography & Telecytology

EDUCATIONAL TELECONSULTATION SERVICES™

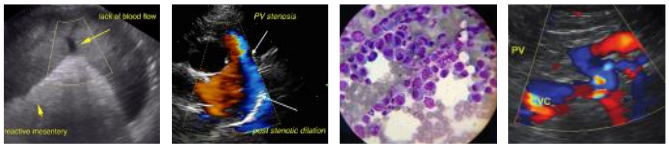

SonoPath.com™
1-800-838-4268 info@sonopath.com

PATIENT

Herman Dunn

SPECIES

Czanine

BREED

Bull Terrier

SEX

MN

AGE

8 yr

WEIGHT

60 lbs.

INTERPRETED BY

R. McKenzie Daniel, DVM, DABVP (Canine and Feline)

IMAGING PERFORMED BY

A. Rodriguez

HOSPITAL NAME

Foxfield VS

REFERRING VET

A. Rodriguez

INVOICE

15665

DATE

12/20/22

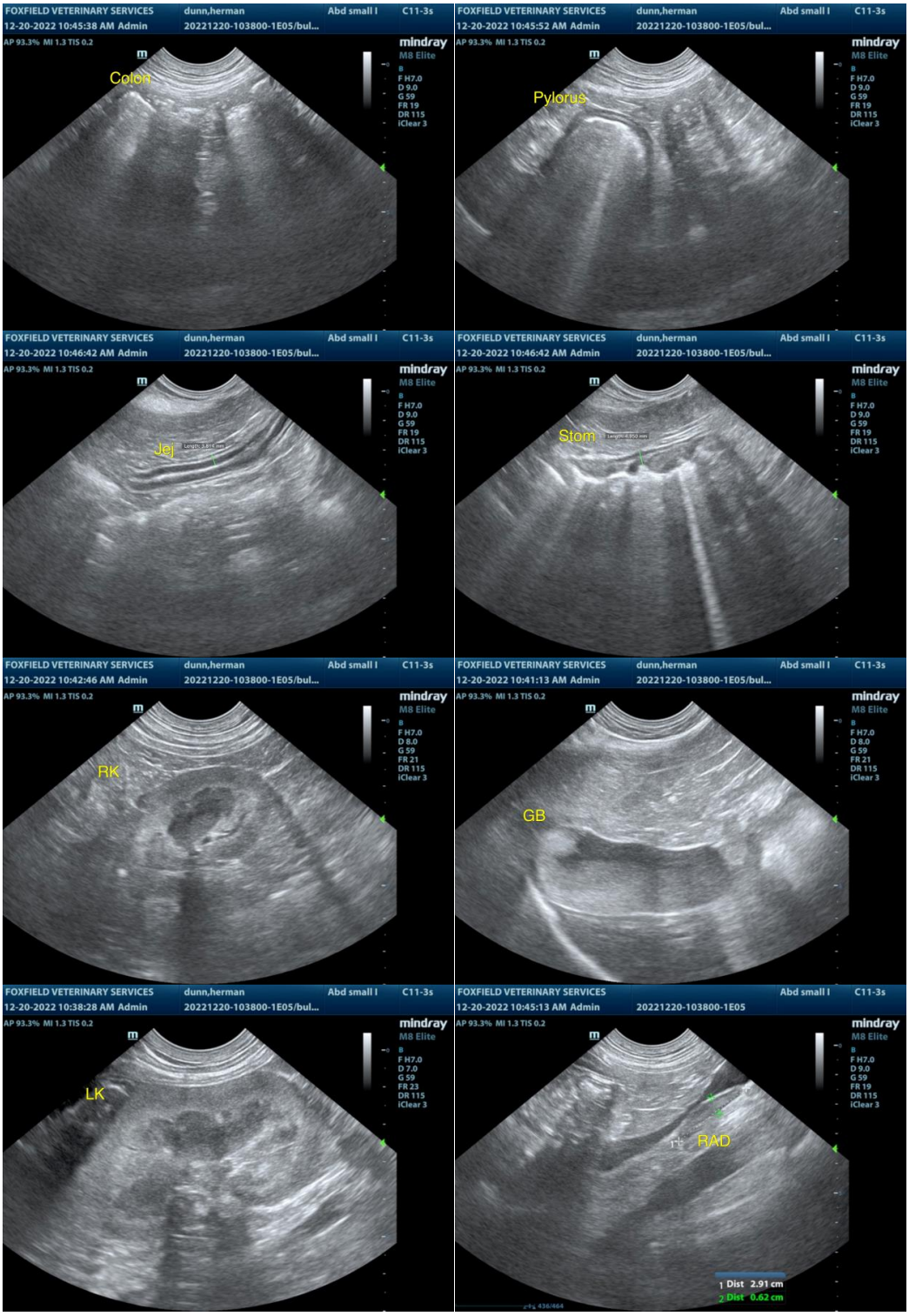

The information and recommendations provided are based on the images presented by the referring veterinarian/sonographer. No evaluation can be communicated regarding pathology that was not visible in the image/video clips provided.

SonoPath
Clinical Sonography & Telecytology

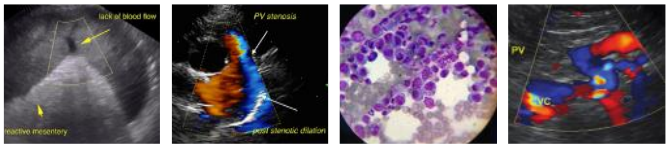

EDUCATIONAL TELECONSULTATION SERVICES™

SonoPath.com™
1-800-838-4268 info@sonopath.com

PATIENT

Herman Dunn

SPECIES

Czanine

BREED

Bull Terrier

SEX

MN

AGE

8 yr

WEIGHT

60 lbs.

INTERPRETED BY

R. McKenzie Daniel, DVM, DABVP (Canine and Feline)

IMAGING PERFORMED BY

A. Rodriguez

HOSPITAL NAME

Foxfield VS

REFERRING VET

A. Rodriguez

INVOICE

15665

DATE

12/20/22

Thank you for this referral. If the clinical or image interpretation does not parallel your findings or if I can be of any further assistance please contact me.

R. McKenzie Daniel, DVM, DABVP (Canine / Feline Practice)
info@SonoPath.com