



**PATIENT**

Asha Wood

**SPECIES**

Canine

**BREED**

Siberian Husky

**SEX**

FS

**AGE**

12 yr

**WEIGHT**

22.3 kg

**INTERPRETED BY**

R. McKenzie Daniel,  
DVM, DABVP  
(Canine and Feline)

**IMAGING PERFORMED BY**

JSS

**HOSPITAL NAME**

King Hopkins Pet  
Hospital

**REFERRING VET**

Dr. Latoya Brown

**INVOICE**

15673

**DATE**

12/20/22

**PRESENTING CLINICAL SIGNS**

Asha is a 12 yr old spayed Siberian Husky dog that presented with the complaint of frequent bouts of urination, PD and progressive weight loss. O says P has a hx of thyroid issues and diabetes for 6 yrs (gets 15 U insulin twice daily). She also has hx of recurrent UTIs. O says P has been having frequent urination and straining for 3 days. Drinking excessively. No v/d, Activity level unaffected, e/d-normal.

Abnormal PE/Chem/CBC/UA Results: Elevated WBC, hyperglycemia, increased ALKP. Please view attached blood work & urine results.

CBC- HCT 0.36, WBC 28.2 with Neutrophilia, Lymphocytosis, and Monocytosis, Platelets 554

Chemistry Panel - Glucose 34.9, normal renal parameters, ALP 1683

Urinalysis - Specific gravity 1.036, Proteinuria and Glucose urea

**ULTRASONOGRAPHIC EXAMINATION OF THE ABDOMEN**

**Urinary System**

The urinary bladder presented uniformly thickened urinary bladder wall isoechoic to the adjacent normal urinary bladder wall. The luminal margin of the thickened urinary bladder wall was mildly asymmetrical in contour. The dorsal apical urinary bladder wall thickness measured up to 1.0 cm width. Mineralization or echogenic foci within the thickened areas of the urinary bladder wall were not present. The urinary bladder, trigone, cystourethral junction, and visible pelvic urethra exhibited normal tone to a depth of 1.0 cm. Anechoic urine was present in the lumen with no uroliths, sediment, or calculi. The ureteral papillae were normal. The ureters were not visible which is normal.

A fluid-filled structure containing anechoic fluid with mild echogenic component, suggestive of fluid cellularity, was present dorsal and separate to the urinary bladder and visible proximal urethra, as well as ventral to the normal-appearing distal descending colon and colorectum, measuring approximately 5.1 cm x 2.2 cm.

Several, mildly prominent, medial iliac lymph nodes were present. The lymph nodes were essentially isoechoic to adjacent omentum without evidence of peripheral inflammation and maintaining a normal width: length ratio (<0.5). An example lymph node measured 1.0 cm in diameter, not consistent with inflammatory or neoplastic criteria.

Normal size and margination were present in the kidneys. A normal 1:3 cortex / medulla ratio was maintained. The medulla and cortices were uniform in texture with some increased echogenicity and mild loss of corticomedullary symmetry and definition expected for the age of the patient. No evidence of pelvic dilatation, pyelectasia, or pyelonephritis was present. The left kidney measured 6.7 cm in length. The right kidney measured 6.9 cm in length. Minor areas of nonobstructive medullary mineral were noted.

**Adrenal Glands**

The left adrenal gland was uniform in size and contour with a uniformly hypoechoic parenchyma. The left adrenal gland measured 0.64 cm width at the caudal pole and 0.5 cm width at the cranial pole. The



**PATIENT**

Asha Wood

right adrenal gland was uniform in size and contour with a uniformly hypoechoic parenchyma. The right adrenal gland measured 0.69 cm width at the caudal pole and 0.66 cm width at the cranial pole.

**SPECIES**

Canine

**Spleen**

The spleen exhibited primarily finely textured parenchyma which was hyperechoic to the liver and renal cortical parenchyma. Mild generalized parenchyma heterogeneity was present without evidence of nodular changes. The capsule was smooth and regular without apparent expansion. The splenic vasculature at the hilus was normal in volume with no evidence of congestion or thrombosis. The parenchymal heterogeneity is likely consistent with benign changes such as extramedullary hematopoiesis or age-related remodeling with minor potential for inflammatory or neoplastic disease.

**BREED**

Siberian Husky

**Liver/ Gallbladder**

**SEX**

FS

The liver presented enlarged in size. The parenchyma of the liver was subjectively normal in echogenicity compared to the spleen and renal cortices. The liver parenchyma was uniform with a mildly coarse echotexture. The capsule of the liver was symmetrically rounded to mildly swollen in margination. The hepatic and portal vasculature were normal in appearance without signs of congestion. The gallbladder was normal in size and non-distended containing primarily anechoic content with moderate luminal mineral, consistent with nonobstructive choleliths. No evidence of gallbladder or peripheral gallbladder inflammation was noted. The cystic and common bile ducts were normal.

**AGE**

12 yr

**WEIGHT**

22.3 kg

**INTERPRETED BY**

R. McKenzie Daniel,  
DVM, DABVP  
(Canine and Feline)

**Gastrointestinal**

The stomach presented intact wall layering with a normal wall layer ratio. The lumen of the stomach contained moderate, hyperechoic, progressively shadowing ingesta, likely consistent with post prandial presentation.

**IMAGING PERFORMED BY**

JSS

The small intestine presented intact wall layering with 1:3 muscularis/mucosa ratio. Segmental mild nonshadowing hyperechoic ingesta/ chyme was present with no evidence of mechanical obstructive pattern.

**HOSPITAL NAME**

King Hopkins Pet  
Hospital

Normal visible colon wall layers were present with apparent formed feces in lumen.

**REFERRING VET**

Dr. Latoya Brown

**Pancreas**

The parenchyma of the left limb, body, and right limb of the pancreas presented isoechoic to the adjacent omental fat. A normal curvilinear capsule contour of the pancreas was present. The visible pancreatic duct was normal. No signs of active inflammation or neoplastic disease were evident.

**INVOICE**

15673

**Free Abdomen**

No omental masses, lymphadenopathy, or evidence of peritoneal free fluid were noted.

**DATE**

12/20/22

**ULTRASONOGRAPHIC FINDINGS**

- Fluid-filled structure dorsal to the urinary bladder / proximal urethra and ventral to normal-appearing distal descending colon and colorectum - consistent with stump pyometra
- Cystitis urinary bladder pattern



**PATIENT**

Asha Wood

**SPECIES**

Canine

**BREED**

Siberian Husky

**SEX**

FS

**AGE**

12 yr

**WEIGHT**

22.3 kg

- Mild chronic renal changes with minor nonobstructive medullary mineral - no evidence of pyelonephritis
- Benign hepatopathy - sonographically suggestive of metabolic, reactive, or vacuolar hepatopathy with potential for nonobstructive cholestasis, inflammatory parenchymal disease i.e. cholangiohepatitis is possible
- Moderate nonobstructive gallbladder choleliths

**INTERPRETATION OF THE FINDINGS & FURTHER RECOMMENDATIONS**

Urine C/S on a sterile urine sample, given the presence of glucose urea, is recommended. Laparotomy with gross inspection in the area of the uterine stump with resection of stump pyometra to the level of the cervix, as well as recommended urinary bladder mural biopsies for histopathology, as well as tissue C/S are warranted. Gross inspection in the area of the left and right ovaries at the time of surgery is recommended, given the presence of stump pyometra.

Hepatosupportive medications including Denamarin and Ursodiol may prove beneficial with potential sonographic monitoring of the gallbladder if evidence of progressive cholestasis.

This is a suggestive checkoff list when faced with an unregulated diabetic patient:

- UTI
- Dietary indiscretion/intolerance
- Pancreatitis
- Hyperthyroidism/hypothyroidism
- Exogenous steroids (including topical eye meds)
- Cushing's
- Acromegaly
- Owner compliance
- Insulin quality issues
- Antibodies to insulin
- Underlying Neoplasia
- Diffuse liver disease

**INTERPRETED BY**

R. McKenzie Daniel,  
DVM, DABVP  
(Canine and Feline)

**IMAGING PERFORMED BY**

JSS

**HOSPITAL NAME**

King Hopkins Pet Hospital

**REFERRING VET**

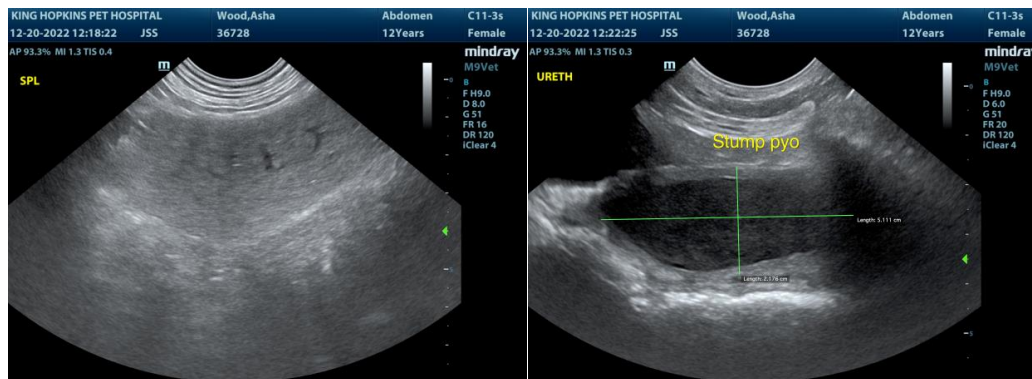
Dr. Latoya Brown

**INVOICE**

15673

**DATE**

12/20/22





**PATIENT**

Asha Wood

**SPECIES**

Canine

**BREED**

Siberian Husky

**SEX**

FS

**AGE**

12 yr

**WEIGHT**

22.3 kg

**INTERPRETED BY**

R. McKenzie Daniel,  
DVM, DABVP  
(Canine and Feline)

**IMAGING PERFORMED BY**

JSS

**HOSPITAL NAME**

King Hopkins Pet  
Hospital

**REFERRING VET**

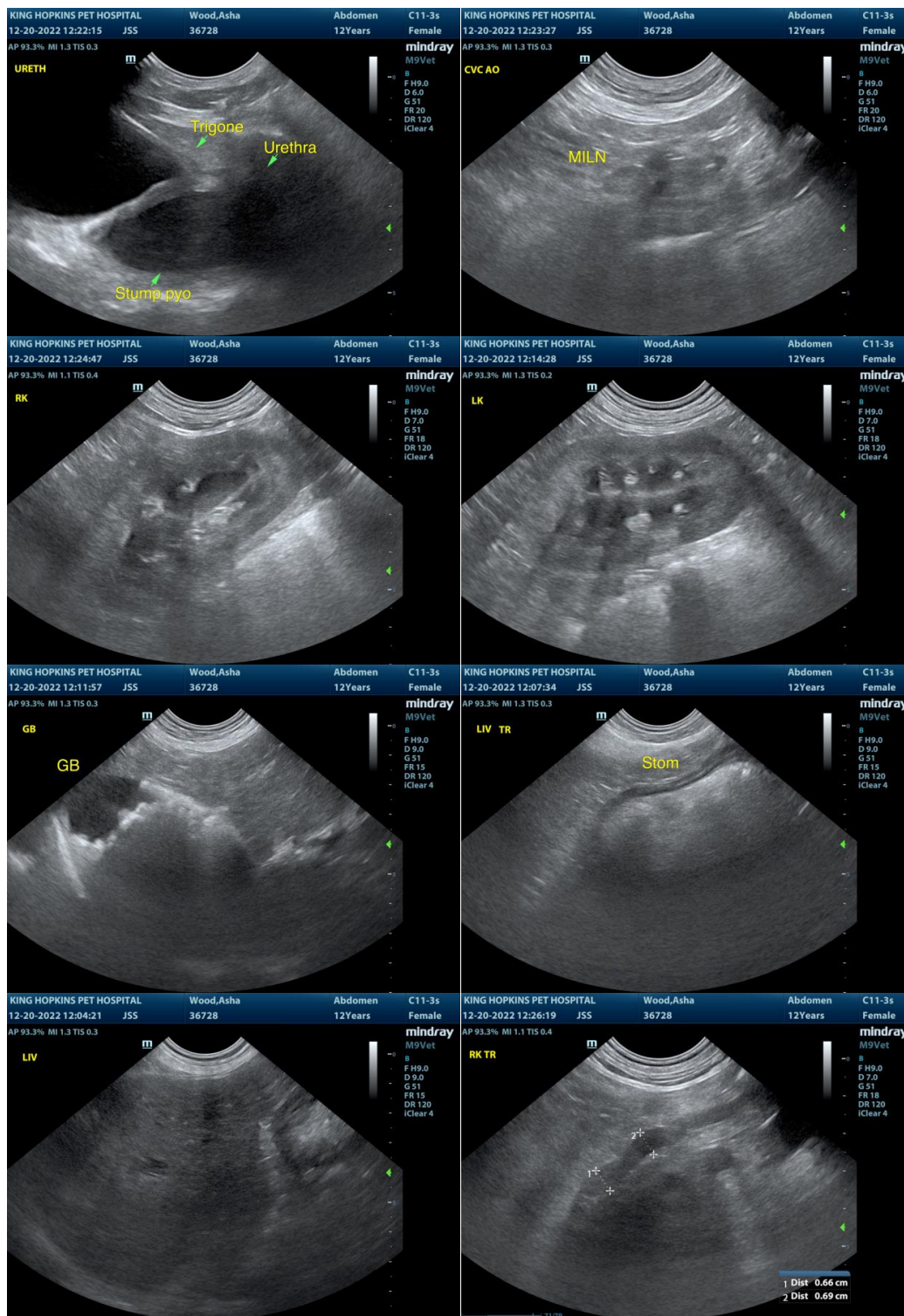
Dr. Latoya Brown

**INVOICE**

15673

**DATE**

12/20/22





## PATIENT

Asha Wood

## SPECIES

Canine

## BREED

Siberian Husky

## SEX

FS

## AGE

12 yr

## WEIGHT

22.3 kg

## INTERPRETED BY

R. McKenzie Daniel,  
DVM, DABVP  
(Canine and Feline)

## IMAGING PERFORMED BY

JSS

## HOSPITAL NAME

King Hopkins Pet  
Hospital

## REFERRING VET

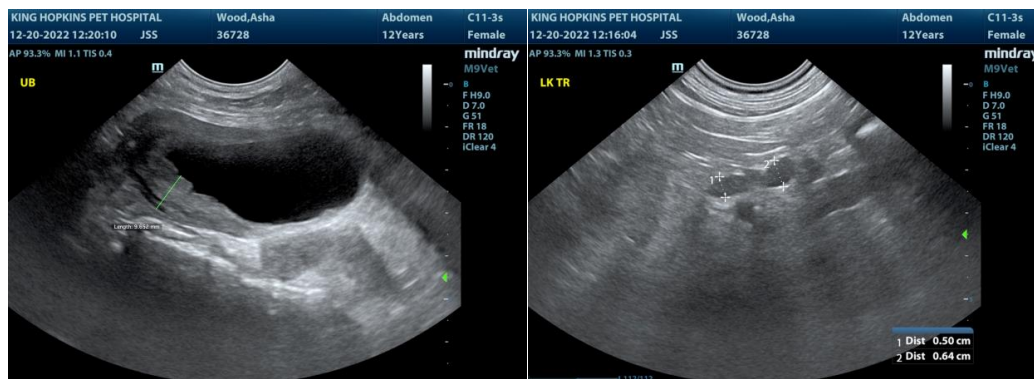
Dr. Latoya Brown

## INVOICE

15673

## DATE

12/20/22



The information and recommendations provided are based on the images presented by the referring veterinarian/sonographer. No evaluation can be communicated regarding pathology that was not visible in the image/video clips provided.

Thank you for this referral. If the clinical or image interpretation does not parallel your findings or if I can be of any further assistance please contact me.

**R. McKenzie Daniel, DVM, DABVP (Canine / Feline Practice)**  
info@SonoPath.com