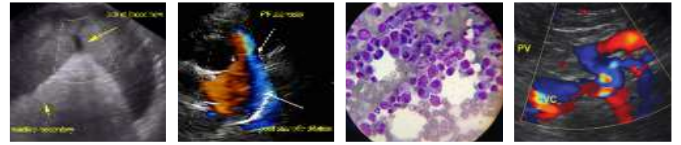




PATIENT	PRESENTING CLINICAL SIGNS
Sheldon Mackalonis	Inappetence; jaundice; bloated abdomen; lethargic; abdominal mass palpated. Abnormal PE/Chem/CBC/UA Results: BW has increased liver values
SPECIES	
Feline	CBC- WBC 12.9 w/ neutrophilia and lymphopenia, HCT 24.7
BREED	Chemistry panel- ALT >1000, ALP 215, GGT 15, TBILI 6.4, BUN 24.4, Creatinine 0.7
DSH	
SEX	
MN	
AGE	
9	ULTRASONOGRAPHIC EXAMINATION OF THE ABDOMEN
WEIGHT	Urinary System
11	The urinary bladder, trigone, cystourethral junction, and visible pelvic urethra to a depth of 2.0 cm exhibited normal thickness and tone. Minor particulate to hyperechoic sediment, likely consistent with minor cellular or crystalline debris, was present. The ureteral papillae were normal. The ureters were not visible which is normal. No evidence of inflammatory or neoplastic changes was noted.
INTERPRETED BY	The area of the aortic trifurcation was free of pathology.
R. McKenzie Daniel, DVM, DABVP (Canine and Feline)	Normal renal size with asymmetrical margination were present in both kidneys. The renal cortex presented uniformly increased in echogenicity with uniform echotexture. The renal cortex appeared to be hypertrophied resulting in an altered cortex: medulla ratio. Mild loss of corticomedullary distinction was also present. The renal medullary volume was subjectively reduced. Pinpoint areas of medullary to pelvic mineral were present in the left kidney. The left kidney measured 4.5 cm in length. The right kidney measured 4.2 cm in length.
IMAGING PERFORMED BY	Adrenal Glands
Tasha	The left and right adrenal glands were not definitively visualized.
HOSPITAL NAME	Spleen
Dillsburg VC	The spleen exhibited a finely textured and homogenous parenchyma which was hyperechoic to the liver and renal cortical parenchyma. The capsule was smooth and regular without apparent expansion. The splenic vasculature at the hilus was normal in volume with no evidence of congestion or thrombosis. Acute to chronic inflammatory, neoplastic, or benign parenchyma changes were not noted. The spleen measured 0.8 cm width.
REFERRING VET	Liver/ Gallbladder
Dr. Jacobs	The liver exhibited generalized enlargement with swollen to mild asymmetrical capsule margination. Generalized nonuniform increased hepatic parenchyma echogenicity with intermittent intraparenchymal nodules to solitary nonhomogeneous nodular mass was noted. The nodular mass measured 3.5 cm in diameter in the deep mid liver. The gallbladder was indistinctly visualized, potentially owing to subnormal size. No evidence of gallbladder overdistention or post hepatic obstruction was noted. The common bile duct was not definitively visualized.
INVOICE	
12858	
DATE	Gastrointestinal
12/20/21	The stomach presented intact wall layering with a normal wall layer ratio. Mild retained anechoic fluid was present in the stomach.



PATIENT	The visualized small intestine was sonographically unremarkable exhibiting intact wall layering and 1:3 muscularis / mucosa ratio. The jejunum wall width measured 0.20 cm. The ileocolic wall width measured 0.31 cm.
Sheldon Mackalonis	
SPECIES	Normal visible colon wall layers were present with apparent formed feces in lumen.
Feline	Pancreas
BREED	The parenchyma of the left limb, body, and right limb of the pancreas presented isoechoic to the adjacent omental fat. A normal curvilinear capsule contour of the pancreas was present. The visible pancreatic duct was normal. No signs of active inflammation or neoplastic disease were evident.
DSH	
SEX	Free Abdomen
MN	Moderate peritoneal free fluid and generalized mildly nonuniform reactive mesentery were present. No overt evidence of Intraabdominal lymphadenopathy was noted.
AGE	ULTRASONOGRAPHIC FINDINGS
9	Primary Findings
WEIGHT	<ul style="list-style-type: none"> • Hepatomegaly exhibiting intermittent intraparenchymal nodules to nodular mass • Overtly normal gallbladder and common bile duct - no signs of post hepatic obstruction • Moderate peritoneal free fluid and generalized mild nonuniform reactive mesentery
11	
INTERPRETED BY	Secondary Findings
R. McKenzie Daniel, DVM, DABVP (Canine and Feline)	<ul style="list-style-type: none"> • Bilateral interstitial nephrosis renal pattern • Mild hypomotile stomach
IMAGING PERFORMED BY	INTERPRETATION OF THE FINDINGS & FURTHER RECOMMENDATIONS
Tasha	Primary considerations for the liver may include moderate to severe cholangiohepatitis with areas of nodular to regenerative hyperplasia, hematopoiesis, intraparenchymal granulomas, or hepatic neoplasia. Hepatic neoplasia is favored, given the presence of the intraparenchymal nodules and nodular mass.
HOSPITAL NAME	
Dillsburg VC	
REFERRING VET	The effusion may be secondary to hepatic parenchymal pathology or portal hypertension, given normal albumin levels.
Dr. Jacobs	
INVOICE	Further assessment may include, assuming normal clotting status, hepatic parenchymal and nodular mass FNA, as well as effusion analysis cytology +/- C/S if clinically indicated. Three view chest radiographs are recommended to rule out occult thoracic pathology and assess cardiopulmonary status. Empirically, aggressive therapy for cholangiohepatitis with as-needed gastrointestinal support is recommended. A guarded prognosis is warranted.
12858	
DATE	
12/20/21	



PATIENT

Sheldon Mackalonis

SPECIES

Feline

BREED

DSH

SEX

MN

AGE

9

WEIGHT

11

INTERPRETED BY

R. McKenzie Daniel,
DVM, DABVP
(Canine and Feline)

IMAGING PERFORMED BY

Tasha

HOSPITAL NAME

Dillsburg VC

REFERRING VET

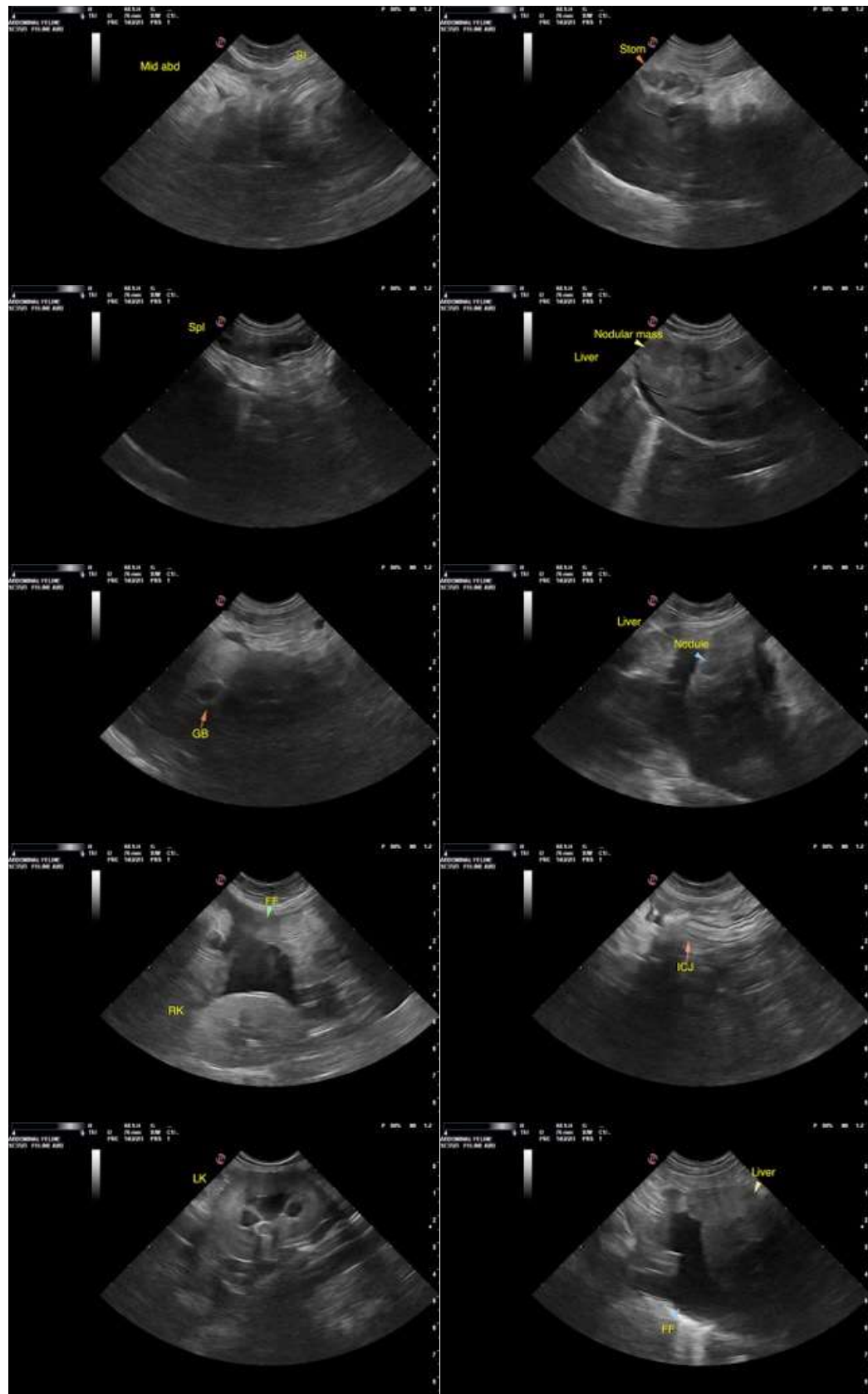
Dr. Jacobs

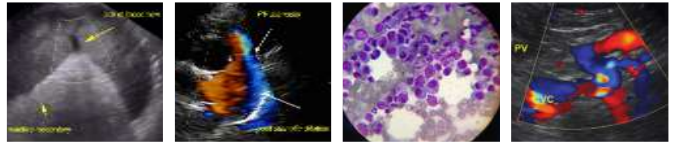
INVOICE

12858

DATE

12/20/21





PATIENT

Sheldon Mackalonis

SPECIES

Feline

BREED

DSH

SEX

MN

AGE

9

WEIGHT

11

INTERPRETED BY

R. McKenzie Daniel,
DVM, DABVP
(Canine and Feline)

**IMAGING
PERFORMED BY**

Tasha

HOSPITAL NAME

Dillsburg VC

REFERRING VET

Dr. Jacobs

INVOICE

12858

DATE

12/20/21

The information and recommendations provided are based on the images presented by the referring veterinarian. No evaluation can be communicated regarding pathology that was not visible in the image/video clips provided.

Thank you for this referral. If the clinical or image interpretation does not parallel your findings or if I can be of any further assistance please contact me.

R. McKenzie Daniel, DVM, DABVP (Canine / Feline Practice)
info@SonoPath.com