



PATIENT

Jazz Jenson Dineen

SPECIES

Canine

BREED

Poodle Mix

SEX

Neutered Male

AGE

11 Years

WEIGHT

6.4 pounds

INTERPRETED BY

R. McKenzie Daniel,
DVM, DABVP

IMAGING PERFORMED BY

Jenn

HOSPITAL NAME

Rockaway Animal
Hospital

REFERRING VET

Dr. Maniar

INVOICE

12533

DATE

12/02/25

PRESENTING CLINICAL SIGNS

Vomiting coughing lethargy

Abnormal PE/Chem/CBC/UA Results: ALT 127 ALP 21 Lipase 368

ULTRASONOGRAPHIC EXAMINATION OF THE HEART & ABDOMEN

CANINE CARDIAC PARAMETERS	MR VMAX (m/s)	TR VMAX (m/s)	LA/AO (M-Mode)	LA/AO (Heart Base; Swe)	FS (%)	EF (%)	EPSS (cm)
NORMAL PARAMETER	4.5-5.5	<2.7	1.3	Up to 1.6	28-40	40-100	<0.6
PATIENT	--	--	NM	1.2	35	68	0.2
CANINE CARDIAC PARAMETERS	HR (BPM)	AV VMAX (m/s)	PV MAX (m/s)	BODY WEIGHT (kg)	LAD LA MAX 4 Chamber	LVIDd Avg; 2D and m-mode short axis (cm)	LVIDs Avg; 2D and m-mode short axis (cm)
NORMAL PARAMETER	50-100	0.7-1.7	0.7-1.6				
PATIENT	119	1.0	0.6	--	1.7	1.6	--

Cardiac Presentation

The echocardiogram in this patient demonstrated normal **left atrial** size based on 2 separate methods of LA evaluation. The cranial and caudal **mitral** valve leaflets presented normal linear structure, extension in systole, and union in diastole with normal kinesis. The **left ventricle** presented thicknesses with linear contour and was not dilated nor restricted. The **myocardium** presented normal echogenicity without subjective evidence of significant fibrotic or ischemic disease. **Contractility** of the ventricular walls was adequate and in normal range for this patient evidenced by the fractional shortening measurement and subjective evaluation of the different regions of the myocardium. The **left ventricular outflow** tract demonstrated normal laminar flow and subjective structural integrity. The **right atrium** and auricle revealed normal size, structure and content. No evidence of masses was noted. **Tricuspid** valvular assessment demonstrated adequate linear morphology and kinesis. The **right ventricle** was of normal size (1/3 diameter of LV), chordae structure, myocardial echogenicity and thickness. **Pulmonary outflow** tract assessment revealed normal valve structure, laminar flow, and diameter (approx.1:1 pa/ao ratio). No visible **pericardial** or free pleura fluid was noted. The cranial **mediastinum and pericardial and extra-cardiac regions** were free of masses in the visible window.

Urinary System

The urinary bladder, trigone, cystourethral junction, and visible pelvic urethra to a depth of 2.0 cm exhibited normal thickness and tone. Anechoic urine was present in the lumen with no uroliths, urine mineral, calculi or sediment. The ureteral papillae were normal. The ureters were not visible which is normal. No evidence of inflammatory or neoplastic change were noted.



PATIENT

Jazz Jenson Dineen

SPECIES

Canine

BREED

Poodle Mix

SEX

Neutered Male

AGE

11 Years

WEIGHT

6.4 pounds

INTERPRETED BY

R. McKenzie Daniel,
DVM, DABVP

IMAGING PERFORMED BY

Jenn

HOSPITAL NAME

Rockaway Animal
Hospital

REFERRING VET

Dr. Maniar

INVOICE

12533

DATE

12/02/25

The area of the residual prostate appeared normal and free of pathology.

The left kidney was subnormal in size compared to the right kidney. A normal 1:3 cortex / medulla ratio was maintained. The medulla and cortices were uniform in texture with some increased echogenicity and moderate loss of corticomedullary symmetry and definition expected for the age of the patient. No evidence of pelvic dilation was present. The left kidney measured 2.7 cm in length.

Normal size and margination was present in the right kidney. A normal 1:3 cortex / medulla ratio was maintained. The medulla and cortices were uniform in texture with some increased echogenicity and mild indistinct corticomedullary border demarcation expected for the age of the patient. No evidence of pelvic dilation was present. The right kidney measured 3.5 cm in length.

Adrenal Glands

The left adrenal gland was uniform in size and contour with a uniformly hypoechoic parenchyma. The left adrenal gland measured 0.31 cm width at the caudal pole.

The right adrenal gland was not definitively visualized.

Spleen

The spleen exhibited a finely textured and homogenous parenchyma which was hyperechoic to the liver and renal cortical parenchyma. The capsule was smooth and regular without apparent expansion. The splenic vasculature at the hilus was normal in volume with no evidence of congestion or thrombosis. Acute to chronic inflammatory, neoplastic, or benign parenchyma changes were not noted.

Liver

The liver was subjectively normal in size, structure, and contour. The liver parenchyma was uniform and hypoechoic to the spleen with a mild coarse echotexture. The hepatic and portal vasculature were normal in appearance without signs of congestion. The gallbladder was non-distended in size with thin walls and primarily anechoic luminal content. The cystic and common bile ducts were normal.

Gastrointestinal

The stomach presented with intact borderline to mild thickened wall given the patient's body weight. Empty gastric lumen with mild lumen gas. Gastric body wall measured 0.37 cm wall width.

The small intestine presented intact wall layering with 1:3 muscularis/mucosa ratio. The lumen of the small intestine was empty with no signs of ileus, obstruction or foreign material. The duodenum wall measured 0.41 cm width. The jejunum wall measured 0.36 cm width.

Normal visible colon wall layers were present with apparent formed feces in lumen.

Pancreas

The parenchyma of the left limb, body and right limb of the pancreas presented isoechoic to the adjacent omental fat. A normal curvilinear capsule contour of the pancreas was present. The visible pancreatic duct was normal. No signs of active inflammation or neoplastic disease was evident.

Free Abdomen

No overt lymphadenopathy or peritoneal effusion was present.



PATIENT

Jazz Jenson Dineen

SPECIES

Canine

BREED

Poodle Mix

SEX

Neutered Male

AGE

11 Years

WEIGHT

6.4 pounds

INTERPRETED BY

R. McKenzie Daniel,
DVM, DABVP

IMAGING PERFORMED BY

Jenn

HOSPITAL NAME

Rockaway Animal
Hospital

REFERRING VET

Dr. Maniar

INVOICE

12533

DATE

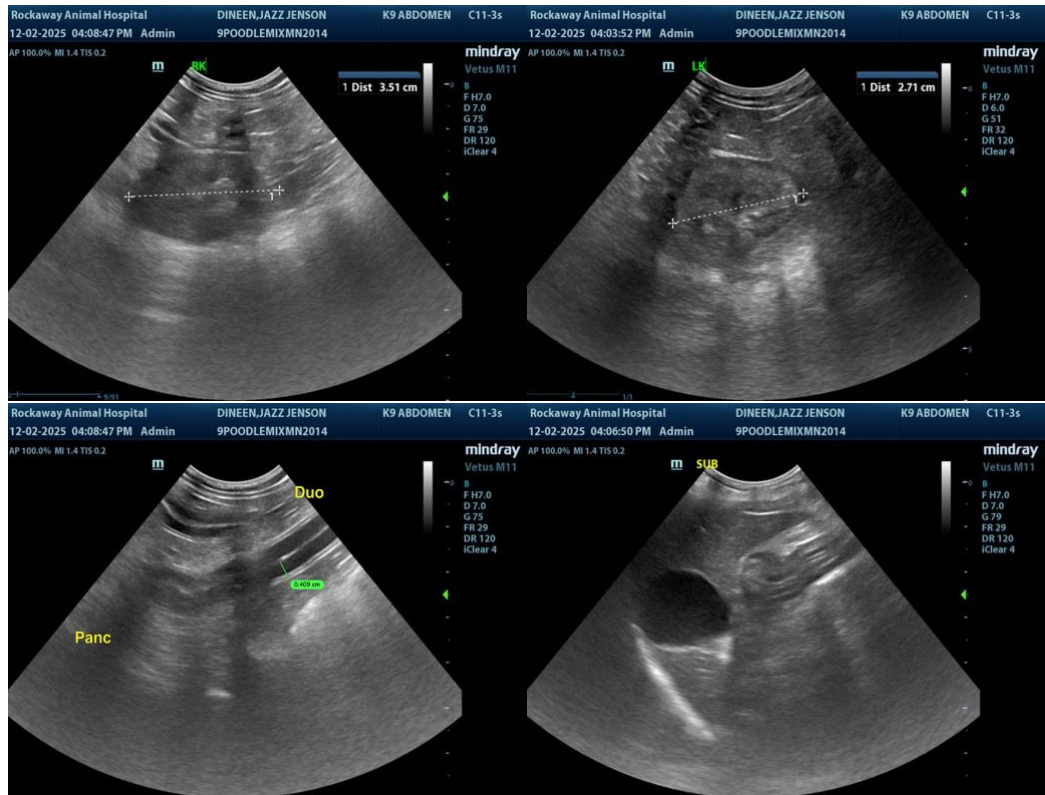
12/02/25

ULTRASONOGRAPHIC FINDINGS

- Normal echocardiogram.
- Sonographically unremarkable normal volume liver- consistent with low grade benign hepatopathy.
- Normal gallbladder.
- Normal area of pancreas.
- Mild gastritis.
- Mild to moderate chronic renal changes- more prominent in the left kidney with subnormal left kidney size compared to the right kidney.

INTERPRETATION OF THE FINDINGS & FURTHER RECOMMENDATIONS

No evidence of structural or functional cardiomyopathy as a cardiogenic contributing factor to the patient's coughing or clinical signs. Gastrointestinal support is indicated. A spec cPL could be considered to assess for mild pancreatitis which may present sonographically normal. Monitoring of hepatic parameters for evidence of progressive hepatopathy is recommended. Three view chest radiographs are suggested if not done.





PATIENT

Jazz Jenson Dineen

SPECIES

Canine

BREED

Poodle Mix

SEX

Neutered Male

AGE

11 Years

WEIGHT

6.4 pounds

INTERPRETED BY

R. McKenzie Daniel,
DVM, DABVP

IMAGING PERFORMED BY

Jenn

HOSPITAL NAME

Rockaway Animal
Hospital

REFERRING VET

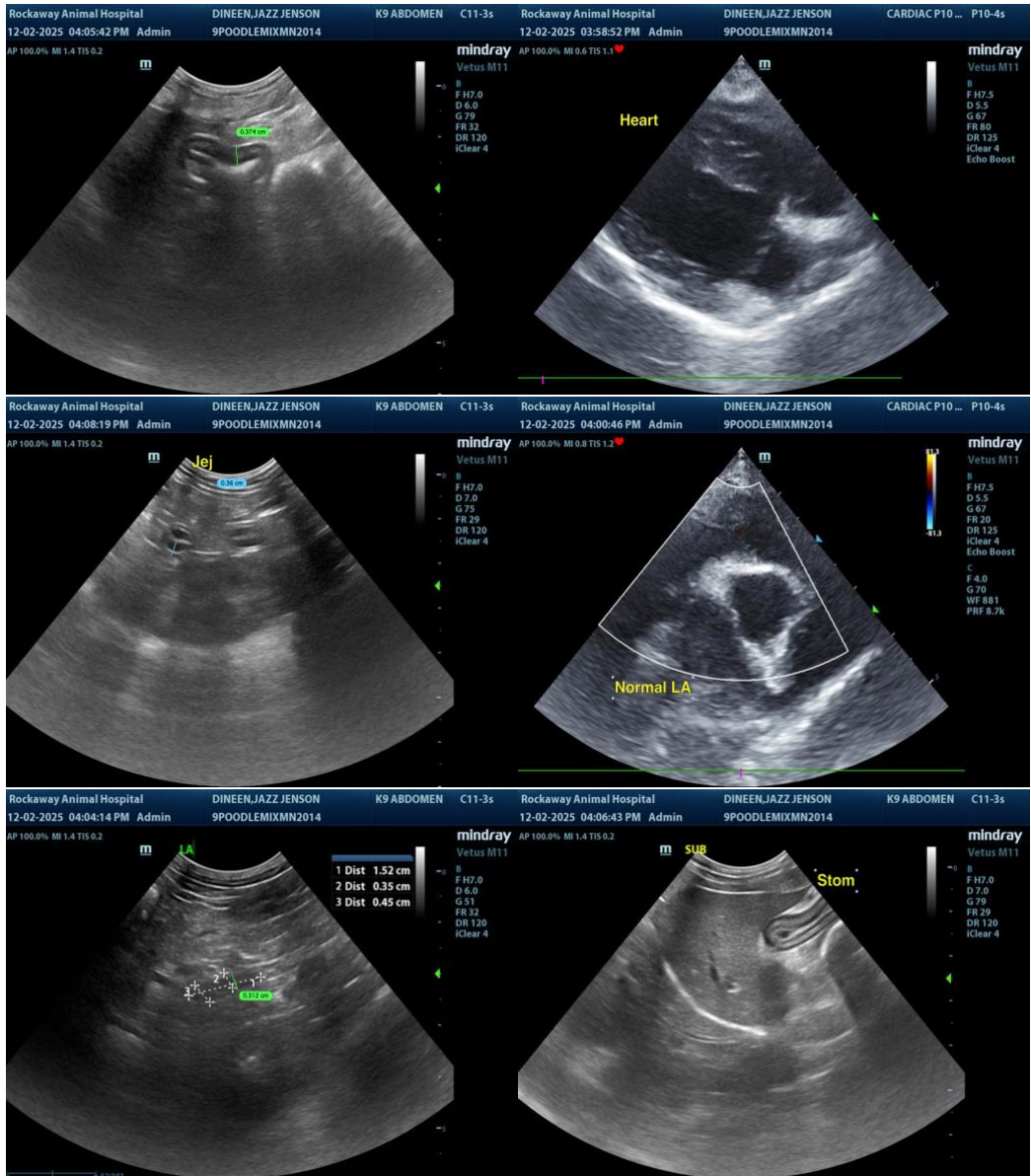
Dr. Maniar

INVOICE

12533

DATE

12/02/25



The information and recommendations provided are based on the images presented by the referring veterinarian/sonographer. No evaluation can be communicated regarding pathology that was not visible in the image/video clips provided.

Thank you for this referral. If the clinical or image interpretation does not parallel your findings or if I can be of any further assistance, please contact me.

R. McKenzie Daniel, DVM, DABVP (Canine / Feline Practice)

info@SonoPath.com