



**PATIENT PRESENTING CLINICAL SIGNS**

Winston Cruze

**SPECIES**

Canine

**BREED**

Golden Doodle

**SEX**

MN

**AGE**

1.5 yr

**WEIGHT**

25 kg

**INTERPRETED BY**

R. McKenzie Daniel,  
DVM, DABVP

**IMAGING**

**PERFORMED BY**

Crystal Hill

**HOSPITAL NAME**

Hillview Vet Clinic

**REFERRING VET**

Dr. Stevenson

**INVOICE**

15583

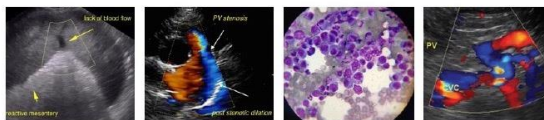
**DATE**

12/2/22

Winston was hit by a car this morning, chest on impact Objective - Oral Health NORMAL CONDITION - mm pink, crt < 2 sec, hydrated mm oral normal Objective - General Appearance ABNORMAL CONDITION -limping no external wounds Objective - Integumentary ABNORMAL CONDITION -mild road rash inside LF and RH Objective - Musculoskeletal ABNORMAL CONDITION -painful LF shoulder area resents extension LF limping no crepitus palpated in all limbs no neck or back pain Objective - Respiratory NORMAL CONDITION - RR on triage panting repeated at 28 normal effort no pain on palpation ribcage Objective - Digestive NORMAL CONDITION - normal palpation abdomen Objective - Genitourinary NORMAL CONDITION - normal externally Objective - Eyes NORMAL CONDITION - normal external fundus no hemorrhage seen normal blink, menace and PLR Objective - Ears NORMAL CONDITION - ears are normal internal and ext Objective - Neural Systems NORMAL CONDITION - normal mentation and behaviour normal cranial nerves limping gait no Horner's syndrome Objective - Lymph Nodes NORMAL CONDITION - superficial nodes are normal Page 25 of 29 Objective - Circulatory NORMAL CONDITION - HR 120 no murmur or arrhythmia pulses normal and synchronous Objective - Rectal NORMAL CONDITION - normal external Temperature 38.9°C By Ear Heart Rate 120 Respiratory Rate panting Pulse Quality normal CRT < 2 seconds Mucous Membrane pink Hydration euhydrate Systolic Blood Pressure 162 Systolic Blood Pressure 162 Diastolic Blood Pressure 135 Body Condition Score 5 - Ideal Pain Score 2 - Mild RECHECK AT REG DVM fine since the HBC on pain and antiinflammatories limping little still o says ok otherwise. this was recheck post emerge clinic long records from emerge clinic. they found no fractures. however large heartsiloutte and evidence of mild bilateral pneumothorax with pulmonary contusions present not deemed necessary at current time for thoracocentesis. home currently with gaba, and metacam BAR HR 96 - syncgh pulses RR - 24 - clear sounds temp 101.2F mm pink , moist CRT < 2sec sore R front noted - o says hit on this side nothing felt abd all else normal cough on tracheal pinch -mild road rash inside LF and RH

**ULTRASONOGRAPHIC EXAMINATION OF THE HEART**

CANINE	MR	TR	LA/AO	LA/AO	FS	EF	EPSS
<b>CARDIAC PARAMETERS</b>	<b>VMAX</b> (m/s)	<b>VMAX</b> (m/s)	(Boon method)	(Heart Base; Swe)	(%)	(%)	(cm)
<b>NORMAL PARAMETER</b>	4.5-5.5	<2.7	1.3	<1.6	28-40	40-100	<0.6
<b>PATIENT</b>				1.7	33.5	62.3	0.6
<b>CANINE</b>	<b>HR</b>	<b>AV</b>	<b>PV</b>	<b>BODY WEIGHT</b>	<b>LA</b>	<b>LVIDd</b>	<b>LVIDs</b>
<b>CARDIAC</b>	(BPM)	<b>VMAX</b>	<b>MAX</b>	(kg)	2D short axis Base view	Avg; 2D and m-mode short axis	Avg; 2D and m-mode shortaxis
<b>PARAMETERS</b>		(m/s)	(m/s)		(cm)	(cm)	(cm)
<b>NORMAL PARAMETER</b>	50-100	0.7-1.7	0.7-1.6	BELOW	BELOW	BELOW	BELOW
<b>PATIENT</b>	142	2.0	1.5		4.5	4.7	



**PATIENT**

**Cardiac Presentation**

Winston Cruze

Moderate left ventricular dilation with adequate systolic function was present. Borderline increased EPSS and increased LV sphericity were noted. Potential mild subjective decreased LV wall thickness. Mild to moderate LA enlargement was noted. The Mitral valve was overtly normal in appearance with normal kinesis. Mild centralized to eccentric MR was present on Doppler. The tricuspid valve was overtly normal. No overt TR was present. The right atrium and right ventricle were of subjective normal size. The aortic valve was normal with borderline increased measured LVOT velocity. No aortic insufficiency was noted. Normal pulmonic valve with normal measured RVOT velocity was present. No pulmonic insufficiency was noted. No pericardial or pleural effusion was noted. No evidence of cardiac tumors was present.

**SPECIES**

Canine

**BREED**

Golden Doodle

**SEX**

MN

**AGE**

1.5 yr

**ULTRASONOGRAPHIC FINDINGS**

- Mild to moderate LA / LV enlargement
- Adequate to normal LV function
- Mild MR

**INTERPRETATION OF THE FINDINGS & FURTHER RECOMMENDATIONS**

**WEIGHT**

25 kg

The cardiac presentation in this patient is nonspecific yet may potentially indicate emerging primary DCM-like criteria, although potential secondary cardiac changes to taurine deficiency, hypothyroidism, myocarditis, or less likely infiltrative disease such as lymphoma, are possible. Diet history should be obtained to assess for or exclude grain-free boutique or exotic diets. Thyroid status, as well as troponin level, may be considered. The overall cardiac function appears to be adequate with congestive criteria considered unlikely and in conjunction with submitted radiographs.

**INTERPRETED BY**

R. McKenzie Daniel,  
DVM, DABVP

No overt indication for cardiac medications, yet serial sonographic monitoring is highly recommended for further assessment. ECG could be considered if evidence of arrhythmia, although no overt arrhythmia was present in this study. Recheck echocardiogram is recommended in 4- 6 months, sooner if clinical signs arise or if evidence of arrhythmia. Initial exercise restriction, as well as baseline monitoring of resting respiration rate, would be appropriate.

**IMAGING PERFORMED BY**

Crystal Hill

**HOSPITAL NAME**

Hillview Vet Clinic

**REFERRING VET**

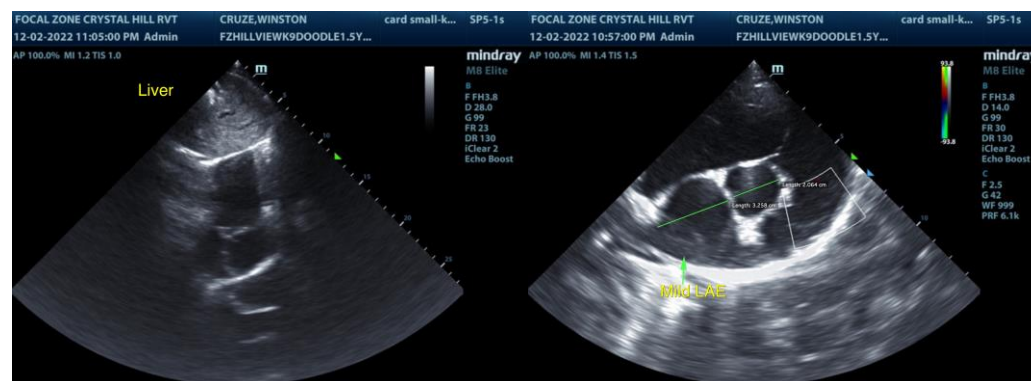
Dr. Stevenson

**INVOICE**

15583

**DATE**

12/2/22





**PATIENT**

Winston Cruze

**SPECIES**

Canine

**BREED**

Golden Doodle

**SEX**

MN

**AGE**

1.5 yr

**WEIGHT**

25 kg

**INTERPRETED BY**

R. McKenzie Daniel,  
DVM, DABVP

**IMAGING  
PERFORMED BY**

Crystal Hill

**HOSPITAL NAME**

Hillview Vet Clinic

**REFERRING VET**

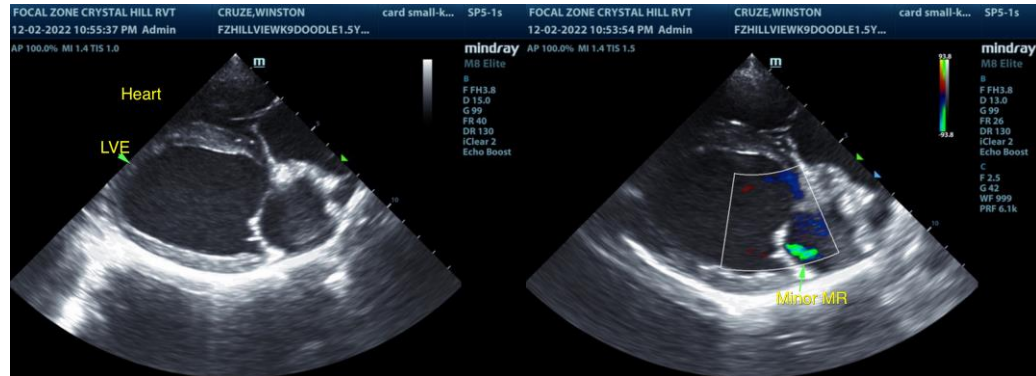
Dr. Stevenson

**INVOICE**

15583

**DATE**

12/2/22



The information and recommendations provided are based on the images presented by the referring veterinarian/sonographer. No evaluation can be communicated regarding pathology that was not visible in the image/video clips provided.

Thank you for this referral. If the clinical or image interpretation does not parallel your findings or if I can be of any further assistance please contact me.

**R. McKenzie Daniel, DVM, DABVP (Canine / Feline Practice)**  
info@SonoPath.com