



PATIENT

Sophie Townsend

SPECIES

Canine

BREED

Labrador Retriever

SEX

FS

AGE

3 years 9 months

WEIGHT

25.6 kg

INTERPRETED BY

R. McKenzie Daniel,
DVM, DABVP
(Canine and Feline)

IMAGING PERFORMED BY

Donna Markland,
DVM

HOSPITAL NAME

Island Mobile Paws
Veterinary Services

REFERRING VET

Island Animal
Hospital

INVOICE

15585

DATE

12/2/22

PRESENTING CLINICAL SIGNS

Presented for failure to gain weight. Sophie was adopted from the SPCA in 2019 after she recovered from a gunshot injury to the abdomen. As a result of that injury, Sophie had an intestinal resection and anastomosis surgery. Sophie is otherwise clinically normal and very active at home. PE is unremarkable, with an ideal BCS of 4-5/9. Workup has included CBC/Chem/UA, PLI, cTLI, B12/Folate, and a GI parasite panel. Almost all tests are well within the normal range (see below for single exception).

Abnormal PE/Chem/CBC/UA Results: 10/31/22: GI Parasite PCR panel: Eimeria detected, low parasite burden.

ULTRASONOGRAPHIC EXAMINATION OF THE ABDOMEN

Urinary System

The urinary bladder, trigone, and cystourethral junction exhibited normal thickness and tone. Anechoic urine was present in the lumen with no uroliths or sediment. The ureteral papillae were normal. The ureters were not visible which is normal. No evidence of inflammatory or neoplastic changes was noted.

The area of the aortic trifurcation was free of pathology.

Normal size and margination were present in the kidneys. A normal 1:3 cortex / medulla ratio and normal corticomedullary definition were maintained. The echogenicity of the cortex was similar to or slightly less than normal liver parenchyma while the medulla echogenicity was hypoechoic to the cortex with no evidence of pelvic dilation. The left kidney measured 6.8 cm in length. The right kidney measured 7.5 cm in length.

Adrenal Glands

The left adrenal gland was uniform in size and contour with a uniformly hypoechoic parenchyma. The left adrenal gland measured 2.5 cm length x 0.53 cm width at the caudal pole. The right adrenal gland was uniform in size and contour with a uniformly hypoechoic parenchyma. The right adrenal gland measured 2.8 cm length x 0.40 cm width at the caudal pole.

Spleen

The spleen exhibited a finely textured and homogenous parenchyma which was hyperechoic to the liver and renal cortical parenchyma. The capsule was smooth and regular without apparent expansion. The splenic vasculature at the hilus was normal in volume with no evidence of congestion or thrombosis. Acute to chronic inflammatory, neoplastic, or benign parenchyma changes were not noted.

Liver/ Gallbladder

The liver was subjectively normal in size, structure, and contour. The liver parenchyma was uniform and hypoechoic to the spleen with a mild coarse echotexture. The hepatic and portal vasculature were normal in appearance without signs of congestion. The gallbladder was non-distended in size with thin walls and primarily anechoic luminal content. The cystic and common bile ducts were normal.



PATIENT

Sophie Townsend

SPECIES

Canine

BREED

Labrador Retriever

SEX

FS

AGE

3 years 9 months

WEIGHT

25.6 kg

INTERPRETED BY

R. McKenzie Daniel,
DVM, DABVP
(Canine and Feline)

IMAGING PERFORMED BY

Donna Markland,
DVM

HOSPITAL NAME

Island Mobile Paws
Veterinary Services

REFERRING VET

Island Animal
Hospital

INVOICE

15585

DATE

12/2/22

Gastrointestinal

The stomach presented intact wall layering with a normal wall layer ratio. The lumen of the stomach was empty with no signs of ileus, obstruction, or foreign material.

The small intestine presented intact wall layering with 1:3 muscularis/mucosa ratio. The lumen of the small intestine was empty with no signs of ileus, obstruction, or foreign material.

Normal visible colon wall layers were present with apparent formed feces in lumen.

Pancreas

The parenchyma of the left limb, body, and right limb of the pancreas presented isoechoic to the adjacent omental fat. A normal curvilinear capsule contour of the pancreas was present. The visible pancreatic duct was normal. No signs of active inflammation or neoplastic disease were evident.

Free Abdomen

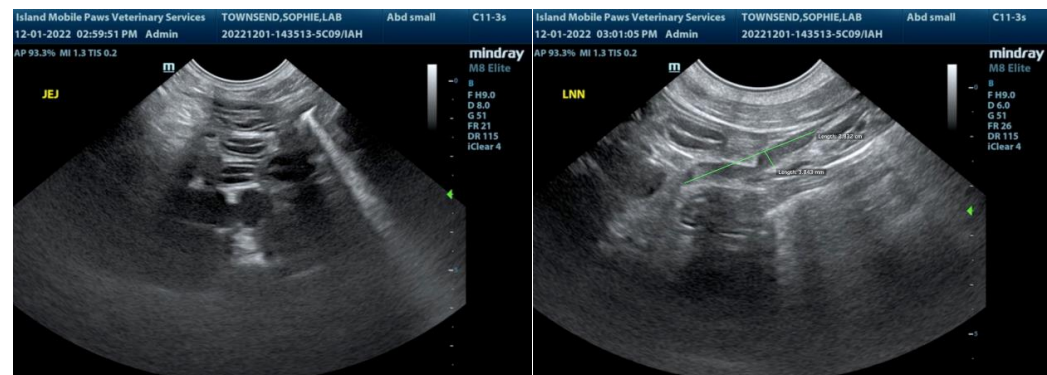
Focal to intermittent mildly prominent mesenteric lymph nodes were present. The lymph nodes were essentially isoechoic to adjacent omentum without evidence of peripheral inflammation and maintaining a normal width: length ratio (<0.5). An example lymph node measured 2.8 cm x 0.38 cm. The mesenteric lymph nodes are considered incidental and not consistent with inflammatory or neoplastic criteria. No evidence of peritoneal free fluid or omental masses was noted.

ULTRASONOGRAPHIC FINDINGS

- Sonographically normal abdomen

INTERPRETATION OF THE FINDINGS & FURTHER RECOMMENDATIONS

No evidence of abdominal visceral pathology was noted.





PATIENT

Sophie Townsend

SPECIES

Canine

BREED

Labrador Retriever

SEX

FS

AGE

3 years 9 months

WEIGHT

25.6 kg

INTERPRETED BY

R. McKenzie Daniel,
DVM, DABVP
(Canine and Feline)

IMAGING PERFORMED BY

Donna Markland,
DVM

HOSPITAL NAME

Island Mobile Paws
Veterinary Services

REFERRING VET

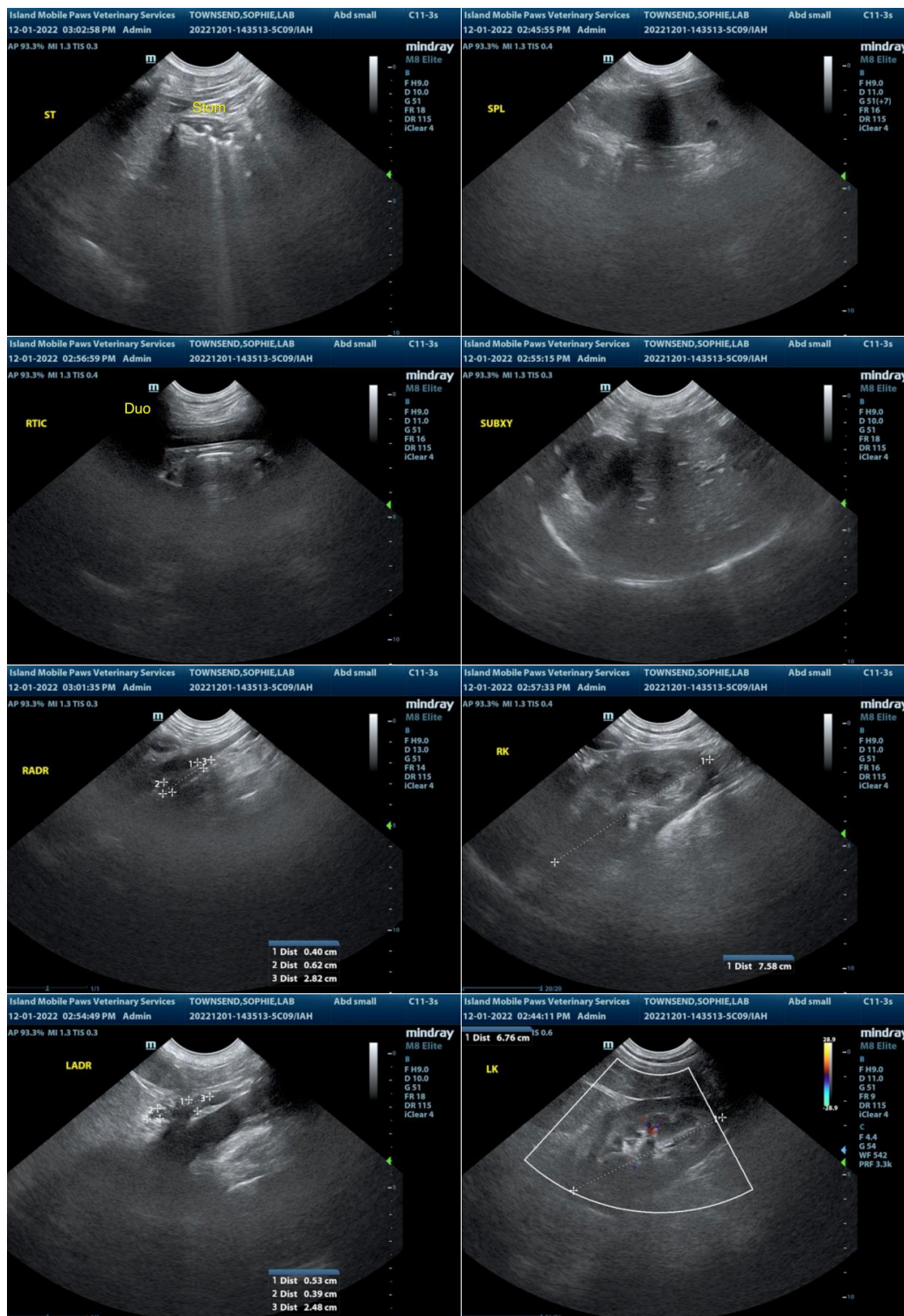
Island Animal
Hospital

INVOICE

15585

DATE

12/2/22



The information and recommendations provided are based on the images presented by the referring veterinarian/sonographer. No evaluation can be communicated regarding pathology that was not visible in the image/video clips provided.



PATIENT

Sophie Townsend

Thank you for this referral. If the clinical or image interpretation does not parallel your findings or if I can be of any further assistance please contact me.

SPECIES

Canine

R. McKenzie Daniel, DVM, DABVP (Canine / Feline Practice)
info@SonoPath.com

BREED

Labrador Retriever

SEX

FS

AGE

3 years 9 months

WEIGHT

25.6 kg

INTERPRETED BY

R. McKenzie Daniel,
DVM, DABVP
(Canine and Feline)

**IMAGING
PERFORMED BY**

Donna Markland,
DVM

HOSPITAL NAME

Island Mobile Paws
Veterinary Services

REFERRING VET

Island Animal
Hospital

INVOICE

15585

DATE

12/2/22