



PATIENT PRESENTING CLINICAL SIGNS

Norman Ervin 10.10 - swollen ventral neck, some improvement with medical management.
Medication: Amoxicillin, Metronidazole

SPECIES ULTRASONOGRAPHIC EXAMINATION OF THE NECK

Canine
Sonographic assessment of the ventral neck revealed regional ventral neck to peritracheal nonuniform hyperechoic tissue, measuring approximately 5.0 cm in diameter. Associated primarily mild yet hypoechoic regional lymphadenopathy was noted. Small to moderately sized pocket of subcutaneous primarily anechoic fluid, potentially encapsulated, measuring approximately 3.0-3.5 cm in diameter was present. No overt evidence of peripheral effusion was noted around the ventral neck, nonuniform, hyperechoic tissue, or adjacent to the trachea. The left or right thyroid lobe nodules were not distinctly visualized.

BREED SEX

Lab Mix MN

- AGE**
- Ventral neck to peritracheal cellulitis pattern with associated mild regional lymphadenopathy
 - Nonspecific subcutaneous potentially encapsulated fluid pocket

2018

WEIGHT INTERPRETATION OF THE FINDINGS & FURTHER RECOMMENDATIONS

70 Unspecified ventral neck to peritracheal inflammation / infection, neoplasia, necrosis, and penetrating foreign body, are all potentials. Culture and sensitivity of the tissue +/- biopsy are likely required for a definitive diagnosis. Given this presentation, cervical CT is likely ideal for further assessment.

INTERPRETED BY

R. McKenzie Daniel,
DVM, DABVP
(Canine and Feline)

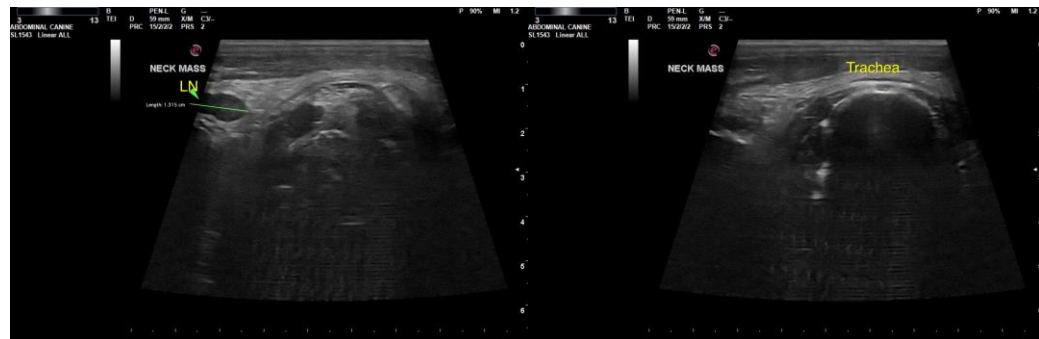
Empirically, as-needed antibiotic trial (ideally based on culture and sensitivity results), with continued monitoring would be a more conservative approach. Sedated thorough oropharyngeal exam may be considered if not done.

IMAGING

PERFORMED BY
Rebekah Jakum, CVT
ARDMS/RVT

HOSPITAL NAME

Mill Pond VC



REFERRING VET

Dr. Thayer

INVOICE

15586

DATE

12/2/22



PATIENT

Norman Ervin

The information and recommendations provided are based on the images presented by the referring veterinarian/sonographer. No evaluation can be communicated regarding pathology that was not visible in the image/video clips provided.

SPECIES

Canine

Thank you for this referral. If the clinical or image interpretation does not parallel your findings or if I can be of any further assistance, please contact me.

BREED

Lab Mix

R. McKenzie Daniel, DVM, DABVP (Canine/Feline Practice)
mac.daniel@sonopath.com

SEX

MN

AGE

2018

WEIGHT

70

INTERPRETED BY

R. McKenzie Daniel,
DVM, DABVP
(Canine and Feline)

**IMAGING
PERFORMED BY**

Rebekah Jakum, CVT
ARDMS/RVT

HOSPITAL NAME

Mill Pond VC

REFERRING VET

Dr. Thayer

INVOICE

15586

DATE

12/2/22