



PATIENT PRESENTING CLINICAL SIGNS

Camilla Straka Pre-anesthetic u/s, met check, staging. Recent MCT noted on FNA/Cyto. Grade II-III/VI murmur.
 Current meds: Gabapentin, Trazadone
 Abnormal PE/Chem/CBC/UA Results: nsf

SPECIES

Canine

ULTRASONOGRAPHIC EXAMINATION OF THE HEART & ABDOMEN

BREED

Pit Bull x

SEX

Spayed Female

AGE

12 Years

WEIGHT

54.6 Pounds

CANINE CARDIAC PARAMETERS	MR VMAX (m/s)	TR VMAX (m/s)	LA/AO (Boon method)	LA/AO (Heart Base; Swe)	FS (%)	EF (%)	EPSS (cm)
NORMAL PARAMETER	4.5-5.5	<2.7	1.3	<1.6	28-40	40-100	<0.6
PATIENT		1.7	1.3	1.3	48.8	83.8	0.35
CANINE CARDIAC PARAMETERS	HR (BPM)	AV VMAX (m/s)	PV MAX (m/s)	BODY WEIGHT (kg)	LA 2D short axis Base view (cm)	LVIDd Avg; 2D and m-mode short axis (cm)	LVIDs Avg; 2D and m-mode short axis (cm)
NORMAL PARAMETER	50-100	0.7-1.7	0.7-1.6				
PATIENT	161	1.6	1.6		3.5	3.87	

INTERPRETED BY

R. McKenzie Daniel, DVM, DABVP (Canine and Feline)

IMAGING PERFORMED BY

Shari Reffi, CVT

HOSPITAL NAME

Long Valley AH

REFERRING VET

Dr. Welch

INVOICE

33183

DATE

12/2/21

Cardiac Presentation

The echocardiogram in this patient demonstrated normal **left atrial** size based on 3 separate methods of LA evaluation. The cranial and caudal **mitral** valve leaflets presented normal linear structure, extension in systole, and union in diastole with normal kinesis. The **left ventricle** presented thicknesses with linear contour and was not dilated nor restricted. The **myocardium** presented normal echogenicity without subjective evidence of significant fibrotic or ischemic disease. **Contractility** of the ventricular walls was adequate and in normal range for this patient evidenced by the fractional shortening measurement and subjective evaluation of the different regions of the myocardium. The **left ventricular outflow** tract demonstrated normal laminar flow and subjective structural integrity. The **right atrium** and auricle revealed normal size, structure and content. No evidence of masses was noted. **Tricuspid** valvular assessment demonstrated adequate linear morphology and kinesis. Color doppler assessment revealed minor tricuspid valve insufficiency. The **right ventricle** was of normal size (1/3 diameter of LV), chordae structure, myocardial echogenicity and thickness. **Pulmonary outflow** tract assessment revealed normal valve structure, laminar flow, and diameter (approx. 1:1 pa/ao ratio). No visible **pericardial** or free pleura fluid was noted. The cranial **mediastinum** and **pericardial** and **extra-cardiac** regions were free of masses in the visible window.

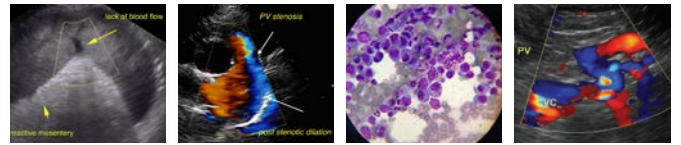
Urinary System

The urinary bladder, trigone, cystourethral junction, and visible pelvic urethra to a depth of – cm exhibited normal thickness and tone. Anechoic urine was present in the lumen with no uroliths or sediment. The ureteral papillae were normal. The ureters were not visible which is normal. No evidence of inflammatory or neoplastic changes were noted.

Normal size and margination were present in the kidneys. A normal 1:3 cortex / medulla ratio was maintained. The medulla and cortices were uniform in texture with some increased echogenicity and



PATIENT	mild loss of corticomedullary symmetry and definition expected for the age of the patient. No evidence of pelvic dilation was present. The left kidney measured 6.2 cm. The right kidney measured 6.4 cm.
Camilla Straka	
SPECIES	The area of the aortic trifurcation was free of pathology. No evidence of medial iliac or sublumbar lymphadenopathy.
Canine	Adrenal Glands
BREED	The adrenal glands were uniform in size and contour with a uniformly hypoechoic parenchyma. The left adrenal gland measured 2.2 cm length x 0.59 cm at the caudal pole. The right adrenal gland measured 2.3 cm length x 0.45 cm at the caudal pole.
Pit Bull x	Spleen
SEX	The spleen exhibited a finely textured and homogenous parenchyma which was hyperechoic to the liver and renal cortical parenchyma. The capsule was smooth and regular without apparent expansion. The splenic vasculature at the hilus was normal in volume with no evidence of congestion or thrombosis. Acute to chronic inflammatory, neoplastic, or benign parenchyma changes were not noted.
Spayed Female	
AGE	Liver
12 Years	The liver was subjectively normal in size, structure, and contour. The liver parenchyma was uniform and hypoechoic to the spleen with a mild coarse echotexture. The hepatic and portal vasculature were normal in appearance without signs of congestion. The gallbladder was non-distended in size with thin walls and primarily anechoic luminal content. The cystic and common bile ducts were normal.
WEIGHT	Gastrointestinal
54.6 Pounds	The stomach presented intact wall layering with a normal wall layer ratio. The lumen of the stomach contained mild to moderate echogenic ingesta exhibiting subtle progressive distal acoustic shadowing.
INTERPRETED BY	The small intestine presented intact wall layering with 1:3 muscularis/mucosa ratio. The lumen of the small intestine was empty with no signs of ileus, obstruction or foreign material.
R. McKenzie Daniel, DVM, DABVP (Canine and Feline)	Normal visible colon wall layers were present with apparent formed feces in lumen.
IMAGING PERFORMED BY	Pancreas
Shari Reffi, CVT	The parenchyma of the left limb, body and right limb of the pancreas presented isoechoic to the adjacent omental fat. A normal curvilinear capsule contour of the pancreas was present. The visible pancreatic duct was normal. No signs of active inflammation or neoplastic disease was evident.
HOSPITAL NAME	Free Abdomen
Long Valley AH	No omental masses, lymphadenopathy or peritoneal effusion.
REFERRING VET	ULTRASONOGRAPHIC FINDINGS
Dr. Welch	<ul style="list-style-type: none"> • Overtly normal cardiac structure and function • Minor TR • Sonographically unremarkable abdomen
INVOICE	INTERPRETATION OF THE FINDINGS & FURTHER RECOMMENDATIONS
33183	No evidence of structural or functional cardiomyopathy. An obvious cause of the murmur was not definitively evident in this study. Minor TR with potential for minor MR was present, yet not likely audible. In the absence of dehydration or anemia, a potential physiologic flow murmur or small flow abnormality not seen here are possible. Regardless, the lack of left or right heart chamber enlargement
DATE	
12/2/21	



PATIENT

Camilla Straka

SPECIES

Canine

BREED

Pit Bull x

SEX

Spayed Female

AGE

12 Years

WEIGHT

54.6 Pounds

INTERPRETED BY

R. McKenzie Daniel,
DVM, DABVP
(Canine and Feline)

IMAGING PERFORMED BY

Shari Reffi, CVT

HOSPITAL NAME

Long Valley AH

REFERRING VET

Dr. Welch

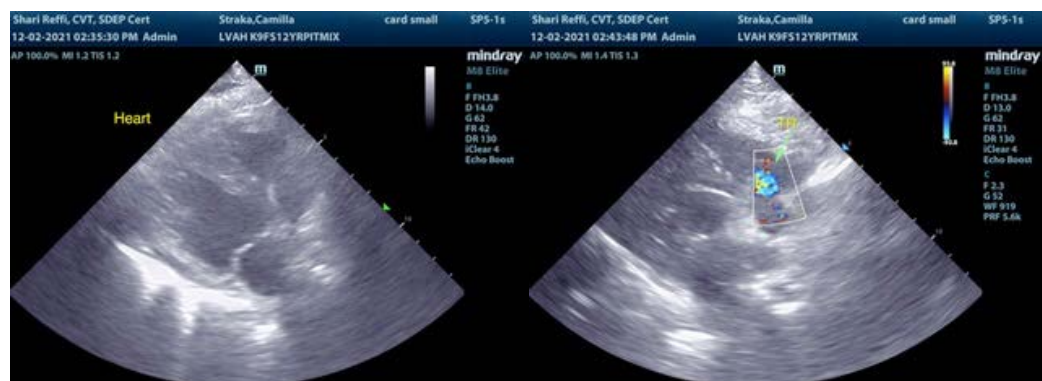
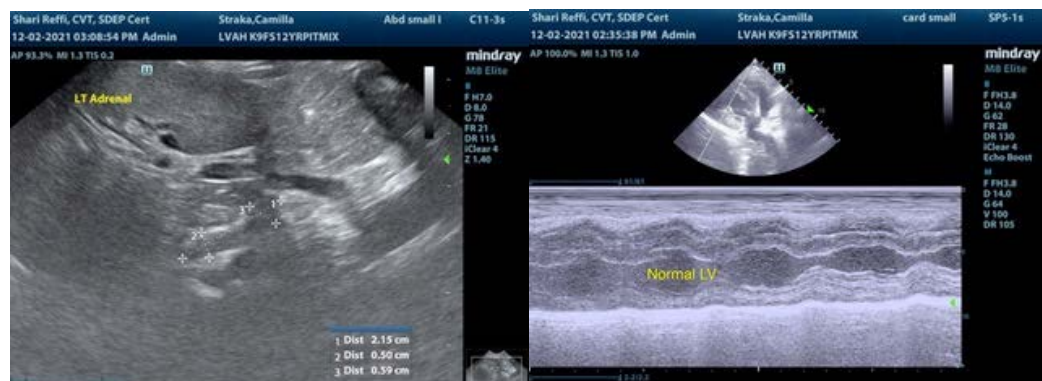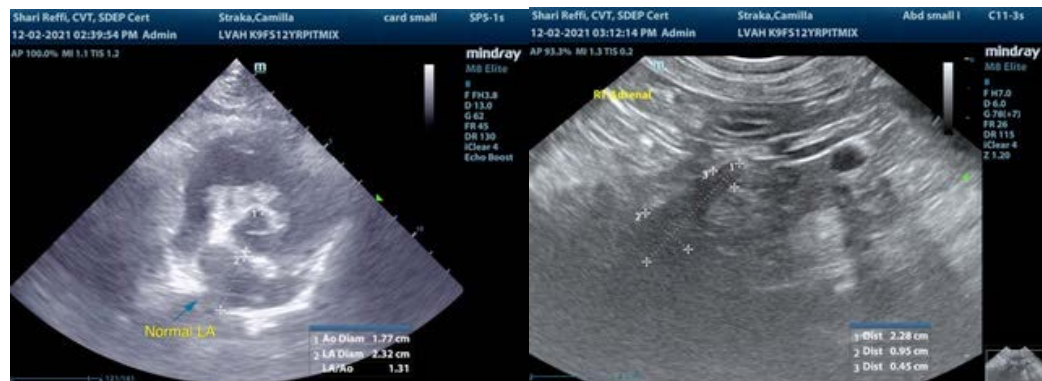
INVOICE

33183

DATE

12/2/21

without additional clinical issues such as systolic dysfunction or evidence of clinical pulmonary hypertension indicate that the risk for future complication is low. No cardiac medications at this stage nor anesthetic contraindications indicated. Suggested anesthetic protocol may include opioid or Benzodiazepine pre-med, induction with Propofol or Alfaxalone, and appropriate gas anesthesia with avoidance of alpha 2 agonists. Conservative monitoring of the murmur would be appropriate with recheck echocardiogram suggested in 6 months, sooner if clinical signs suggestive of heart disease develop, or if the murmur persists/progresses. No evidence of intraabdominal or pericardial metastasis from the mast cell tumor.





PATIENT

Camilla Straka

SPECIES

Canine

BREED

Pit Bull x

SEX

Spayed Female

AGE

12 Years

WEIGHT

54.6 Pounds

INTERPRETED BY

R. McKenzie Daniel,
DVM, DABVP
(Canine and Feline)

IMAGING PERFORMED BY

Shari Reffi, CVT

HOSPITAL NAME

Long Valley AH

REFERRING VET

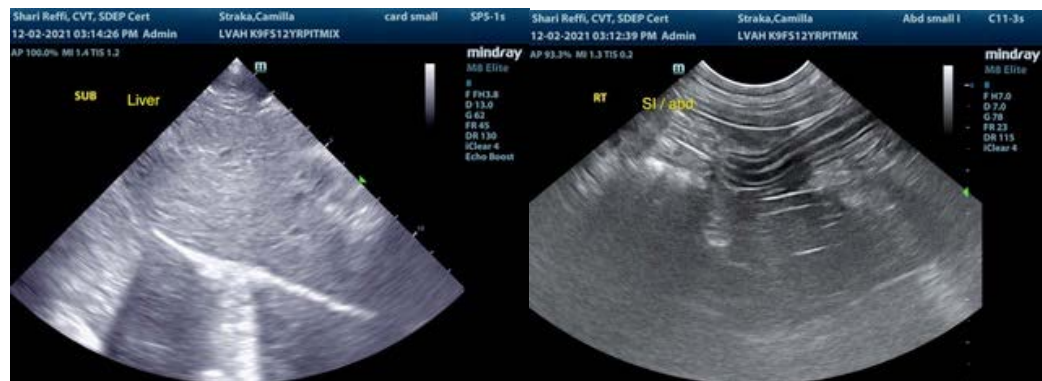
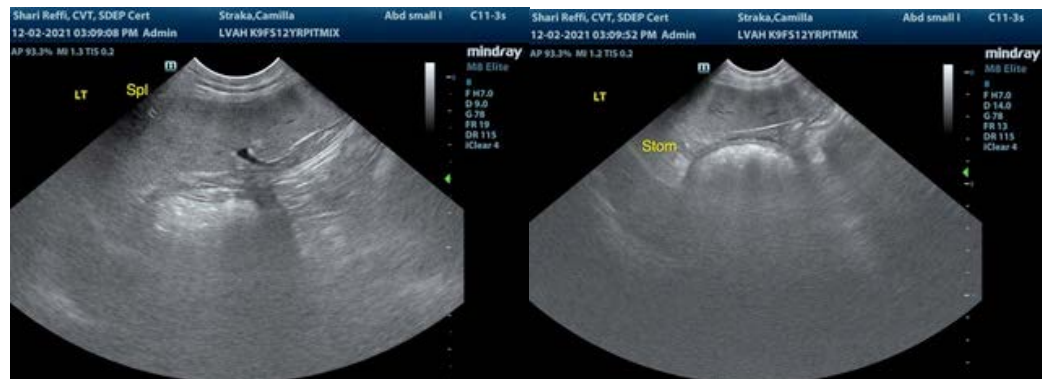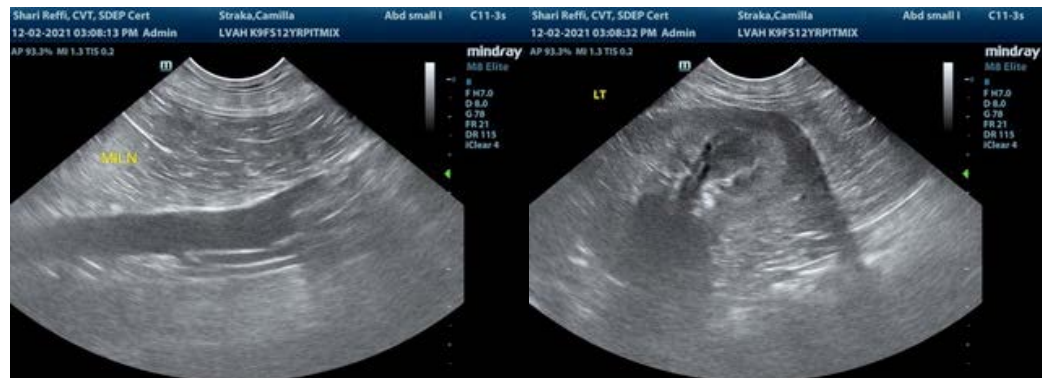
Dr. Welch

INVOICE

33183

DATE

12/2/21



The information and recommendations provided are based on the images presented by the referring veterinarian. No evaluation can be communicated regarding pathology that was not visible in the image/video clips provided.

Thank you for this referral. If the clinical or image interpretation does not parallel your findings or if I can be of any further assistance please contact me.

R. McKenzie Daniel, DVM, DABVP (Canine / Feline Practice)
info@SonoPath.com