

**PATIENT**

Suzy Shoemaker

**PRESENTING CLINICAL SIGNS**

Presented for hotspot on neck and a 2/6 holosystolic heart murmur was noted on exam. Baseline echo to check for heart disease.

**SPECIES**

Feline

**ULTRASONOGRAPHIC EXAMINATION OF THE HEART**

**BREED**

DSH

**SEX**

FI

**AGE**

9mo

**WEIGHT**

7.1lb

FELINE CARDIAC PARAMETERS	BODY WEIGHT (kg)	HR (BPM)	IVSd (cm)	LVIDd (cm)	LVWd (cm)	FS (%)	EF (%)
NORMAL PARAMETER	-----	150-240	0.3-0.6	1.0-2.1	0.25-0.6	35-67	80-100
PATIENT		131	0.4	1.45	0.36	48.3	82
FELINE CARDIAC PARAMETERS	LA/AO (Boon)	LA/AO HEART BASE (Sisson)	LA 2D 4-chamber long axis AS to FW (Sisson) (cm)	LVOT VEL. (m/s)	RVOT VEL. (m/s)	IVRT (m/)	
NORMAL PARAMETER	<1.5	0.88-1.79	0.7-1.7	<1.6	<1.3	40-60	
PATIENT	1.3	1.35	1.2	1.0	1.15		

Adapted from June Boon, Veterinary Echocardiography, 1998  
Sisson D et al. JVIM 1991; 5: 232, Jacobs et al. Am J Vet Res 1985; 46:1705

**Cardiac Presentation**

The echocardiogram in this patient demonstrated normal left atrial size based on 3 separate LA measurements. The cranial and caudal mitral valve leaflets presented normal linear structure and kinetics. The left ventricle presented normal thicknesses with linear contour and was not dilated nor restricted. The myocardium presented normal echogenicity without subjective evidence of significant fibrotic or ischemic disease. The contractility of the ventricular walls was adequate and in normal range for this patient evidenced by the fractional shortening measurement and subjective evaluation of the different regions and angles of the myocardium. The left ventricular outflow tract demonstrated normal laminar flow and subjective structural integrity. The right atrium and auricle revealed normal size, structure and content. No evidence of masses was noted or chamber overload. Tricuspid valvular assessment demonstrated adequate linear morphology and kinetics. The right ventricle was of normal size (1/3 diameter of LV), chordae structure, myocardial echogenicity and thickness. Pulmonic tract assessment revealed normal valve structure, laminar flow, and diameter (approx. 1:1 pa/ao ratio). No visible pericardial or free pleura fluid was noted or extra cardiac pathology in the visible planes. The cranial mediastinum and pericardial regions were free of masses in the visible window.

**INTERPRETED BY**

R. McKenzie Daniel, DVM, DABVP (Canine and Feline)

**IMAGING PERFORMED BY**

Kim Liedberg

**HOSPITAL NAME**

SVS Imaging WI

**REFERRING VET**

Dr. Swanson

**ULTRASONOGRAPHIC FINDINGS**

- Normal echocardiogram

**INVOICE**

12487ag

**DATE**

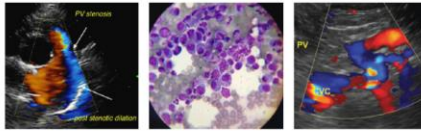
12/19/2022

**INTERPRETATION OF THE FINDINGS & FURTHER RECOMMENDATIONS**

A definitive cause of the patient's murmur was not evident without evidence of structural or functional cardiomyopathy. No evidence of clinical issues such as left or right heart chamber enlargement, LV systolic dysfunction, clinical pulmonary hypertension or overt valvular insufficiencies was present. If no volume changes such as dehydration or anemia are present, a benign physiologic flow murmur or small flow abnormality is suspected. Regardless, the lack of left or right heart chamber enlargement indicate that the hemodynamic effects of the murmur are minimal. No indication for cardiac medications.

IMAGING PERFORMED BY

SVS Mobile Imaging 262 - 366 - 5970  
fredgromalak@gmail.com



Clinical Sonography & Telectology

EDUCATIONAL TELECONSULTATION SERVICES™

1-800-838-4268 info@sonopath.com SonoPath.com

PATIENT

Suzy Shoemaker

Continued conservative monitoring of the murmur is recommended. Recheck echocardiogram recommended in 12 months, sooner if murmur intensity increases or clinical signs suggestive of heart disease arise. No anesthetic contraindications if required.

SPECIES

Feline

BREED

DSH

SEX

FI

AGE

9mo

WEIGHT

7.1lb

INTERPRETED BY

R. McKenzie Daniel,  
DVM, DABVP  
(Canine and Feline)

IMAGING PERFORMED BY

Kim Liedberg

HOSPITAL NAME

SVS Imaging WI

REFERRING VET

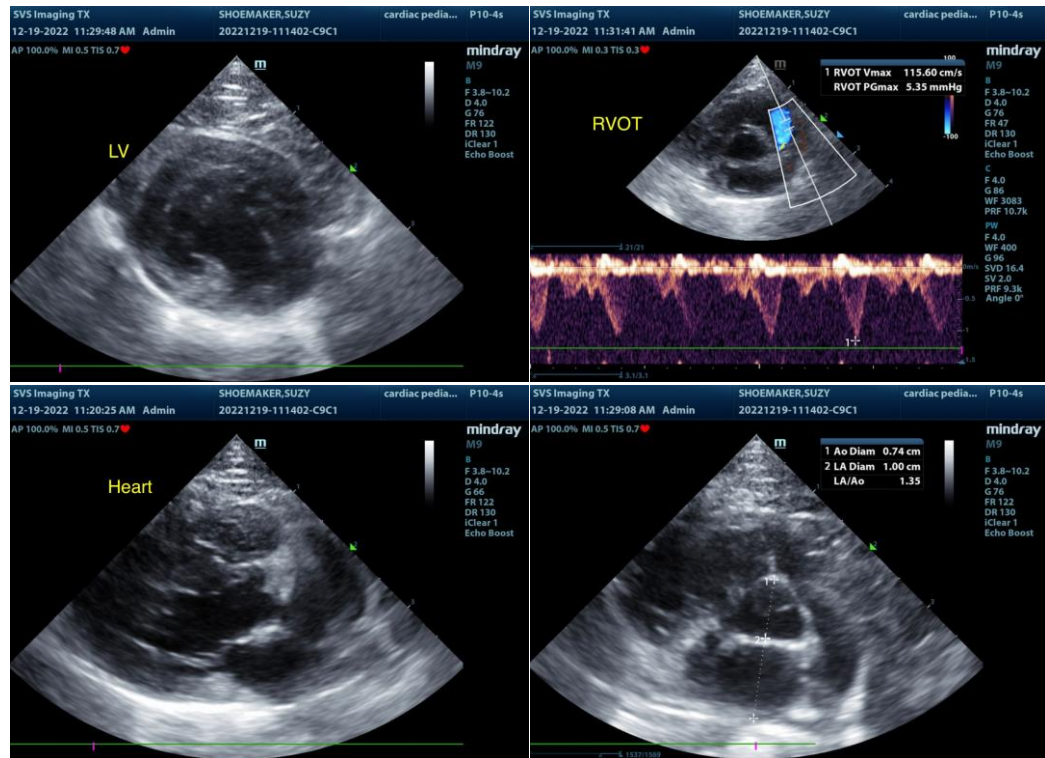
Dr. Swanson

INVOICE

12487ag

DATE

12/19/2022



The information and recommendations provided are based on the images presented by the referring veterinarian/sonographer. No evaluation can be communicated regarding pathology that was not visible in the image/video clips provided.

Thank you for this referral. If the clinical or image interpretation does not parallel your findings or if I can be of any further assistance please contact me.

R. McKenzie Daniel, DVM, DABVP (Canine / Feline Practice)

info@SonoPath.com